

MAY POLYESTER WITH COLLAGEN COATING MESH DECREASE THE RATE OF INTRAPERITONEAL ADHESIONS IN INCISIONAL HERNIA REPAIR?

Pode a tela de poliéster coberta com colágeno diminuir as taxas aderências intraperitoneais na correção de hérnia incisional?

Bárbara LAMBER², João Vicente Machado GROSSI¹, Bibiana Borges MANNA⁴,
Juliano Hermes Maeso MONTES⁴, André Vicente BIGOLIN³, Leandro Totti CAVAZZOLA⁵

From the ¹Department of Surgery, General Surgery HPS, Porto Alegre, RS; ²Department of Surgery and Gin/Obstetric Surgery - UNISC, Santa Cruz do Sul, RS; ³Department of Surgery, General Surgery, Santa Casa Misericórdia, Porto Alegre; ⁴Faculty of Medicine, Lutheran University of Brazil - ULBRA; ⁵Faculty of Medicine, ULBRA and Federal University of Health Sciences, Porto Alegre, RS, Brazil.

ABSTRACT – Background - Among meshes used in incisional hernias in open technique repair, the polypropylene is the most commonly used due to flexibility, cellular growth stimulation, satisfactory inflammatory response, easy manipulation and low price. However, it induces adhesions formation when in contact with the intra-abdominal contents. **Aim** - To evaluate the formation of adhesions after polypropylene and collagen coated polyester mesh with intraperitoneal placement. **Methods** - Twenty six female Wistar rats were randomized in three groups. In the group 0 (sham) there was no prosthesis placement, in the polypropylene (group 1) the prosthesis was placed at the peritoneal surface and in the group 2, collagen coated polyester mesh was placed. The rats were killed on postoperative day 21 to evaluate adhesions regarding its degree, mesh percentage of involvement, bowel involvement and strength needed to cause rupture. **Results** - There was no difference in weight between groups. The group 0 did not develop any adhesions. The groups 1 and 2 developed prosthetic mesh surface adhesions, mostly in the omentum. There was no difference in adhesion degree and percentage of surface involvement between groups. The collagen coated mesh did not develop adhesions. The adhesions occurred at the free edge of the mesh, in contact with the polyester. The Polypropylene group presented 80% of the surface involved with adhesions, while the collagen coated polyester group presented 10% ($p < 0,005$). **Conclusion** - There was no difference between adhesion, degree of adhesion and strength needed to cause rupture. However, the polypropylene mesh presented significantly higher surface of adhesion when compared to the collagen coated polyester mesh.

HEADINGS - Hernia. Collagen. Tissue Adhesions.

Correspondence:

João Vicente Machado Grossi,
e-mail : jvicentegrossi@gmail.com

Financial source: none
Conflicts of interest: none

Received for publication: 15/10/2012
Accepted for publication: 11/12/2012

DESCRITORES - Hérnia. Colágeno. Aderências teciduais

RESUMO – Racional - Entre as telas utilizadas na reparação de hérnias incisionais na técnica aberta, a de polipropileno é a mais utilizada devido à flexibilidade, estimulação do crescimento celular, resposta inflamatória satisfatória, fácil manipulação e baixo preço. No entanto, induz a formação de aderências, quando em contato com os conteúdos intra-abdominais. **Objetivo** - Avaliar as aderências formadas após a colocação intraperitoneal da tela de polipropileno e a tela de poliéster coberta com colágeno. **Método** - Foram utilizadas 26 ratas Wistar fêmeas, randomizadas em três grupos. No grupo 0 (sham) não houve colocação de prótese, apenas laparotomia; no grupo 1 foi implantada a prótese de polipropileno na superfície peritoneal; e no grupo 2, a prótese composta por poliéster coberta por colágeno. Todos os animais foram mortos 21 dias após o procedimento e avaliados quanto às vísceras envolvidas nas aderências, grau das aderências, percentual da tela acometimento por aderências e a força necessária para a sua ruptura. **Resultados** - Não houve diferença de peso entre os grupos. O grupo 0 não apresentou aderência. Os grupos 1 e 2 apresentaram aderências na superfície da prótese, predominante no omento. O grau de aderências, superfície acometida não teve diferença representativa entre os grupos. A cobertura de colágeno não demonstrou aderências. As aderências ocorreram na borda livre da tela, em contato com a face de poliéster. Análise do tipo de superfície comprometida por aderências, o grupo polipropileno teve 80% e o grupo poliéster com colágeno apenas 10% ($p < 0,005$). **Conclusão** - Para os parâmetros avaliados aderência, grau e força máxima de ruptura não houve diferença. No entanto, a tela de polipropileno teve superfície acometida pela aderência significativamente maior em relação à tela de poliéster protegida com colágeno.

INTRODUCTION

More than two million abdominal surgeries are performed annually in the USA. The incisional hernia is the most common complication, found in 11% of the patients submitted to this kind of surgery and 23% of those who develop postoperative wound infection. Hernia repair surgeries represent a 100,000 new procedures every year^{4,5}.

Nearly 50% of incisional hernias develop in the first two postoperative years and 74% three years after surgery^{1,10,15,16}. The ideal mesh must have good tensile strength, be inert, non carcinogen, stable in case of infection and able to develop inflammatory response and avoid tissue rejection²⁰. It is known that an ideal mesh to be used inside the peritoneal cavity in contact with the bowel needs to have a high reactivity side to promote tissue growth at the abdominal wall and another side with the capacity to avoid adhesions⁷.

Among meshes used in incisional hernias in open technique repair, the polypropylene, introduced by Usher in 1963⁸, is the most commonly used due to flexibility, cellular growth stimulation, satisfactory inflammatory response, easy manipulation and low price. However, the polypropylene (PP) mesh induces adhesions formation when in contact with the intra-abdominal contents^{13,17,21}. An experimental study with rats showed that the inflammatory process in the PP mesh may become chronic and delay the proliferative stage of healing. The collagen production is crescent and reaches the maximum level at postoperative day 21, with predominance of collagen type III in the early process and collagen type I after that³. This demonstrates the need to protect the bowel surface of the mesh for longer than that. The Parietex Composite® mesh achieved satisfactory results in extra-peritoneal hernias because of low adhesions formation, appropriate tissue growth, absence of enterocutaneous fistulas and low recurrence rates^{2,6}.

The comparison between bilaminar mesh and other components that include one sheet for temporary tissue separation are only available in a few studies in vivo¹⁹. The recurrence rate after surgical repair reaches 49% of incidence^{4,14}. The postoperative complications are due to adhesions, and includes bowel obstruction and fistulas. Up to 44% of these complications need surgical repair, which shows the need to avoid adhesions¹⁸.

The aim of this study is to evaluate the formation of adhesions after and collagen coated polyester (PC) mesh intraperitoneally placed.

METHODS

The present study was accomplished with the approval of the ethics and research committee from Lutheran University of Brazil – ULBRA and is registered

under protocol number 2009-005A. It was used the ULBRA bioterium according to experimental models protocols from the institution.

Twenty six Wistar female rats (*Rattus norvegicus albinus*) were used. They were kept at room temperature, fed with standard laboratory chow and allowed tap water ad libitum. The meshes were given without any cost to avoid ethics conflicts. For sample size calculation the software Sample Size Determination in Health Studies was chosen¹¹. Was considered force of 80% for p value < 0,05. The rats weight was around 200 g and they were randomized in three groups:

Group 0 (sham group) with six animals: a midline laparotomy was performed, with primary closure of the abdominal wall, without prosthetic implant.

Group 1 or PP with 10 rats: a midline laparotomy was performed and the defect was repaired with a 2x2 cm intraperitoneal PP (Marlex®) mesh.

Group 2 or PC with 10 rats: a midline laparotomy was performed and the defect was repaired with 2x2 cm intraperitoneal collagen coated polyester (Parietex Composite ®) mesh with previously hydration with physiological saline during one minute.

All of the animals were initially kept in groups of 4 or 5 inside the cages. There were 12 hours day and night shifts. The rats were kept at room temperature with appropriate sanitation. All of them received anesthetic induction before the surgical procedure and before death.

Operative technique

The rats received intramuscular injection of 5 mg/kg xilazine (0,1 ml of solution at 2% diluted at 0,2 ml of physiological saline 0,9%) followed by 50 mg/kg intramuscular ketamine (0,35 ml of solution 50 mg/ml). Abdominal trichotomy and antisepsis with alcoholic chlorhexidine 2% were performed.

In the group 0 a 3x4 cm midline incision was made with dissection of the subcutaneous tissue and peritoneal cavity opening through the linea alba. The abdominal wall was closed using 3-0 polypropylene sutures without mesh implantation.

In the group 1 a 3x4 cm midline incision was made with dissection of the subcutaneous tissue and peritoneal cavity was opened through the linea alba. A 2x2 cm PP mesh was implanted using 4-0 polypropylene sutures at the four quadrants. After that, the skin was closed using 3-0 polypropylene sutures.

In the group 2, the same group 1 procedure was performed, except a 2x2 cm collagen coated polyester mesh was implanted after hydration with physiological saline during one minute. 4-0 polypropylene sutures were made at the four quadrants only at the polyester portion without damage of the collagen layer. The abdominal wall closure was made with 3-0 polypropylene sutures (Figure 1).

RESULTS

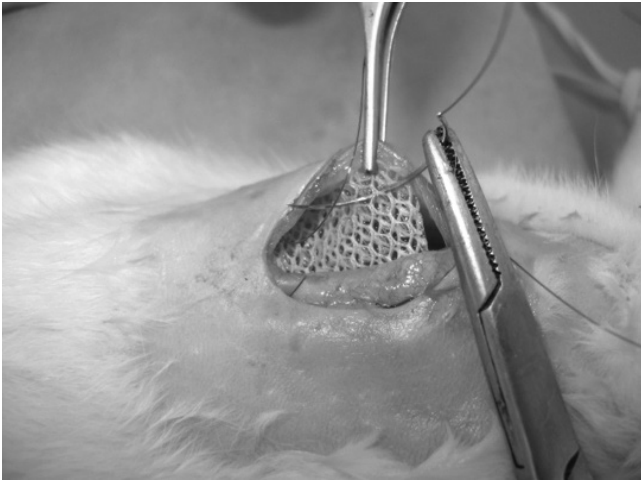


FIGURE 1 – Intraperitoneal placement of Parietex Composite® (collagen coated polyester) mesh

After the procedure, the rats received 0,5 ml of subcutaneous physiological saline 0,9% and recovered in heated place. After recovery they were transferred to their cages with food and water ad libitum. Dipirone (90 mg/ml) diluted in water was offered for three days.

The variables evaluated were: adhesions (Figure 2), regarding presence or absence, adhered structures (liver including round ligament, omentum, intestinal loop), retraction size, percentage of surface involvement (less or more than 50%), and adhesions locations (peripheral or central). The tensile strength was measured using a millimeter ruler with a 5N dynamometer, which was pulled and measured the strength needed to cause rupture. The assessment was performed by a surgeon and a pathologist, both of them blinded to type of mesh. Due to the lack of histologic analysis, the strength needed to cause rupture was measured to estimate the amount of collagen.

Type of Adhesions	Definition
0	NONE - Absence of adhesions.
1	MILD - Thin adhesions with easy release.
2	MODERATE - Adhesions that need blunt dissection to be released.
3	SEVERE - Firm adhesions in which only significant strength is able to release, injuring partially or totally the involved gut

FIGURE 2 – Adhesions degree definition

Statistical analysis

Statistical analysis was done using SPSS v.17 (Statistical package for social science) program. The continuous variables analyzed were standard deviation, average, minimum and maximum values. The categorical variables analyzed were number and percentage. The Wilcoxon test verified if there was any difference between the average weight before and after the surgery with each one of the meshes. The Fisher’s exact test was used to verify the associations between the categorical variables.

There was one death in the sham group during the anesthesia, before the beginning of the surgery. None of the other five animals presented adhesions at the abdominal wall. One rat had the omentum sutured with the abdominal wall but this finding was considered a consequence from the surgical procedure.

The weight of the animals was measured before the surgical procedure and after their death. The analysis was made with Wilcoxon test, which demonstrated significantly difference between initial and final weight for both groups PP and PC, with a significantly weight gain independent from the mesh type ($p=0,005$).

The evaluation of adhesion incidence, according to mesh type, demonstrated 100% of adhesion on the PP mesh, of which 100% involving omentum, 30% the liver, 30% small intestine, 60% liver round ligament (Table 1). The PC mesh also showed 100% of adhesions, of which 100% involving omentum and 10% involving small intestine, but there were no adhesions involving liver and round ligament (Figure 2). There was significant statistical difference for round ligament adhesions only.

TABLE 1 - Meshes comparison regarding adhesions

	Adhesions		Collagen coated polyester		p*
	Sham Group	Polypropylene			
Omentum	0 (0%)	10 (100%)	10 (100%)	-	-
Liver	0 (0%)	3 (30%)	0 (0%)	0,211	
Small intestine	0 (0%)	3 (30%)	1 (10%)	0,582	
Round ligament	0 (0%)	6 (60%)	0 (0%)	0,011	

Data presented as n(%). *P value for Fisher’s exact test

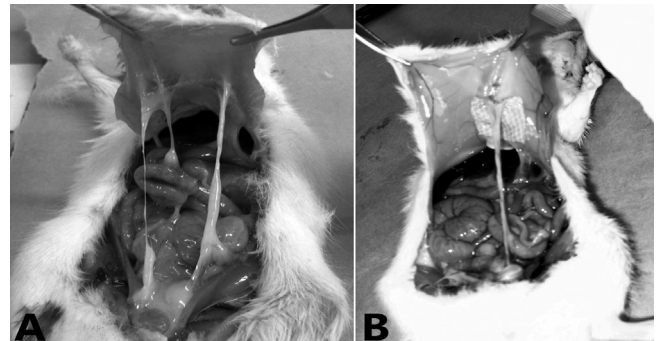


FIGURE 3 – Mesh adhesions: A) Parietex Composite® (collagen coated polyester); B) Marlex® (polypropylene)

The strength needed to cause rupture can be evaluated on Table 2 (Mann–Whitney test). A significant difference was found between the average strength needed to cause rupture on the adhered bowel.

TABLE 2 - Comparison of strength needed to cause rupture between the two types of mesh

Mesh	Adhesion strength	
	Average	Standard deviation
Polypropylene (n=10)	0,96	0,39
Collagen coated polyester (n=10)	0,37	0,18
p-value (*)	<0,001 (**)	

* Mann–Whitney test

There was no significant difference on mesh retraction between PP and PC. Regarding adhesions degree, the PP mesh presented 60% of adhesions level 1 or 2 e 40% of adhesions level 3. The PC mesh presented 90% of adhesions level 1 or 2 and 10% of adhesions level 3. There was a predominance of mild adhesions on the PC mesh (90%) in comparison to the PP mesh (60%) according to Fisher's exact test ($p=0,303$ Table 3).

TABLE 3 - Adhesion degree between meshes

Type of mesh	Degree			
	1 ou 2		3	
Polypropylene	6	60,0	4	40,0
Collagen coated polyester	9	90,0	1	10,0

Data presented as n(%). * p value= $0,303$ for Fisher's exact test

The surface involved with adhesions was classified in two groups. The first with less than 50% of the surface involved with adhesions and the second with more than 50%. There was more than 50% in eight PP meshes and less than 50% in two of them.

Ninety percentage of the PC meshes were involved with adhesions in less 50% of the surface. The Fischer's exact test showed variation between type of mesh and surface involvement ($p=0.005$ Table 4).

TABLE 4 - Adhesions percentage between meshes

Type of mesh	Percentage of mesh involvement			
	Less than 50%		Equal or more than 50%	
Polypropylene (PP)	2	(20%)	4	40,0
Collagen coated polyester (PC)	9	(90%)	1	10,0

Data presented as n(%). * p value= $0,005$ for Fisher's exact test.

In relation to adhesions location, they were found only on the edges of the PC mesh, where the polyester layer was exposed. There were no adhesions in the center of the mesh, where the collagen coating remained intact. In the PP mesh 100% of the adhesions developed in the center. The statistical analysis was not able to be done due to the fact that the adhesions developed in different locations in both meshes.

DISCUSSION

The choice to use exclusively female rats was due to their smaller size, allowing better pliability of the meshes. The number of animals, although the use of sample scale, was also determined by other published studies with similar objectives.

The sham group should be seen as the control group. The study showed the animals gained weight after postoperative day 21.

There was no difference between the types of adhesions. Both meshes developed adhesions in the omentum and small intestine as a consequence. Only the PP mesh developed adhesions in the liver and round ligament of the liver with significant difference ($p=0,011$). The surface of the mesh involved with adhesions was statistically significant when compared

to the two types of mesh ($p=0,005$) with more involvement of the intraperitoneal PP mesh.

The analysis made exclusively for the collagen coated polyester mesh showed adhesions only at the prosthesis edges, which had been previously cut to turn the experiment into a feasible procedure. As a consequence, the component became exposed, which is contraindicated by the manufacturer. There were no adhesions in the center of the mesh, as described before in the literature^{9,12}. The PP mesh developed 100% of the adhesion in the center. This is a limitation of this experimental model that can be solved with upcoming studies.

The collagen layer appears to have a protective effect on the adhesions formations, since the PP and PC meshes showed significantly difference in surface involved with adhesions ($p=0,005$).

CONCLUSION

There was no significant difference between PP and PC mesh when adhesion, degree of adhesion and strength needed to cause rupture were evaluated. However, the PP mesh had significantly higher surface involved with adhesions when compared to PC mesh. Based on these data, is recommend the use of polyester with collagen coating mesh for incisional hernia repair.

REFERENCES

1. Antony T.E, Bergen P.C, Kim L.T, Henderson M, Fahey T, Rege RV, Turnage R.H. Factors affecting recurrence following incisional herniorrhaphy; discussion 101. *World J Surg* 2000; 24:95-100.
2. Benchetrit S, Debaert M, Detruit B, ET AL. Laparoscopic and open abdominal wall reconstruction using Paritex® meshes clinical results in 2700 hernias. *Hernia* 1998; 2: 57-62
3. Casanova A.B, Trindade E.N, Trindade M.R.M. Fibroplasia after polypropylene mesh implantation for abdominal wall hernia repair in rats. *Acta Cir. Bras.* 2009 ; 24 (2): 19-25
4. Cassar K, Munro A. Surgical Treatment of incisional hernia. *Br. J. Surg.* 2002; 89(5): 534 – 45.
5. Dunn R, Lyman M.D, Edelman P.G, Campbell P.K. Evaluation of the SprayGel Adhesion Barrier in the Rat Cecum Adhesion Barrier in the rat Cecum Abrasion and Rabbit Uterine Horn Adhesion Models. *Fertil. Steril.* 2001; 75 (2): 411-6
6. Jacob B.P, Hogler N.J, Durak E, Kim T, Fowler D.L. Tissue ingrowth and bowel adhesion formation in an animal comparative study: Polypropylene versus Proceed versus Parietex Composite. *Surg. Endosc.* 2007; 21: 629-33.
7. Jin J, Voskerician G, Hunter SA, McGee MF, Cavazzola LT, Schomish S, Harth K, Rosen MJ. Human peritoneal membrane controls adhesion formation and host tissue response following intra-abdominal placement in a porcine model. *J. Surg. Res.* 2009; 156(2):297-304.
8. Kiudelis M, Konciauskiene J, Deduchovas O, Radziunas A, Mickevicius A, Janciauskas D, Petrovas S, Endzinas Z, Pundzius J. Effects of different kinds of meshes on postoperative adhesion formation in the New Zealand White rabbit. *Hernia* 2007;11(1): 19-23.
- a. Konarzewski NS, Bigolin AV, Montes JHM, Lambert B, Kist C, Grossi JMV, Cavazzola LT. Evaluation of Intraperitoneal Adhesions Associated with the Double Layer Mesh PTFEe/Polypropylene in the Ventral Hernia Repair – An Experimental Study in Rats. *Bras. J. Video-Sur* 2009, 1(2): 2-10

9. Lamont PM, Ellis H. Incisional hernia in re-opened abdominal incisions: overlooked risk factor. *Br. J. Surg* 1988; 75:373-6.
10. Lun, KC, Chiam, PYW and Aaron, C of the W.H.O. Sample size determination in health studies. Collaborating Centre for Health Informatics and the Medical Informatics Programme of the National University of Singapore. Version 2.0, 1998.
11. Mathews B.D, Mostafa G, Carbonell AM, Joels CS, Kercher KW, Austin C, Norton HJ, Heniford BT. Evaluation on Adhesion Formation and Host Tissue Response to intra-abdominal Polytetrafluoroethylene Mesh and Composite Prosthetic Mesh. *J. Surg. Res.* 2005; 123: 227-34.
12. Nagler A, Rivkind A.I, Raphael J, Levi-schaffer F, Genina O, Lavelin I, Pines M. Halofuginone – an Inhibitor of Collagen Type I Synthesis – Prevents Postoperative Formation of Abdominal Adhesions. *Ann. Surg.* 1998; 227 (4): 575-82.
13. Poelman M.M, Langenhorst B.L.A.M., Schellekens J.F, Schreurs W.H. Modified onlay technique for the repair of the more complicated incisional hernias: single – centre evaluation of a large cohort. *Hernia*
14. Pollock A.V, Evans M. Early prediction of late incisional hernias. *Br. J. Surg.* 1989; 76: 953-4.
15. Rudmik L.R, Schieman C, Dixon E, Debru E. Laparoscopic incisional hernia repair: a review of the literature. *Hernia*, 2006; 10:110-9.
16. Scalco P.P.C, Costa R.G, Lontra M.B, Jotz G.P, Marques F.B, Cavazzola L.T. Comparação entre a tela de submucosa intestinal suína acelular (Surgisis®) e a tela polipropileno (Marlex®) na formação de aderências peritoneais – estudo experimental em ratos. *Revista da AMRIGS.* 2008; 52 (3): 197-203.
17. Scheeffer N.K., Bigolin A., Montes J., Lambert B., Kist Caroline C., Grossi J.V., Cavazzola L.T. Evaluation of intraperitoneal adhesions associated with the double layer mesh PTFEe/Polypropylene in the ventral hernia repair – an experimental study in rats. *Bras. J. Video – Surg.* 2009;2(1): 002 - 010
18. Toosie K, Gallego K, Stabile BE, Schaber B, French S, De Virgilio C. Fibrin glue reduces intra-abdominal adhesions to synthetic mesh in a rat ventral hernia model. *Am Surg*, 2000; 66(1):41-5.
19. Van't Riet M, Van Steenwijk J.D.V, Bonthuis F, Marquet RL, Steyerberg EW, Jeekel J, Bonjer HJ. Prevention of Adhesion to Prosthetic Mesh. *Ann. Surg.* 2003; 237 (1): 123 – 8.
20. Voeller GR.. Innovations in ventral hernia repair. *Surg Technol. Int.* 2007; 16: 117-22.