

Massive Splenomegaly in Pregnancy: Case Report

Janete Vettorazzi^{1,2,3,4}, Edimárlei Gonsales Valério^{1,2,3,4}, André Rajab Reis⁴,
Harold Fabian Ibanez Torres⁵, Anthony Petermann⁴

¹Postgraduation Program in Health Sciences: Gynecology and Obstetrics, Universidade Federal do Rio Grande do Sul (UFRGS), Porto Alegre, Brasil

²Department of Gynecology and Obstetrics, Universidade Federal do Rio Grande do Sul, Porto Alegre, Brasil

³Service of Obstetrics and Gynecology, Hospital de Clínicas de Porto Alegre, Porto Alegre, Brasil

⁴Faculty of Medicine (FAMED), Universidade Federal do Rio Grande do Sul, Porto Alegre, Brasil

⁵Service of Hematology, Hospital de Clínicas de Porto Alegre, Porto Alegre, Brasil

Email: jvettorazzi@hcpa.edu.br

How to cite this paper: Vettorazzi, J., Valério, E.G., Reis, A.R., Torres, H.F.I. and Petermann, A. (2018) Massive Splenomegaly in Pregnancy: Case Report. *Open Journal of Obstetrics and Gynecology*, 8, 163-169.

<https://doi.org/10.4236/ojog.2018.83019>

Received: December 11, 2017

Accepted: March 3, 2018

Published: March 6, 2018

Copyright © 2018 by authors and Scientific Research Publishing Inc.

This work is licensed under the Creative Commons Attribution International License (CC BY 4.0).

<http://creativecommons.org/licenses/by/4.0/>



Open Access

Abstract

A 33-year-old primigravida presented to an appointment at a high-risk prenatal outpatient service due to a history of splenomegaly. Her spleen occupied 2/3 of the abdominal cavity and shifted the uterus to the right side of the abdomen. During investigation, an intrauterine growth restriction (IURG) and a series of other clinical complications were discovered. We admitted her to inpatient care at 28 + 1 weeks' gestation for a better investigation of her extensive splenomegaly and for pregnancy monitoring, with a further successful delivery.

Keywords

Splenomegaly, Spleen, Pregnancy, Cesarean, Intrauterine Growth Restriction, Restricted Fetal Growth

1. Introduction

Splenomegaly can be a clinical sign of many systemic diseases, the most common cases being liver diseases, hematologic malignancies, infections (such as AIDS, endocarditis and parasitosis) and congestion or inflammation (such as in congestive heart failure) [1]. Patients with splenomegaly may be asymptomatic. Nevertheless, these patients sometimes report abdominal pain or even present a series of other clinical manifestations depending on the specific cause of this finding. Once the etiology is known, we can choose a better treatment for such patients.

In the pregnant population, splenomegaly may represent a risk for both the mother and the fetus [2]. There is a vast amount of information on the specific management of the diseases causing splenomegaly and other splenic disorders during pregnancy, but there is little information regarding the obstetric aspects of pregnant women with splenomegaly. In this article, we present a case of a pregnant patient whose splenomegaly had no defined etiology after a large investigation with a multidisciplinary team of doctors and aim to discuss the patient's obstetric approach and the management of a series of other findings.

2. Case

A 33-year-old primigravida from southern Brazil presented to her first obstetric appointment at our high-risk prenatal outpatient service at 21 + 2 weeks' gestation due to a history of splenomegaly. She learned of her increased spleen size when she was 19 years old during the physical examination at a medical appointment for an abdominal pain crisis and further learned that she also had inferior vena cava atresia. With no clear indication for surgery, the patient received pain medications such as Paracetamol and her condition was henceforward followed up by her general physician.

She reported many years of continuous hypochondriac pain and chronic anaemia, denying a history of weight loss, fever, nocturnal sweating or any other symptoms. She also reported a previous extensive investigation for infectious causes of splenomegaly, the results of which were all negative.

Her gynecological exam showed a fundal height of 20 cm and a fetal heart rate of 147 bpm. Her spleen was palpable down to the left iliac fossa, but there were no palpable adenomegalies. Otherwise, her physical exam was unremarkable.

She was Caucasian, a previous tobacco user who stopped smoking before gestation and had no previous surgeries. She denied previous travels to northern Brazil, where Malaria, Leishmaniasis and other parasitoses are endemic.

One day before hospitalization, the patient underwent an abdominal ultrasound (**Figure 1**), which presented the findings of chronic thrombosis of the left branch of the portal vein and of the splenic vein with collateral circulation, signs suggestive of chronic liver disease, a spleen measuring 33 cm in diameter at its largest point and normal blood flow in the inferior vena cava. The patient was then admitted to inpatient care at 28 + 1 weeks' gestation for a better investigation of her extensive splenomegaly and chronic thrombosis in both portal and splenic veins and for pregnancy monitoring. On admission, the patient had a body mass index (BMI) of 20.6 kg/m² and presented with massive splenomegaly at the physical examination, with the spleen occupying roughly 2/3 of the abdominal cavity, as seen on **Figure 2**, and pelvis and shifting the uterus to the right side of the abdomen. Laboratory values on her first day at the hospital were hemoglobin 9.5 mg/dL (normal range: 11.5 - 16.0 mg/dL), total leukocytes 6120/mm³ (normal range: 4000 - 10,000 mm³), platelet count 132,000/mm³ (normal range: 150,000 - 400,000 mm³), AST 18U/L (normal range: 0 - 32 U/L) and ALT 17 U/L (normal range: 0 - 33 U/L). The results of an investigation for

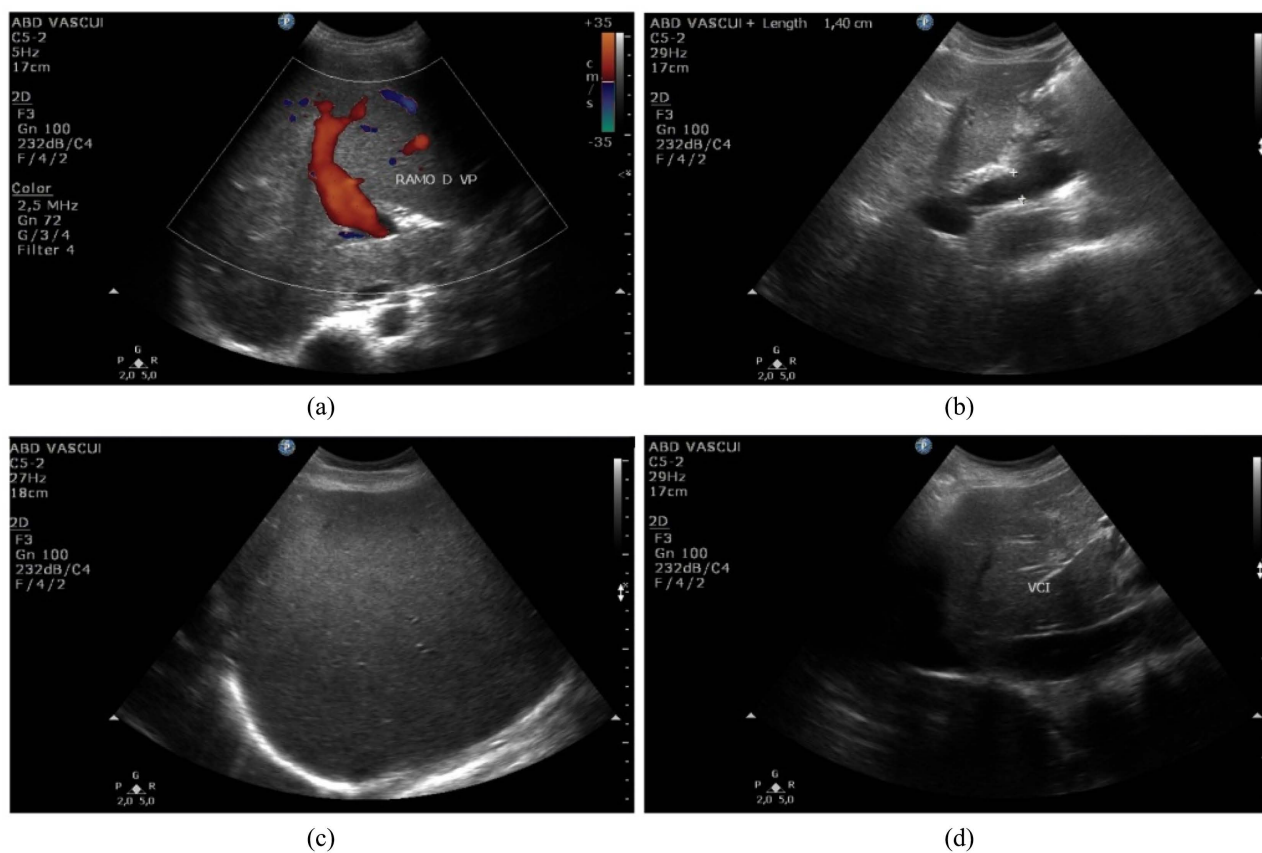


Figure 1. Abdominal Ultrasound: (a) Only the right branch of the portal vein can be seen in the image, suggesting chronic thrombosis of the left branch; (b) Dilatation of the portal vein (1, 4 cm of diameter); (c) The enlarged spleen measures 33 cm on its largest longitudinal axis; (d) Inferior vena cava—no significant alterations.

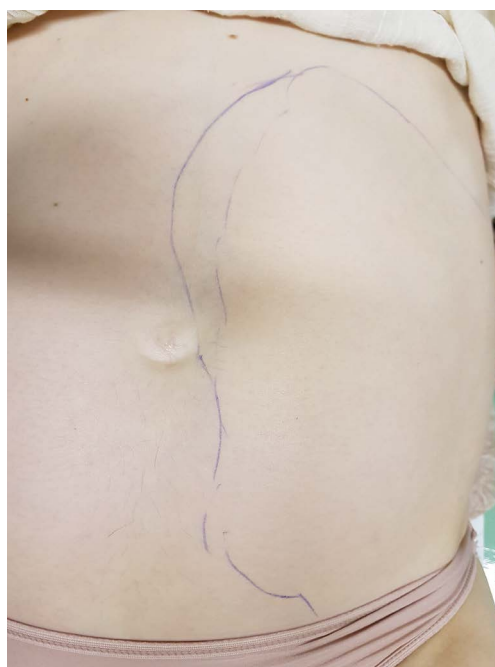

Figure 2. A drawing on the patient's abdomen corresponding to the approximate size of her spleen.

causes of thrombophilias (factor V Leiden, C protein, prothrombin mutation and anticardiolipin IgM and IgG) were negative. Test results for ANA, anti-DNA, lupic anticoagulant, rheumatoid factor, C 3 and C 4, antithrombin activity and paroxysmal nocturnal hemoglobinuria were also negative. The patient tested negative for infectious hepatitis and HIV. The JAK 2 mutation was present, but the patient had no clinical manifestation of myeloproliferative diseases other than splenomegaly. She underwent bone marrow biopsy, which presented only reactional abnormalities and megakaryocyte hyperplasia, and her medulogram presented hyperplasia of all blood cell lineages. Her echocardiography had no significantly altered findings and the abdominal presentations at successive abdominal ultrasounds remained unchanged during the entire hospitalization period.

During her inpatient care period, she was evaluated intensely by doctors of many specialities. The hematology team conducted an extensive investigation concerning the origin of the patient's chronic thrombosis and splenomegaly, which produced no clear answer after 2 months of multiple examinations. Surgeons also evaluated the patient and saw no indication for splenectomy, as the patient was clinically stable. The gastroenterology service did not indicate a new upper gastrointestinal endoscopy, because the patient had already undergone the same procedure, which showed the presence of small esophageal varices justifying that a new exam would only aggravate the risk at that moment and indicated the prescription of propranolol for primary bleeding prophylaxis. The multidisciplinary team formed by hematologists, general surgeons, vascular surgeons, gastroenterologists and obstetricians opted to maintain heparin in prophylactic doses and not administer full-dose therapy during the hospitalization period, given the patient's risk of upper digestive bleeding due to her esophageal varices.

She was evaluated during her entire inpatient period with periodic fetal assessment and weekly Doppler ultrasonography due to intrauterine growth restriction, with Doppler demonstrating distention of the middle cerebral artery and normal umbilical arteries. We opted to electively interrupt gestation at 36 weeks by cesarean section, given the risks of bleeding during an exposure manoeuvre of a vaginal delivery, because the spleen occupied a wide portion of her pelvis and had dislocated the uterine body and due to restricted fetal growth (percentile 5); before surgery, the patient had a hemoglobin level of 10.5 mg/dL and a platelet count of 178,000/m³ so a reservation of blood supply was requested. A xifopubic median abdominal incision and broad fundic/body uterine incision were then performed and a female baby was born weighing 2255 g with an Apgar score of 8/9; no complications occurred during the surgery and blood supply was not necessary. The possibility of performing a concomitant splenectomy during the cesarean section, which could increase the risk of maternal morbidity but might be necessary, was discussed with the surgical team. The findings of the surgery are described on **Figure 3** and **Figure 4**. The general surgeons were therefore present in the operating room during the cesarean section, but the splenectomy was not necessary as the patient had no significant

bleeding during the surgical procedure. The patient evolved to a physiologic puerperium and the baby was discharged from the hospital with the mother 4 days after delivery.

The patient returned 5 days after being discharged from the hospital for an appointment with the obstetrics team and received an anticoagulant prescription with directions of continuing an outpatient investigation of the etiology of her splenomegaly with the hematology team, as there was no final diagnosis for this

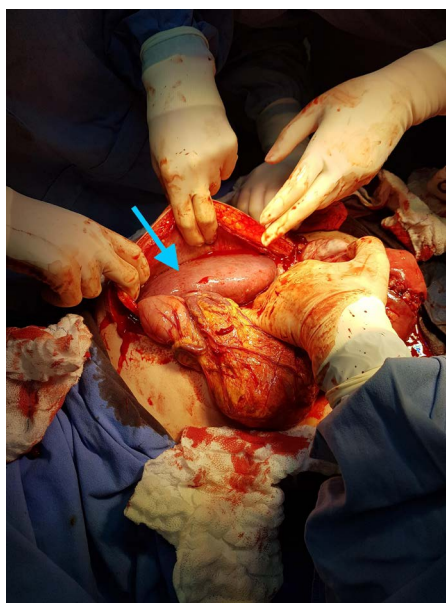


Figure 3. The patient's spleen shown clearly (blue arrow).

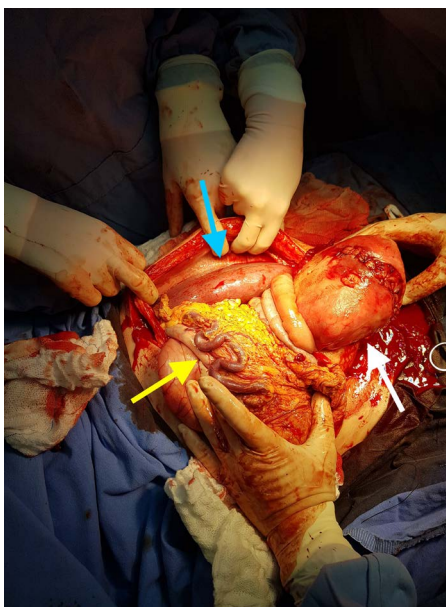


Figure 4. During surgery, the enlarged spleen (blue arrow) occupied most of the left portion of the patient's abdomen, prominent mesenteric vascularization (yellow Arrow) was noticed and a suture of the uterine fund (white arrow) was performed where the fetus was removed.

presentation. Around 40 days after delivery, the patient had a copper intrauterine device (IUD) implanted. The hematology team continued to investigate the uncertain etiology of her splenomegaly. The patient signed an informed consent authorizing the publication of this case.

3. Discussion

There are many known causes of splenomegaly during pregnancy, which do not differ much from those in the general population. However, the management of a patient with a voluminous splenomegaly of unknown etiology can be challenging, especially when it involves a pregnant woman, as it may bring a series of risks and complications for both the mother and the fetus. Most articles discuss the best therapy for certain diseases that cause splenomegaly specifically during the pregnancy period, but there is little information regarding the obstetric approach to cases where extensive splenomegaly may be a potential obstetric issue.

In the general population, an enlarged spleen may increase the risk of infections, bleeding secondary to splenic sequestration of platelets and traumatic or spontaneous splenic rupture, complications that can also affect pregnant women with splenomegaly. In addition, some authors believe pregnancy itself may be a risk factor for splenic rupture, an event that can be fatal for both the mother and the child if misdiagnosed [2]. Despite being extremely rare, there are reported cases of spontaneous splenic rupture during pregnancy with no underlying pathology or trauma history that could explain this event, but trauma continues to be the major cause of splenic rupture [3].

Another remarkable finding in this case was the fetus's restricted intrauterine growth. Since the patient's prenatal infection screening results were negative, no signs of other systemic or obstetric diseases were present and the anatomopathological exam of the placenta was normal, we can point to two possible causes of this disturbance in this patient among the most common etiologies of IURG: First is the mother's chronic morbidity, given that she had a long history of anaemia and splenomegaly of unknown etiology; Secondly, the mother's spleen occupied a large space in her abdomen and pelvis, and this might have played a role in the development of the fetus's IURG, although there is no clear evidence of the correlation between these two events.

Despite the potential complications during delivery due to splenomegaly, the best mode of delivery in patients with this finding is not yet established. In a recent prospective cohort study from the United Kingdom that evaluated pregnancy outcomes in patients with myeloproliferative neoplasms who have splenomegaly as a relatively frequent finding [4], the rate of cesarean delivery was 45% [5]. The study does not point to splenomegaly itself as a deciding factor in the mode of delivery; therefore, it is not known whether this finding might have played a role in choosing the route of birth. In our patient's case, the considerable volume of the spleen supported the decision to deliver by cesarean section, because the uterus was dislocated by the spleen to the right side of the abdomen,

and the spleen itself occupied a portion of the pelvis. Hence, we believe physicians should evaluate each case individually to determine which mode of delivery is best for their pregnant patients with splenomegaly.

This case also highlights the importance of a multidisciplinary team to discuss the best approach to patients with a clinical finding with no defined etiology and a series of clinical complications. In our patient's case, a group formed by doctors from different specialities had to weigh the risks and benefits of full anticoagulation, as the patient had simultaneous thrombotic findings and esophageal varices. Heparin was eventually prescribed in prophylactic doses because the team believed that the risks of bleeding complications surpassed the benefits of full anticoagulation in this pregnant patient. The patient participated actively in all the clinical decisions and was continuously informed about her clinical status.

We must ultimately remember the importance of discussing contraception methods with all patients before and after their delivery, offering them complete gynecological care.

4. Conclusion

Splenomegaly, regardless of its etiology, may be an issue during pregnancy, representing risks for both the mother and the child. We lack evidence regarding the best obstetric approach for pregnant patients with splenomegaly. In order to offer the best medical care for these patients, they should be evaluated by a multidisciplinary team.

References

- [1] Schrier, S.L., Tirnauer, J.S. and Mentzer, W.C. (2017) Approach to the Adult Patient with Splenomegaly and Other Splenic Disorders. UpToDate, Waltham, MA.
- [2] Bljajić, D., *et al.* (2004) Splenic Rupture in Pregnancy—Traumatic or Spontaneous Event? *European Journal of Obstetrics & Gynecology and Reproductive Biology*, **115**, 113-114. <https://doi.org/10.1016/j.ejogrb.2003.10.028>
- [3] Wang, C.H., *et al.* (2011) Spontaneous Rupture of the Spleen: A Rare but Serious Case of Acute Abdominal Pain in Pregnancy. *The Journal of Emergency Medicine*, **41**, 503-506. <https://doi.org/10.1016/j.jemermed.2010.05.075>
- [4] Van Etten, R.A. (2017) Clinical Manifestations and Diagnosis of Chronic Myeloid Leukemia. UpToDate, Waltham, MA. <https://www.uptodate.com/contents/clinical-manifestations-and-diagnosis-of-chronic-myeloid-leukemia>
- [5] Alimam, S., *et al.* (2016) Pregnancy Outcomes in Myeloproliferative Neoplasms: UK Prospective Cohort Study. *British Journal of Hematology*, **175**, 31-36. <https://doi.org/10.1111/bjh.14289>