

Classic homocystinuria and keratoconus: a case report

Homocistinúria clássica e ceratocone: um relato de caso

Patrícia Ioschpe Gus¹, Natália Paseto Pilati², Bruna Ossana Schoenardie², Diane Ruschel Marinho³

1. Hospital de Clínicas de Porto Alegre, Porto Alegre, RS, Brazil.

2. Universidade Federal do Rio Grande do Sul, Porto Alegre, RS, Brazil.

3. Ophthalmology and Otolaryngology Department, Universidade Federal do Rio Grande do Sul, Porto Alegre, RS, Brazil.

ABSTRACT | Homocystinuria is one of a group of genetic disorders called inborn errors of metabolism. It is characterized by a deficiency of the enzyme that converts homocysteine to cystathionine. Keratoconus is an ophthalmologic condition characterized by thinning of the corneal stroma, which causes the cornea to assume a conical shape. There is little information in the scientific literature about the association between keratoconus and homocystinuria. We believe that a collagen cross-linking defect may be the key to understand the connection between these two conditions. This case report describes a 38-year-old male patient with a diagnosis of classical homocystinuria since age 13. At the age of 16, he received a diagnosis of asymmetrical keratoconus when referred for lensectomy with vitrectomy of his left eye. To the best of our knowledge, this is the first report of a patient with simultaneous homocystinuria and keratoconus.

Keywords: Keratoconus; Homocystinuria/genetics; Collagen; Corneal stroma

RESUMO | Homocistinúria é parte de um grupo de doenças genéticas chamado erros inatos do metabolismo. É caracterizada por uma deficiência da enzima que converte a homocisteína em cistationina. O ceratocone é uma patologia oftalmológica caracterizada pelo afinamento do estroma corneano, o que faz com que a córnea assumam um formato cônico. Há pouca informação na literatura científica sobre a associação entre ceratocone e homocistinúria. Acreditamos que um defeito no cross-linking do colágeno possa ser a chave para entender a conexão entre estas duas condições. Este relato de caso descreve um paciente masculino de 38 anos com diagnóstico de homocistinúria clássica desde os 13 anos. Aos 16 anos, recebeu o diagnóstico de ceratocone assimétrico quando foi encaminhado para len-

sectomia com vitrectomia do olho esquerdo. Até onde sabemos, este é o primeiro relato de um paciente com homocistinúria e ceratocone simultâneos.

Descritores: Ceratocone; Homocistinúria/genética; Colágeno; Substância própria

INTRODUCTION

Homocystinuria is one of a group of genetic disorders called inborn errors of metabolism. It is characterized by a deficiency of the enzyme cystathionine- β -synthase, which converts homocysteine to cystathionine. This condition results in an accumulation of homocysteine and methionine, among other metabolites, in the cells and plasma. Homocystinuria is a hereditary disorder with an autosomal recessive inheritance pattern that causes alterations in many parts of the body. The symptoms usually start in the first year of life. The worldwide clinical prevalence of this disease is 1/300,000⁽¹⁾. The main nonophthalmologic alterations in the most common form of homocystinuria are osteoporosis, malar flush, cognitive impairment, and thromboembolic phenomena. In ophthalmology, the main findings are lens subluxation, progressive myopia, and loss of best-corrected visual acuity. Homocystinuria is also associated with microcystic peripheral retinal degeneration, secondary pupillary block glaucoma, retinal detachment, microphthalmos, optic atrophy, retinal arterial occlusions, and band keratopathy⁽²⁾.

Keratoconus is an ophthalmologic condition characterized by thinning of the corneal stroma, which causes the cornea to assume a conical shape. Abnormal posterior ectasia, abnormal corneal thickness distribution, and clinical noninflammatory corneal thinning are mandatory findings in the diagnosis of keratoconus⁽³⁾. The prevalence of keratoconus is approximately 1/2000 among the general population. It usually manifests during the

Submitted for publication: December 19, 2017

Accepted for publication: March 14, 2018

Funding: No specific financial support was available for this study.

Disclosure of potential conflicts of interest: None of the authors have any potential conflicts of interest to disclose.

Corresponding author: Patrícia Ioschpe Gus.

Av. Carlos Gomes, 403/608 - Porto Alegre, RS - 90480-003 - Brazil
E-mail: patriciaagus@me.com

 This content is licensed under a Creative Commons Attribution 4.0 International License.

second decade of life and progresses for approximately 10 years until stabilization. Keratoconus is bilateral and usually asymmetrical and causes irregular astigmatism and myopia. In advanced cases or in those in which the vision cannot be improved with contact lenses, corneal transplantation may be needed.

The case report below describes a patient who was diagnosed with simultaneous homocystinuria and keratoconus. To the best of our knowledge, this is the first such reported case. We believe that these two disorders may be correlated due to alterations in collagen metabolism.

CASE REPORT

The patient is a 38-year-old man who received a diagnosis of classical homocystinuria (cystathionine-β-synthase deficiency) at age 13. He was responsive to vitamin B₁₂, which he has been taking ever since diagnosis.

At the age of 16, he was referred for lensectomy with vitrectomy of the left eye (OS) due to bilateral subluxated crystalline lenses. The same procedure was performed in the right eye (OD) at the age of 26. No intraocular lens implantation was performed. At this time, he also received a diagnosis of asymmetrical keratoconus. His

visual acuity with glasses was 20/50 with +8.50 sph -2.00 cyl 180 OD and 20/100 with -3.00 sph -3.50 cyl 135 OS. At the last visit, the patient was wearing a soft contact lens in OD (20/50) and a scleral lens in OS (20/40). Corneal topography showed the typical pattern of bilateral keratoconus, which was much more advanced in OS (Figures 1 and 2). The thinnest pachymetric measurements were 544 and 232 μm in OD and OS, respectively. The retinal examination was normal.

DISCUSSION

The pathophysiology of keratoconus is believed to be a defect in collagen, which allows for enzymatic degradation and fibrillary slippage, resulting in weakening of the cornea. The association of keratoconus with connective tissue disorders is based partly on reports of association between collagen metabolism disorders and keratoconus. A study of 44 patients with keratoconus showed that 22 of them had hypermobility of the joints⁽⁴⁾. Keratoconus has also been described in patients with imperfect osteogenesis, Ehlers-Danlos syndrome, mitral valve prolapse, and other conditions linked to alterations in collagen metabolism. In keratoconic corneas, there are some changes in the proteoglycans, such as a

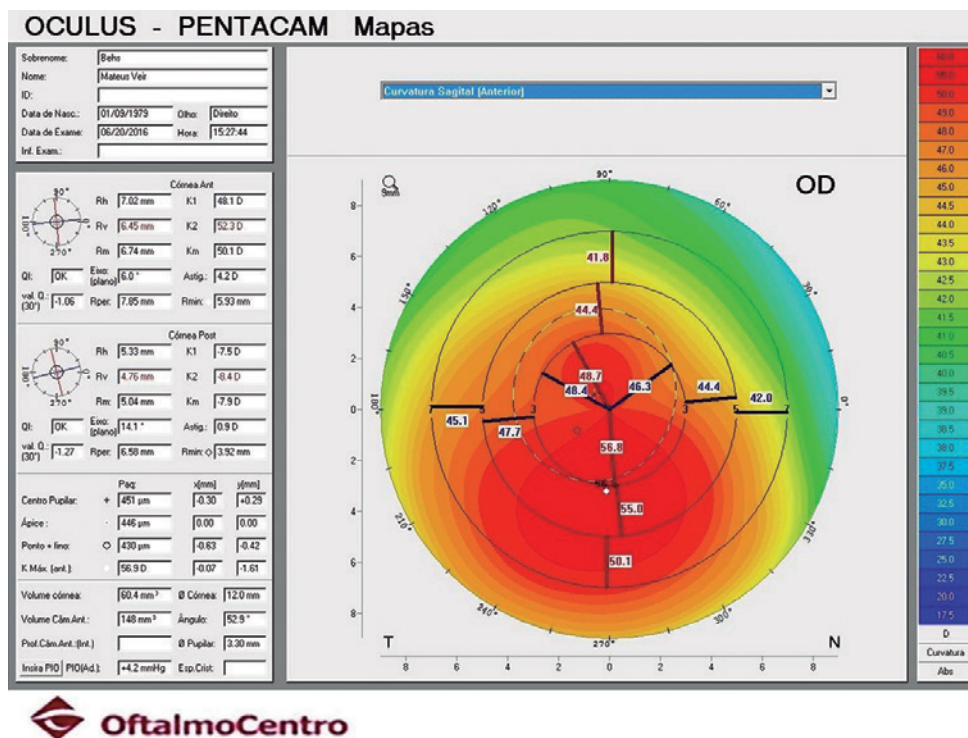


Figure 1. Right eye topography.

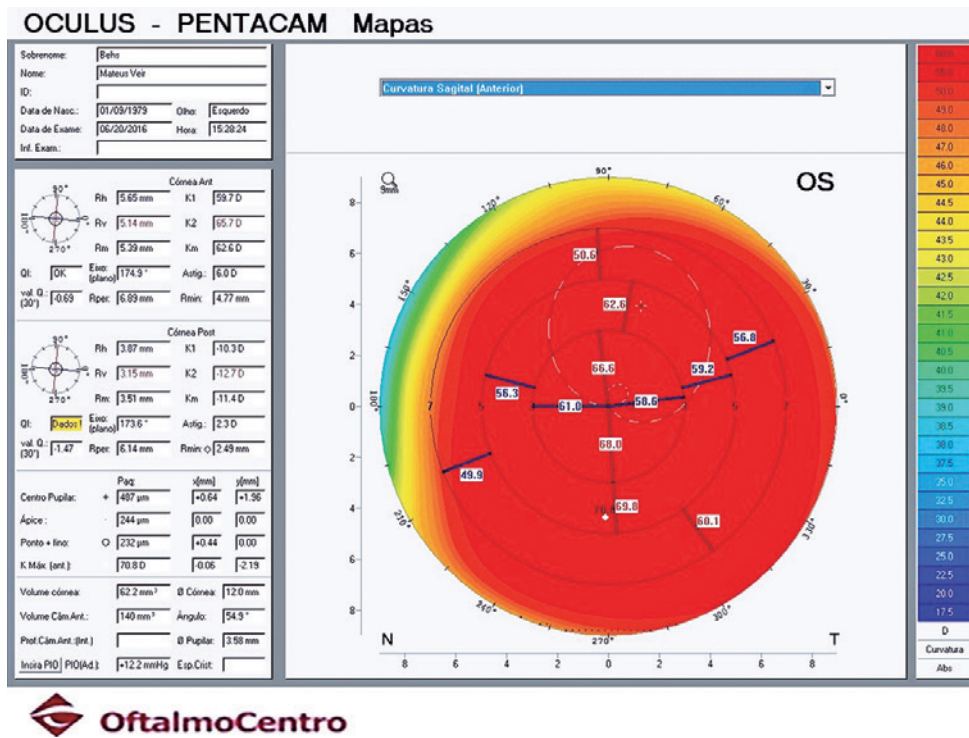


Figure 2. Left eye topography.

decrease in sulfate chains and an increase in dermatan chains. These changes lead to a decrease in the strength of the cohesive forces between collagen sheets, which may explain the physiopathology of the disease.

The enzymatic defect responsible for the altered amino acid metabolism in homocystinuria leads to connective tissue malformation. In 1973, a study showed a decrease in cross-linking of the collagen in three patients with homocystinuria compared with that in age-matched controls. However, the mechanism of action is still poorly understood⁽⁵⁾.

There is no information in the scientific literature about the association between keratoconus and homocystinuria. We believe that a collagen cross-linking defect may be the key to understand the connection between these two conditions. However, the mechanism

of this defect is not well understood. We acknowledge the possibility that the association between the two conditions in our patient may have been random, and therefore, additional studies are required.

REFERENCES

1. Cecil R, Goldman L, Schafer A. Goldman's Cecil medicine. Philadelphia: Elsevier, Saunders; 2012.
2. Harrison D, Mullaney P, Mesfer S, Awad A, Dhindsa H. Management of ophthalmic complications of homocystinuria. Ophthalmology. 1998;105(10):1886-90.
3. Gomes J, Tan D, Rapuano C, Belin M, Ambrósio R, Guell J, et al. Global Consensus on keratoconus and ectatic diseases. Cornea. 2015; 34(4):359-69.
4. Baum J. Keratoconus and the Ehlers-Danlos syndrome: A new aspect of keratoconus. Surv Ophthalmol. 1976;21(1):73-4.
5. Kang A, Trelstad R. A Collagen Defect in Homocystinuria. J Clin Invest. 1973;52(10):2571-8.