

Outbreaks of Mycoplasmosis and Histomoniasis in a Southern Brazilian Flock of Ornamental Birds

Luiz Gustavo Schneider de Oliveira¹, Fabiana Marques Boabaid¹, Marina Paula Lorenzetti¹, Veronica Rolim¹, Helton Fernandes dos Santos², David Driemeier¹ & Cláudio Estêvão Farias Cruz³

ABSTRACT

Background: Infectious diseases have expanded their host and geographic ranges, increasing impacts on both human and animal health. *Mycoplasma gallisepticum* usually causes avian chronic respiratory conditions and *Histomonas meleagridis* infects the cecum and the liver of poultry. Although these diseases have been reported in several bird species, information associated with their prevalence and impact in local flocks of ornamental birds is scarce. This communication describes severe outbreaks of mycoplasmosis and histomoniasis that affected a southern Brazilian commercial flock of ornamental birds.

Case: The outbreaks occurred in an ornamental bird flock that contained 2,340 birds from 39 different species, distributed mostly in the orders Galliformes, Anseriformes, and Psittaciformes. *Mycoplasma gallisepticum* affected 12 chukar partridges, 12 Indian peacocks, 19 ornamental chickens and 46 individuals of 4 species of pheasant. The disease cases were distributed between April and July 2015. A total of 36 birds died due to the disease' complications and most surviving birds suffered from severe ocular sequels, which determined their subsequent culling, despite attempts of different treatment protocols. The main signs included coughing, sneezing, infraorbital swelling, wasting, and death which were mostly associated with caseous sinusitis. Affected birds had positive samples when stained with anti-*Mycoplasma gallisepticum* immunohistochemistry and tested by *Mycoplasma gallisepticum*-Polymerase Chain Reaction. The application of 2 doses of a *Mycoplasma gallisepticum* vaccine in early 2016 to all the Galliformes in the flock reduced the annual prevalence to 4 clinical cases. Histomoniasis affected and killed 19 out of 27 chukar partridges that were being kept with ring-necked pheasants in the same enclosure. The disease occurred between September and December 2016 and a high prevalence of *Heterakis gallinarum* was detected in the flock. The main findings included apathy and death linked to hepatic and cecal necrosis. Admixed in the necrotic areas, there were numerous round to oval, eosinophilic, protozoal trophozoites of 15-20 µm in diameter, occasionally containing a 3-5 µm centrally located basophilic nucleus (histomonads) surrounded by a clear halo. Anthelmintic dosing, exchanging and liming the bedding material of the enclosures, and keeping the remaining partridges in an aerial aviary with a wire mesh floor prevented additional cases of histomoniasis.

Discussion: In Brazil, as in other countries, the sanitary management practices applied in commercial chicken production reached high levels of technification. However, this is not the case in ornamental bird breeding systems, which may still suffer the impacts of diseases that are practically extinct in industrial chicken flocks. For both diseases, diagnosis was based on typical clinical signs and detection of the pathogens in association with characteristic pathological findings. The occurrence of mycoplasmosis and histomoniasis was associated with improper management practices at the farm; the main risk factors observed were a high turnover of birds, the absence of quarantine, the absence of basic health care, overcrowding and poor hygiene. The prevention of further cases of both diseases was mostly established with the application of basic sanitary measures, including vaccination and anthelmintic dosing, for mycoplasmosis and histomoniasis respectively. This report alerts bird keepers and avian veterinarians of the importance of establishing proper sanitary management in local ornamental bird flocks. Because some of the ornamental bird species that have been commercially propagated worldwide may be included in the list of threatened species, the findings described here also show that simple health care may promote the fight against extinctions.

Keywords: avian diseases, ornamental birds, sanitary management, chukar partridge, pheasants, control.

INTRODUCTION

The bacterium *Mycoplasma gallisepticum* causes chronic respiratory disease of poultry, especially in the presence of stress and/or other pathogens. Typical outbreaks are associated with coryza, sneezing, conjunctivitis and sinusitis, particularly in turkeys and game birds, which are often commercialized as ornamental bird species in Brazil. Mycoplasmas may be transmitted through infectious aerosols and contaminated feed and water [2,6].

Histomoniasis is caused by the protozoan parasite *Histomonas meleagridis* that infects the cecum and the liver of poultry. The disease affects turkeys to a greater extent than chickens or game birds. The parasite is most often transmitted in embryonated eggs of the nematode *Heterakis gallinarum*, which may be harbored by many birds. *H. gallinarum* larvae that are infected with *H. meleagridis* may also be carried by earthworms. Clinical signs of histomoniasis may include reduced appetite, drooping wings, ruffled feathers, diarrhea and sudden death. While vaccination and successful drug therapy have been reported to control mycoplasmosis, appropriate management practices are the most effective control measures [2,6]. Proper management has also been reported as a gold standard preventive practice for histomoniasis, especially general hygiene and housing species separately [4,8].

Although both conditions have been described in several exotic and wild species, there is little information available about the impact of the diseases on Brazilian flocks of ornamental birds. This communication describes severe outbreaks of mycoplasmosis and histomoniasis that affected a commercial flock of ornamental birds in southern Brazil.

CASE

The disease outbreaks occurred in an ornamental bird flock that has been established commercially for up to 15 years and is located in the Glorinha municipality, Rio Grande do Sul, Brazil. The total flock included 2,340 birds, distributed mostly in the orders Galliformes, Anseriformes and Psittaciformes. The mycoplasmosis cases were observed in birds of both sexes and of 1-4 years old, between April and July 2015. Affected birds included 46 pheasants (18 golden *Chrysolophus pictus*, 15 silver *Lophura nycthemera*, 8 green *Phasianus versicolor* and 5 ring-necked *Phasianus colchicus*), 12 Indian peafowl (*Pavo cristatus*), 12 chukar partridge

(*Alectoris chukar*) and 19 ornamental chickens, mostly of the Appenzeller and Sebright breeds. The clinical signs included coughing, sneezing, respiratory rales, lacrimation, increased infraorbital volume (Figure 1), wasting and death. Eight dead birds were submitted for necropsy and tissue fragments were collected, processed by standard histological methods, and stained with hematoxylin-eosin. Selected sections were submitted to anti-*Mycoplasma gallisepticum* immunohistochemical (IHC) staining. In addition, samples of tracheal secretion from 7 birds were submitted for *Mycoplasma gallisepticum*-Polymerase Chain Reaction (PCR).

The necropsies revealed that the increased infraorbital volume was filled with a translucent, mucous to caseous material (Figure 1D). An infiltrate of macrophages and cellular debris occupied the paranasal sinuses. The PCR confirmed the presence of *Mycoplasma gallisepticum* in 4 of the 7 samples tested. The IHC staining showed positive staining in the air sacs in 4 cases. During the outbreak period, the farmer implemented some treatment protocols (for example, tylosin, gentamicin and tetracycline administered by oral and/or intramuscular routes, or surgical removal of the infraorbital caseous material), all of which produced low recovery rates. The condition produced a mortality



Figure 1. A – Chukar partridge (*Alectoris chukar*) affected with pronounced infraorbital edema. B – Silver pheasant (*Lophura nycthemera*) with ocular and nasal discharges. C – Golden pheasant (*Chrysolophus pictus*) showing conjunctivitis, ocular discharge and increased infraorbital volume. D – Golden pheasant (*Chrysolophus pictus*; pictured in C); infraorbital area filled with caseous material. The three cases were confirmed to be infected with *Mycoplasma gallisepticum*.

rate of approximately 40%, but most surviving birds suffered from severe ocular sequels and consequently were culled due to commercial devaluation. In February-March 2016, just after the molt, 2 doses (of 1 drop each) of a *Mycoplasma gallisepticum* vaccine (Myco-Galli MG70®)¹, were provided ocularly 28 days apart to all the Galliformes in the flock. Later that year, during the usual period of the disease's annual occurrence (April-July), only 4 clinical cases (2 *Polyplectron bicalcaratum* and 2 *Lophura nycthemera*) were observed, and they were successfully treated at the beginning of the clinical course (the stage when the infraorbital edema was just becoming evident). A combination of 0.2 g tylosin (Tyladen®)² and 0.5 mg flumethasone (Flucortan®)³ was splashed onto the birds' eyes using a syringe, twice daily for 3 days. The birds were released after their wet feathers had been dried with hair dryer.

In this same flock, but in the period September - December 2016, 19 out of 27 chukar partridges (*Alectoris chukar*) were affected and died suddenly. Due to the lack of an available enclosure, a recently acquired group of partridges, comprising both sexes and ages of 1-2 years, was released into the enclosure in which the ring-necked pheasants were kept. The deaths started 30 days after releasing the birds, but signs of the disease were only noticed for 3 birds and included apathy, ruffled feathers and diarrhea. Most birds died suddenly. Eight dead birds with good body condition were submitted for necropsy and showed similar findings; the main changes were seen in the liver and cecum and consisted of well-delimited, focal to multifocal areas of hepatic necrosis (Figure 2). The ceca were largely filled with caseous contents and showed expanded and friable walls in addition to multifocal areas of adherences. In the lumen of the small intestine of all birds there were also large amounts of nematode parasites, which were identified as *Heterakis gallinarum* by a parasitological examination.

It was observed with a microscope that there were multifocal, well-delimited areas of massive lytic necrosis with a multifocal moderate infiltrate of macrophages, sometimes containing a granular brown pigment (hemosiderin) and lymphocytes, as well as multifocal areas of mild to moderate hemorrhage. Admixed in the necrotic areas, there were numerous round to oval, lightly eosinophilic, protozoal trophozoites of 15-20 µm in diameter, occasionally containing a 3-5 µm centrally located basophilic nucleus (histomonads),

which were either extracellular or intrahistiocytic and surrounded by a clear halo. These structures were positive in Periodic Acid Schiff staining (Figure 3). The cecal walls were also markedly thickened, with multifocal, transmural, lytic necrosis areas with abundant infiltrates of macrophages and lymphocytes. The lumen was sometimes filled with large amounts of amorphous, eosinophilic material mixed with cellular debris and a large quantity of coccoid or coccobacillary structures (Figure 4), as well as numerous protozoal organisms in the necrotic areas, similar to those described in the liver. After dosing the whole flock with oral levamisole⁴ (40 mg.kg⁻¹ PO), exchanging and liming the bedding material of the enclosures, and keeping the remaining partridges in an aerial aviary with a wiremesh floor, no additional cases were observed. The farmer reported about 50 losses associated with either of the two conditions each year for the last 3 years.

DISCUSSION

Definitive diagnosis of the two conditions was based on typical signs and lesions [2-8], in addition to complementary IHC [3] and PCR results for confirming mycoplasmosis. High rates of purchase and resale of birds in the absence of appropriate sanitary management (quarantine, routine anthelmintic administration and vaccination), overcrowding, and poor enclosure hygiene were identified as the main predisposing factors in these outbreaks. The difficulties and losses observed in mycoplasmosis cases, despite attempts of different treatment protocols, contrasted with the adequate results observed after disease vaccination.



Figure 2. Chukar partridges (*Alectoris chukar*) affected with well-delimited, circular to multifocal or coalescing areas of necrosis on the hepatic surface (arrows). There is also large area of cecal necrosis (arrowhead). Both lesions are associated with *Histomonas meleagridis* infection.

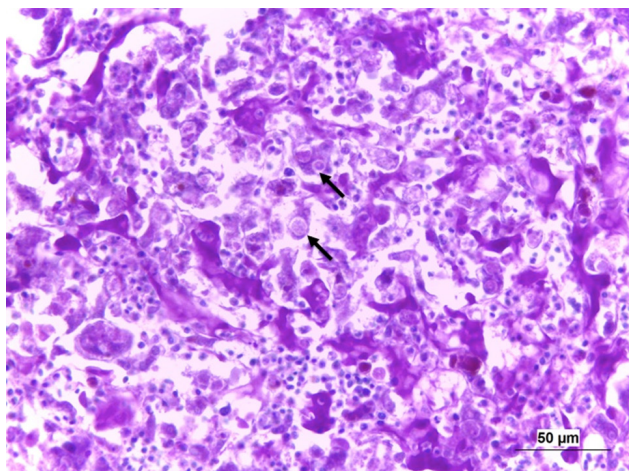


Figure 3. Chukar partridge liver with an extensive focal area of lytic necrosis, abundant histiocytic infiltrate and numerous round to oval, 15–20 µm, Periodic Acid Schiff (PAS)-positive, histomonad trophozoites (arrows), which are either extracellular or intracellular within macrophages and have a clear halo. [PAS staining; bar = 50 µm].

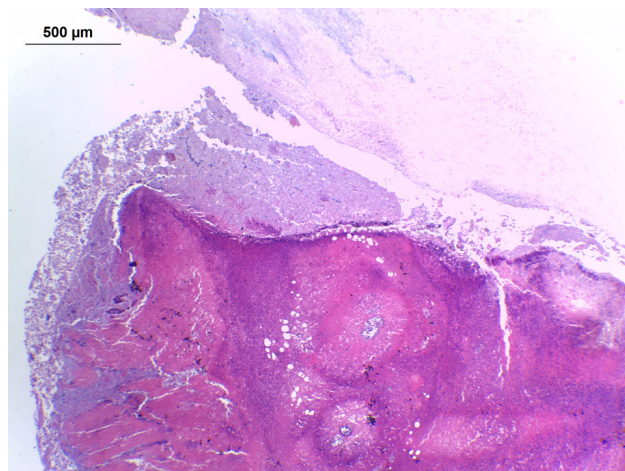


Figure 4. Chukar partridge. Cecum with an extensive focal area of lytic necrosis of the intestinal wall and abundant amorphous, eosinophilic cellular debris on the mucosal surface, covered by coccobacillary structures (bacterial colonies). [HE staining; bar = 500 µm].

Similarly, the prevention of additional histomoniasis-cases could be attributed to the hygienic and sanitary practices applied to the flock [4,11]. In addition to the management of bedding material (exchange and liming), further basic and simple practice such as anthelmintic dosing was effective for the disease control. As was the case in this outbreak, the acquisition of new animals has long been recognized as an important and frequent route for the introduction of new pathogenic agents into the flock [9,11]. The high susceptibility of chukar partridges to histomoniasis, especially when they are kept with resistant species such as ring-necked pheasants, was another risk factor involved in this outbreak [7]. This paper also highlights the valuable role of post-mortem examinations for disease vigilance and control [9-11]. However, local breeders of ornamental birds do not tend to adhere to this procedure, as well as many other measures routinely practiced in most animal production systems. Therefore, disseminating the information included here has additional justifica-

tion. Moreover, since some of the species that are commercially propagated in Brazil, as in other countries, are listed as vulnerable or threatened species in their original environments [5], a higher level of care should be taken for disease prevention. There were records of similar losses to those reported here in at least in 2 additional bird farms visited regularly by our team in 2016. Although it is known that mycoplasmosis and histomoniasis can affect free-range chickens in Brazil [1,3], this communication provides new evidence of the impact that these diseases may have on local flocks of ornamental birds, but also shows that some control measures may be easily performed.

MANUFACTURERS

¹Laboratório Bio-Vet S.A. São Paulo, SP, Brazil.

²Ceva Saúde Animal Ltda. Paulínia, SP, Brazil.

³Zoetis Indústria de Produtos Veterinários Ltda. Campinas, SP, Brazil.

⁴Janssen-Cilag Farmacêutica Ltda. São José dos Campos, SP, Brazil.

Declaration of interest. The authors declare that they have no conflicts of interest. All authors approved the manuscript and its submission to the journal.

REFERENCES

- 1 Araújo J.L., Olinda R.G., Frade M.T.S., Maia L.A. & Dantas A.F.M. 2015. Histomoniasis outbreak in free-range chickens in semiarid Paraíba, Brazil. *Semina: Ciências Agrárias*. 36(1): 307-3012.
- 2 Bradbury J.M., Yavari C.A. & Dare C.M. 2010. Mycoplasmas and respiratory disease in pheasants and partridges. *Avian Pathology*. 30(4):391-396.
- 3 Casagrande R.A., Castro L.A., Rolim V., Wouters F., Boabald F., Souza S.O., Guerra P.R., Silva S.C. & Driemeier D. 2014. Diagnóstico imuno-histoquímico e caracterização anatomopatológica de *Mycoplasma gallisepticum* em galinhas de subsistência. *Pesquisa Veterinária Brasileira*. 34(2):153-161.

- 4 **Davidson W.R. 2009.** Histomonas. In: Atkinson C.T., Thomas N.J. & Hunter D.B. (Eds). *Parasitic Diseases of Wild Birds*. 2nd edn. Oxford: Wiley-Blackwell, pp.154-161.
- 5 **International Union for Conservation of Nature (IUCN). 2015.** The IUCN Red List of Threatened Species. Available in <http://www.iucnredlist.org>. [Accessed online October 2016].
- 6 **Ley D.H. 2008.** *Mycoplasma gallisepticum* Infection. In: Saif Y.M., Fadly A.M., Glisson J.R., McDougald L.R., Nolan L.K. & Swayne D.E. (Eds). *Diseases of Poultry*. 12th edn. Oxford: Blackwell Publishing, pp.807-834.
- 7 **Lund E.E. & Chute A.M. 1971.** Histomoniasis in the Chukar partridge. *The Journal of Wildlife Management*. 35(2): 307-315.
- 8 **McDougald L.R. 2008.** Histomoniasis (Blackhead) and Other Protozoan Diseases of the Intestinal Tract. In: Saif Y.M., Fadly A.M., Glisson J.R., McDougald L.R., Nolan L.K. & Swayne D.E. (Eds). *Diseases of Poultry*. 12th edn. Oxford: Blackwell Publishing, pp.1095-1105.
- 9 **Oliveira L.G.S., Lipinski G.P., Lorenzetti M.P., Rolim V.M., Marques S.T., Driemeier D. & Cruz C.E.F. 2017.** Causes of bird losses recorded in a captive-bred wild bird flock between 2011 and 2015. *Ciência Rural*. [in press].
- 10 **Radostits O.M., Leslie K.E. & Fetrow J. 1994.** Health and Production Management in Beef Feedlots. In: *Herd Health Food Animal Production Medicine*. 2nd edn. Philadelphia: W.B. Saunders Co., pp.394-434.
- 11 **Silva J.C.R. & Corrêa S.H.R. 2007.** Manejo Sanitário e Biosseguridade. In: Cubas Z.S., Silva J.C.R. & Catão-Dias J.L. (Eds). *Tratado de Animais Selvagens - Medicina Veterinária*. São Paulo: Editora Roca Ltda., pp.1226-1244.

