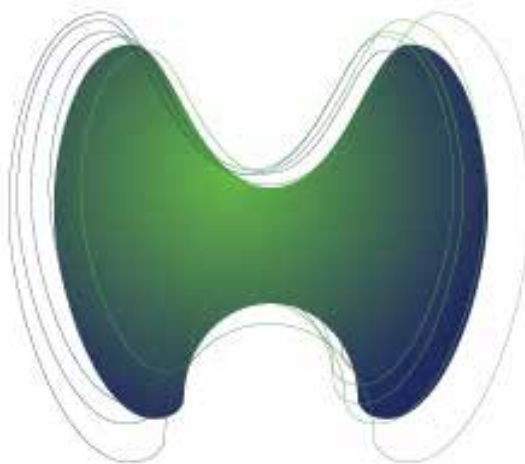


Archives of Endocrinology and Metabolism

OFFICIAL JOURNAL OF THE BRAZILIAN SOCIETY OF ENDOCRINOLOGY AND METABOLISM

Vol. 61 • Supplement 02 – June 2017



**XVI LATIN
AMERICAN
THYROID
CONGRESS**

JUNE 15TH | 18TH 2017



Sociedade Brasileira de
Endocrinologia e Metabologia

55923 UNUSUAL METASTASES FROM DIFFERENTIATED THYROID CANCERInes Califano¹, Anabela Zunino¹, Eduardo Faure¹, Adriana Reyes¹, Rosana Sklate¹, Fabián Pitoia¹, Verónica Ilera¹¹ Departamento de Tíroides de SAEM

Introduction: Complications related to metastatic disease are the main cause of specific mortality in patients with differentiated thyroid cancer (DTC). The most common sites of metastases are lungs and bones. Other localizations are infrequent and they have been reported as isolated cases or small series. The impact of these unusual metastases (UM) in patient management and prognosis remains largely unknown. **Objectives:** to evaluate the prevalence of UM in DTC patients, to define their clinicopathological characteristics and to analyze its relevance in DTC management and mortality. **Patients and methods:** We retrospectively reviewed the file records from 7 databases. UM were diagnosed by: a) biopsy and/or b) radioiodine uptake + elevated thyroglobulin (Tg) levels and/or c) uptake of 18-FDG in the PET-CT scan + elevated Tg levels. We analyzed histopathologic characteristics, clinical presentation, localization, time of diagnosis (synchronic *vs.* metachronic presentation), diagnostic and therapeutic modalities and final outcome of patients. **Results:** UM were diagnosed in 29 out of 2,986 DTC patients (1%). The most common site of UM was the central nervous system (CNS, 31%); the second was skin (20%), followed by liver and non-cervicomedial lymph node (8% each). 21% of the patients had more than one UM. In 93% of the cases, UM coexisted with either lung and/or bone metastases and/or locoregional disease. Papillary histology was found in 75% of cases; 79% were metachronic with DTC diagnosis, and 76% fulfilled radioiodine refractoriness criteria. Half of the patients reported symptoms related to the UM. In 76% of the cases, therapeutic decisions were influenced by the diagnosis of the UM. Median follow-up after the diagnosis of UM was 16 months; 16 patients (55%) died due to DTC related causes, with a mean survival of 8.5 months. The most frequent cause of death was CNS metastasis progression. **Conclusions:** UM are a rare entity in patients with DTC. They are usually metachronic and radioiodine refractory. UM were found in patients with widespread disease, and treatment strategies were modified by their diagnosis. UM were associated with poor prognosis and disease specific mortality.

56604 USEFULNESS OF POST-THERAPY WHOLE-BODY SCAN IN PATIENTS WITH LOW-RISK DIFFERENTIATED THYROID CANCERCarla Fernanda Nava¹, Rafael Selbach Scheffel¹, Jose Miguel Dora¹, Ana Luiza Maia¹, Andre Borsatto Zanella¹¹ Hospital de Clínicas de Porto Alegre

Introduction: Radioactive iodine (RAI) is widely used in the management of differentiated thyroid cancer (DTC). When RAI is indicated, current guidelines indicate a post-therapy whole-body scan (WBS) in order to document iodine's avidity of structural disease, and to update disease stage. However, the utility of the post-therapy WBS for low-risk DTC has been questioned. **Objective:** Evaluate the diagnostic value of post-therapy WBS in the population of low-risk DTC. **Material and methods:** From a cohort of 1045 DTC patients consecutively attended in Thyroid Outpatient Clinic of the Endocrine Division of Hospital de Clínicas de Porto Alegre we selected those who have undergone RAI, performed post-therapy WBS and were classified as low-risk according to the 2009 ATA risk system. Persistent disease was defined as the presence of clinical or radiological and/or biochemical disease (thyroglobulin under suppression > 1 ng/mL and/or stimulated thyroglobulin > 2 ng/mL). **Results:** A total of 295 low-risk DTC patients were studied. The age at diagnosis was 46 ± 14 years, 260 (88%) women, with a tumor of 1.8 cm (P25-P75 1.0-3.0) and 218 (74%) with TNM AJCC stage I disease. The post-operative stimulated-Tg was 5.1 ng/dL (P25-P75 1.3-13.5) and the RAI activity 94 ± 30 mCi. Post-therapy WBS showed no distant metastasis in all studied patients (n= 0/295). At a 6 year (P25-P75 3-9) follow up, 192 (81%) patients were disease free, 36 (15%) had persistent biochemical disease and 10 (3%) structural disease, 5 (1.5%) of which had distant metastases not detected on the post-therapy WBS. **Conclusion:** In low-risk DTC patients, post-therapy WBS do not contribute to risk stratification nor to long term prognosis. Performing the post-therapy WBS in the low-risk population seems unnecessary, and avoiding this procedure could reduce the number of hospital visits and treatment costs.