

## Experimental Ventilator-Associated Pneumonia: Distribution of Lung Infection and Consequences for Lung Aeration

Silvia Regina Rios Vieira, Ivan Goldstein,  
Gilles Lenaour, Charles-Hugo Marquette,  
Jean-Jacques Rouby and the Experimental ICU Study Group

*Surgical Intensive Care Unit, Department of Anesthesiology and Department of Pathology, Pitié-Salpêtrière Hospital, University of Paris VI, France; Unité INSERM 416 of Institut Pasteur and Département Hospitalo-Universitaire de Recherche Experimentale, University of Medicine, Lille, France*

Ventilator-associated pneumonia (VAP) has been described in humans and in experimental animals. The most severe lesions are located in dependent lung segments along a sterno-vertebral axis, however the cephalocaudal distribution of lung infection remains unknown. We used an experimental model to evaluate the distribution of lung infection, considering its anteroposterior and cephalocaudal gradient, and its impact on lung aeration. Ten healthy domestic piglets were anesthetized, paralyzed and mechanically ventilated for 59 hours in the prone position. At the end of the experiment they were sacrificed and their lungs were fixed. Six segments were analyzed: a non-dependant (ND) and a dependant (D) segment of the upper (UL), middle (ML) and lower (LL) lobes. The presence of healthy lung or of histological infectious lesions was analyzed with a semi-quantitative method. The regional distribution of lung infection was compared between upper, middle and lower lobes, as well as between dependant and non-dependant regions. The presence of infectious lesions was correlated with measurements of lung aeration. Nine of the ten piglets developed VAP. Infectious lesions were distributed along a sterno-vertebral and a cephalocaudal gradient; the lower and middle lobes were more frequently infected than the upper lobes. There was an inverse correlation ( $R = -0.902$ ) between the development of lung lesions and lung aeration. In conclusion, VAP was a frequent complication in healthy mechanically ventilated piglets, showing an anteroposterior as well as a cephalocaudal gradient. As expected, development of lung infection was accompanied by a corresponding loss of aeration.

**Key Words:** Ventilator associated pneumonia.

Pneumonia is the most frequent infectious complication in Intensive Care Units (ICU), principally in patients with acute lung injury (ALI) or acute respiratory distress syndrome (ARDS), under mechanical ventilation, and it provokes a high mortality rate [1-6]. Several important issues regarding the pathophysiology, the diagnosis and the treatment of ventilator-acquired pneumonia (VAP) are difficult to

address in humans due to the complexity of this multifactorial disease [7]. Therefore animal models of nosocomial bronchopneumonia (BPN) are important in order to better understand its behavior.

The models of nosocomial pneumonia described in the literature usually include mechanical ventilation, with or without microbial inoculations, but other models, such as tracheal stenosis, have also been associated with pneumonic lesions [7-10]. Two decades ago, Johanson et al. [9,11], in a model that consisted of mechanically ventilated baboons with oleic acid associated ALI, found a pneumonia incidence of as high as 100%, in animals without BPN prevention. Using the same model, Crouch et al. [8] evaluated 32 mechanically-ventilated and non-inoculated baboons (5 controls without acid oleic exposure,

Received on 29 August 2002; revised 16 January 2003.

Address for correspondence: Dr. Silvia Regina Rios Vieira. São Luis, 1127, 501. Porto Alegre, RS, Brazil. Zip code: 90620-170. Phone/Fax: 55 51 33367214. E-mail: srvieira@terra.com.br

**The Brazilian Journal of Infectious Diseases** 2003;7(3):216-223  
© 2003 by The Brazilian Journal of Infectious Diseases and Contexto Publishing. All rights reserved.

8 with acid oleic exposure and no BPN prevention and 19 with acid oleic exposure and BPN prevention) and also found a 100% incidence of BPN in animals not receiving prophylaxis. Some years later, in an analysis of 17 pigs submitted to a model of tracheal stenosis, Marquette et al. [10] found bronchopneumonic lesions in 12 of them. In a more recent study, the same group [7] described an experimental model of pneumonia used on 62 pigs that were ventilated for 4 days, or that developed pneumonia after inoculation. In mechanically ventilated pigs, VAP developed in 17 of 18 without antibiotic prophylaxis and in 4 of 9 with prophylaxis with Ceftriaxone. This model resembles human VAP in its histological, bacteriologic and pathogenic aspects and it has been used in recent studies concerning VAP [12-14].

In this experimental model [7], it has also been shown that infectious lesions are predominant and more severe in the dependant lung regions, confirming the anteroposterior gradient observed previously in ARDS patients [15,16]. Possibly, these lesions also follow a cephalocaudal gradient, as seen in ARDS patients [16], but this has never been demonstrated. The relationship between development of lung infection and degree of lung aeration seems obvious, however an objective demonstration has never been reported.

We evaluated the distribution of lung infection, considering its anteroposterior and cephalocaudal gradients and its consequence on lung aeration, with an experimental model similar to VAP.

## Materials and Methods

*The experimental intensive care unit.* An experimental Intensive Care Unit (ICU) was initiated in Lille, in 1997, by the Surgical ICU group from La Pitié-Salpêtrière Hospital (University of Paris VI from Paris) in collaboration with the Department of Pneumology of A Calmette Hospital (CHU from Lille). Two beds in this ICU were fully equipped with cardiovascular monitors (Hewlett-Packard, USA), ventilators (Taema, France) and electric infusers. A medical team composed of two physicians was on-call on a 24-hour period shift. Two technicians were present daily from 9 am to 5 pm.

*Animal preparation.* Ten healthy domestic Largewhite-Landrace piglets, aged 3-4 months were anesthetized using Propofol ( $3 \text{ mg.kg}^{-1}$ ) and orotracheally intubated in the supine position with a 7.0 Hi-Lo Jet Mallinckrodt tube (Mallinckrodt Inc., Argyle, NY). Anesthesia was maintained with a continuous infusion of Midazolam ( $0.3 \text{ mg.kg}^{-1}.\text{h}^{-1}$ ), Pancuronium ( $0.3 \text{ mg.kg}^{-1}.\text{h}^{-1}$ ) and Fentanyl ( $5 \mu\text{g.kg}^{-1}.\text{h}^{-1}$ ). A catheter was inserted into the right femoral vein for continuous infusion of 10% Dextrose ( $1.5 \text{ ml.kg}^{-1}.\text{h}^{-1}$ ) and Ringer Lactate ( $3 \text{ ml.kg}^{-1}.\text{h}^{-1}$ ) with an infusion pump, and the femoral artery was cannulated with a 3F polyethylene catheter (Plastimed, St Leu la Forêt, France) for pressure monitoring and blood sampling. An 8F suprapubic urinary catheter (Vesicoset, Angiomed, Karlsruhe, Germany) was placed in the bladder trans-abdominally. All animals were treated according to the guidelines of the Department of Experimental Research of Lille University and according to the Guide for the Care and use of Laboratory Animals (NIH Publication No. 93-23, revised 1985).

*Measurements.* After anesthesia and technical preparation, the piglets were placed in the prone position. They were mechanically ventilated in a volume-controlled mode with a Cesar type 1 ventilator (Taema, Antony, France). The initial ventilatory parameters consisted of a tidal volume ( $V_t$ ) of  $15 \text{ ml.kg}^{-1}$ , a respiratory rate (RR) of 15 breaths per minute, an I/E ratio of 0.5 and zero positive end-expiratory pressure (ZEEP). Inspired gases were humidified using a conventional humidifier (MR290, Fisher Paykel, New Zealand) and an initial  $\text{FiO}_2$  of 0.21 was used. Airway pressure was measured at the distal tip of a Hi-Lo Jet endotracheal tube. Pressure-Volume curves were performed on the Cesar ventilator after a 3-second end-expiratory pause. According to a previously validated technique [17] a low constant flow of  $9 \text{ l.min}^{-1}$  was delivered during 9.6 sec and the P-V curve was displayed on the screen of the ventilator. Respiratory compliance was determined as the slope of the linear portion of the P-V curve. Respiratory resistance was calculated as the division of the difference between inspiratory pressure and plateau pressure by constant inspiratory flow. Blood gases were analyzed at  $37^\circ\text{C}$

with an ABL120 blood gas analyzer (Radiometer Copenhagen, Denmark). All data were recorded on a strip-chart recorder (Gould ES1000, Gould instruments, Cleveland, OH).

No inoculations with microorganisms were made. The piglets were mechanically ventilated during a maximum of 60 hours, or less if they died before, with a fixed tidal volume of  $15\text{ml.kg}^{-1}$ . Hemodynamic parameters, airway pressures, respiratory compliance, respiratory resistance, blood gases, hemograms and blood lactate levels were determined at steady state and every 6 hours. Throughout the protocol,  $\text{FiO}_2$  was increased in order to maintain  $\text{PaO}_2$  above 80 mm Hg, whenever necessary.  $\text{PaCO}_2$  was kept between 35 and 45 mm Hg by increasing the respiratory frequency to the maximum level preceding the appearance of auto-PEEP. Above this limit, hypercapnia was tolerated. Septic shock, defined as a 30% decrease of mean arterial pressure, persisting despite rapid 500 ml intravenous fluid loading, was treated by Norepinephrine infusion. In the case of a sudden increase in airway pressures or hemodynamic failure, pneumothorax was suspected and drained promptly. Sacrifice was performed at day 3, if death had not occurred earlier.

*Fixation of the lungs.* Following death and the intravenous injection of Heparin (5000 U), a sternotomy was performed, while maintaining mechanical ventilation, and the piglets were exsanguinated by cardiac puncture. Along with sections of the main bronchi and pulmonary vessels, the left lung was removed, weighed and fixed by intrabronchial instillation of a solution composed of 10% Formalin, 10% 70° ethanol, 30% polyethylene glycol and 50% water. The lung was filled in order to reach a pulmonary volume close to the functional residual capacity. The instillation was stopped when the lung placed in the thorax exactly fit within the rib cage volume. The filling procedure had pressure limited to 40 cm  $\text{H}_2\text{O}$ , determined by the elevation of the reservoir containing the fixative. This technique of fixation was aimed at avoiding artifactual overdistension of normally ventilated lung areas. After fixation, the lung was sagittally sectioned in

the middle. Six segments were used for histological analysis. They were taken from dependant (D) and non-dependant (ND) regions from the upper, middle and lower lung regions.

*Assessment of lung aeration.* The aeration of all lobules of each of the six lung segments was analyzed. A computerized image analyzer system (Leica: Q500IW Cambridge, UK) was coupled to a high-resolution color camera (JVC KYF 3 CCD, Japan) and an optical microscope with a 2.5x objective (Leitz, Wetzlar, Germany). An interactive software - QUIPS (Quantimet Image Processing Software Leica Cambridge, UK) was used to detect air space structures. A special computerized program that was developed to quantify lung aeration [14] was used. Each histological section was analyzed on a computer connected to the optical microscope and the optical camera. Each optical field was analyzed as an automatically delineated rectangular elementary unit, with an area of  $2.289\text{ mm}^2$ . Within the main unit, aerated lung structures were automatically identified by a color encoding system. "Air-like" structures, such as pulmonary vessels and interlobular septa, were visually detected and manually "deselected" in order to include only lung aeration alveolar and air-filled bronchiolar structures. Lung aeration of the elementary unit, expressed in percentage, was computed as the area of alveolar and bronchial air-filled structures divided by the difference between  $2.289\text{ mm}^2$  and the area of "air-like" structures. For each lobule, lung aeration was computed as the mean lung aeration of all elementary units present in the histological section within the lobule. Overlapping between different elementary units when changing the optical field was visually avoided by referring to histological hallmarks.

*Histological classification.* A histological analysis of bronchopneumonia was also subjectively made for each lobule. Lung samples were processed for routine histological preparation and embedded in paraffin. Sections with a thickness of  $4\text{ }\mu\text{m}$  were cut from the block and stained with hematoxylin-eosin.

Bronchopneumonic lesions were assessed in each secondary pulmonary lobule present in a given histological section, and classified into five different categories, as previously described [1,18]. Bronchiolitis was defined as the proliferation of polymorphonuclear leukocytes within the bronchial lumen, leading to the formation of purulent plugs associated with necrosis and disruption of bronchial mucosa; interstitial bronchopneumonia was defined as the presence of scattered neutrophilic infiltrates localized to alveolar septa and terminal bronchioles; focal bronchopneumonia was defined as a localized intense proliferation of polymorphonuclear leukocytes near terminal bronchioles and surrounding alveoli; confluent bronchopneumonia was defined as an extension of these elementary lesions to one or several adjacent pulmonary lobules; purulent bronchopneumonia was defined as confluent bronchopneumonia associated with tissular necrosis and disruption of normal lung architecture. Total alveolitis was considered as all alveolar infectious lesions together. Each lobule was evaluated for the presence of healthy lung or of infectious lesions and the percentages of each were subjectively quantified. The presence, in each lobule, of alveolar disruption, bronchiolar distension, pseudocysts and alveolar atelectasis was also evaluated subjectively.

*Statistical analysis.* Baseline hemodynamic and respiratory parameters were compared with final parameters by a paired Student t-test. The comparison between the percentages of lung aeration, healthy lung and lung lesions in different lung regions was done by analysis of variance or the Student t-test. The correlation between lung aeration and normal lung or infected lung was tested by linear regression analysis. The statistical analysis was performed using Statview 5.0 (SAS Institute inc., Cary, NC, USA). All data were expressed as mean  $\pm$  standard deviation (SD) on tables and mean  $\pm$  SEM on graphics. The statistical significance level was fixed at 0.05.

## Results

Ten healthy pigs were studied. They had been mechanically ventilated for a mean of 59.3 hours. Nine

completed the protocol of 60 hours and one died a few hours before (at 54 hours) due to severe acute respiratory failure (ARF). During the protocol two animals developed septic shock; receiving rapid 500 ml intravenous fluid loading and treated with Norepinephrine, and three developed severe ARF, requiring adjustments in the mechanical ventilation.

Vital measurements were made at the beginning and at the end of the protocol; there was an increase in temperature, while heart rate, mean arterial pressure,  $\text{PaO}_2/\text{FIO}_2$  ratio,  $\text{DO}_2$ , tidal volume and respiratory compliance decreased (Table 1). The hematological measurements did not change significantly during the experiment ( $22,000 \pm 8,300$  versus  $21,300 \pm 9,300$  leukocytes and  $10.3 \pm 1.3$  versus  $8.6 \pm 1.5$  hemoglobin level). The lactate levels also did not change ( $2.2 \pm 2.3$  versus  $1.9 \pm 1.9$ ).

We found pneumonic lesions in 9 of the 10 piglets. Eight to ten lobules were analyzed in each of sixty pulmonary segments, giving a total of 532 lobules. Most of the lobules had some normal lung tissue, but we also found interstitial pneumonia and alveolitis (Table 2). In some cases, we found severe infectious lesions. In our analysis of the 532 lobules, interstitial pneumonia was observed in 378 (71%), alveolitis in 473 (89%), confluent pneumonia in 176 (33%), suppurative pneumonia in 104 (20%) and bronchiolitis in 249 (47%).

The distribution of the estimated percentage of healthy lung and of alveolitis, as well as the measurement of lung aeration, followed a cephalocaudal as well as an anteroposterior gradient (Figures 1 and 2). Aeration and normal lung appearance decreased from the apex to the base and from non-dependant to dependant regions. The percentage of alveolitis increased in the same direction. As expected, there was a positive correlation between lung aeration and estimated percentage of healthy lung, and a negative correlation of lung aeration with estimated percentage of total alveolitis (Figure 3). The upper lobes were less frequently compromised ( $p < 0.05$ ) than the middle and lower lobes (Figure 1).

When non-infectious complications of mechanical ventilation were examined, many of the lobules showed some degree of alteration. Among the 532 lobules, alveolar disruption was observed in 245 (46%),

**Table 1.** Cardiorespiratory characteristics of healthy piglets at basal condition and after 60 hours of mechanical ventilation

|   | Basal      | End of protocol | P value* |
|---|------------|-----------------|----------|
| Temperature   | 38.0 ± 1.9 | 39.7 ± 0.8      | 0.04     |
| HR (bpm)  | 178 ± 22   | 144 ± 13        | 0.01     |
| MAP (mm Hg)   | 120 ± 21   | 89 ± 15         | 0.01     |
| MPAP (mm Hg)  | 18.6 ± 7.3 | 23.0 ± 10.3     | NS       |
| PAOP (mm Hg)  | 5.2 ± 1.7  | 4.7 ± 2.4       | NS       |
| CO (L.min <sup>-1</sup> )                                   | 3.8 ± 1.2  | 3.8 ± 1.0       | NS       |
| SVR (dynes.s.cm <sup>-5</sup> .m <sup>2</sup> )             | 2597 ± 797 | 2032 ± 876      | NS       |
| PVR (dynes.s.cm <sup>-5</sup> .m <sup>2</sup> )             | 285 ± 115  | 348 ± 247       | NS       |
| PaCO <sub>2</sub> (mm Hg)                                   | 37 ± 5.5   | 45 ± 9.5        | NS       |
| PaO <sub>2</sub> /FIO <sub>2</sub>                          | 411 ± 84   | 225 ± 147       | 0.01     |
| DO <sub>2</sub> (ml.min <sup>-1</sup> .m <sup>-2</sup> )    | 519 ± 170  | 359 ± 64        | 0.04     |
| VO <sub>2</sub> (ml.min <sup>-1</sup> .m <sup>-2</sup> )    | 148 ± 83   | 125 ± 37        | NS       |
| Qs/Qt (%)   | 2.6 ± 2.4  | 17 ± 21         | NS       |
| PetCO <sub>2</sub> (mmHg)                                   | 34 ± 7.2   | 31 ± 9.7        | NS       |
| RR (breaths/min)  | 15 ± 0.5   | 17 ± 3.6        | NS       |
| Vt (ml)   | 382 ± 29   | 341 ± 38        | 0.001    |
| Ppeak (cm H <sub>2</sub> O)                                 | 20 ± 2     | 31 ± 17         | NS       |
| Ppl (cm H <sub>2</sub> O)                                   | 17 ± 3     | 22 ± 11         | NS       |
| Crs (ml.cm H <sub>2</sub> O <sup>-1</sup> )                 | 35 ± 7     | 22 ± 8          | 0.004    |
| Rrs (cm H <sub>2</sub> O.L <sup>-1</sup> .s <sup>-1</sup> ) | 3.0 ± 1.5  | 6.7 ± 4.9       | NS       |

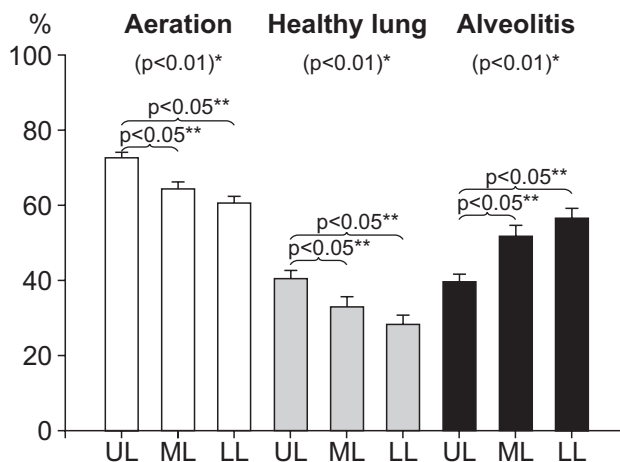
HR = heart rate; MAP = mean arterial pressure; MPAP = mean pulmonary artery pressure; PAOP = pulmonary artery occlusion pressure; CO = cardiac output; SVR = systemic vascular resistance; PVR = pulmonary vascular resistance; PaCO<sub>2</sub> = arterial pressure of CO<sub>2</sub>; PaO<sub>2</sub> = arterial pressure of oxygen; FIO<sub>2</sub> = inspired fraction of oxygen; DO<sub>2</sub> = oxygen delivery; VO<sub>2</sub> = oxygen consumption; Qs/Qt = pulmonary shunt; PetCO<sub>2</sub> = end-tidal CO<sub>2</sub>; RR = respiratory rate; Vt = tidal volume; Ppeak = peak pressure; Ppl = plateau pressure; Crs = compliance of respiratory system; Rrs = resistance of respiratory system; \*t-test.

**Table 2.** Percentages of healthy lung, interstitial pneumonia and total alveolitis quantified in different lung regions

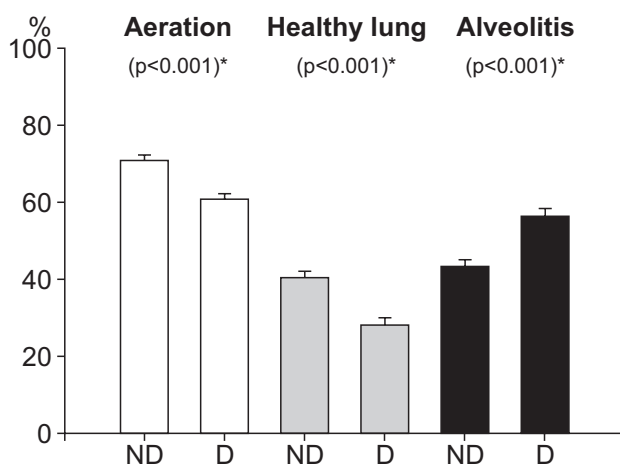
|                            | UL      | ML      | LL      | p   | ND      | D       | p   |
|----------------------------|---------|---------|---------|-----|---------|---------|-----|
| Healthy Lung (%)           | 41 ± 28 | 33 ± 32 | 29 ± 30 | **‡ | 40 ± 29 | 28 ± 31 | *** |
| Interstitial Pneumonia (%) | 19 ± 11 | 14 ± 10 | 14 ± 12 | *‡  | 16 ± 10 | 16 ± 12 | NS  |
| Alveolitis (%)             | 40 ± 27 | 52 ± 33 | 57 ± 32 | **‡ | 43 ± 29 | 56 ± 33 | *** |

UL= upper lobe; ML= medium lobe; LL= lower lobe; ND= non dependent regions; D= dependent regions; \* p<0.05, \*\* p<0.01 and \*\*\* p<0.001 using ANOVA ; ‡ p<0.05 comparing UL versus ML and UL versus LL with the t-test.

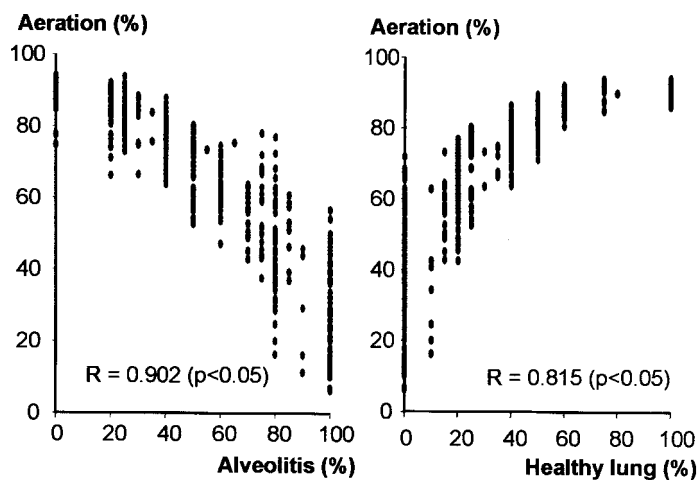
**Figure 1.** Percentage of aeration, healthy lung and alveolitis in upper (UL), medium (ML) and lower lobes (LL); \*p value comparing segments with ANOVA; \*\* p value comparing UL *versus* ML or LL with the t test.



**Figure 2.** Percentage of aeration, healthy lung and alveolitis in non-dependent (ND) and dependent (D) regions; \*p value comparing segments with the t test.



**Figure 3.** Correlation between percentage of lung aeration versus alveolitis and versus healthy lung.



bronchiolar distension in 444 (83%), pseudocysts in 94 (18%) and alveolar atelectasis in 365 (69%).

## Discussion

Nine of the ten healthy piglets that were mechanically ventilated for 60 hours developed ventilator associated pneumonia (VAP). Lung infection followed anteroposterior as well as cephalocaudal gradients, and there was an inverse correlation between lung aeration and lung infection.

The high incidence of VAP in our animal model was expected, based on previous reports in the literature. It has been shown that mechanically ventilated baboons develop endogenous pulmonary infection [8,9,11]. It is also known that piglets rapidly develop endogenous pneumonia due to mechanical impairment of mucociliary clearance in a post-obstructive pneumonia model [10,19]. In an animal model, similar to the one we used here, Marquette et al. [7] found a VAP incidence of 94% (17/18) in a control group of mechanically ventilated pigs. The reasons for such a high incidence of pneumonia are unknown [7], however various mechanisms are possible. One possibility is mechanical impairment of mucociliary clearance, as observed in post-obstructive pneumonia [10,19]. Another possibility is a loss of upper respiratory tract immunity. Kudsk et al. [20], comparing parenteral with enteral nutrition in mice, found that the former could cause an impairment of upper respiratory tract immunity that can result in a high incidence of pneumonia. In addition, inter-animal contamination, among piglets being kept together, cannot be excluded.

Also, this high incidence of VAP is in agreement with observations made on mechanically-ventilated patients. Although the incidence of VAP in clinical studies is generally not as high as observed in animals, it is also very high. Its incidence varies from 10 to 70%, in different populations, and depending on the criteria used to establish the diagnosis, being higher in ARDS patients [3-6]. When lungs from mechanically ventilated patients who had died in an ICU were analyzed, histological lesions of bronchopneumonia were found in 52% of them (43 of 83) [1]. The reasons for this high clinical incidence of VAP are probably the same as we discuss here.

The histological lesions were distributed along an

anteroposterior gradient, confirming previous descriptions of a predominance of experimental infectious lesions in dependant regions [7]. We also found a cephalocaudal gradient, with lower lobes being more compromised than upper lobes. This fact had not been demonstrated previously. Both anteroposterior and cephalocaudal gradients are in agreement with the lung lesion distributions observed in ARDS patients [15,16]. These gradients appear to be due to the participation of gravity, as well as intra-abdominal pressure, in the development of lung injuries.

The correlation between the presence and intensity of lung lesions with lung aeration was expected, but had not been documented. The computer software, which had been especially designed for measuring alveolar aeration, demonstrated this phenomenon quite clearly.

Differently from Marquette et al. [7], we observed, in a subjective analysis, non-infectious lesions, such as alveolar disruption, bronchiolar distension, pseudocysts and/or alveolar atelectasis in many of the piglets, confirming previous clinical observations [21]. In a clinical study, Rouby et al. [21] found that underlying histological lesions, responsible for clinical lung barotrauma, consist of pleural cysts, bronchiolar dilatation, alveolar overdistension and intra-parenchymal pseudocysts. We cannot, however, indicate mechanical ventilation as the only cause of those barotraumatic lesions. Even the piglets were not sick when connected to the mechanical ventilator, most of them developed VAP during the study. Therefore, it is not possible to discriminate between the influences of the mechanical ventilation alone and infectious lesions in the development of the lesions that we found. Other studies are needed to examine the correlation between mechanical ventilation, infectious lesions and barotrauma.

In conclusion, with this model of VAP, we have shown that lung infection is a frequent complication of mechanical ventilation, developing in most (9/10) of the healthy, mechanically-ventilated piglets. The pattern of distribution of infectious lesions followed an anteroposterior as well as a cephalocaudal gradient, being more frequent in lower than in upper lobes. As expected, lung infection was accompanied by a corresponding loss of aeration.

## Acknowledgements

Silvia Vieira received a Post-Doctorate award from CAPES (Brazil).

## Members of the Experimental ICU Study

The following members of the Experimental ICU Study Group participated in this study: Q. Lu, L. Puybasset, C. Vezinet, Pierre Coriat, Réanimation Chirurgicale, Pitié-Salpêtrière Hospital, Paris, France; Jack Richecoeur, Réanimation Médicale, Pontoise, France; Pablo Gusman, Department of Anesthesiology, Santa Casa de Misericórdia, Juiz de Fora, MG, Brazil; L. Malbouisson, Department of Anesthesiology, Hospital Das Clínicas, Sao Paulo, Brazil; Y. Lecharpentier, Department of Pathology, Pitié-Salpêtrière Hospital, Paris, France; Frederic Wallet, Department of Pneumology, A Calmette Hospital, Lille, France.

## References

1. Rouby J.J., Martin De Lassale E., Poete P., et al. Nosocomial bronchopneumonia in the critically ill. Histologic and bacteriologic aspects. *Am Rev Respir Dis* **1992**;146:1059-66.
2. Vincent J.L., Bihari D.J., Suter P.M., et al. The prevalence of nosocomial infection in intensive care units in Europe. Results of the European Prevalence of Infection in Intensive Care (EPIC) Study. EPIC International Advisory Committee. *Jama* **1995**;274:639-44.
3. Fagon J.Y., Chastre J., Vuagnat A., et al. Nosocomial pneumonia and mortality among patients in intensive care units. *JAMA* **1996**;275:866-9.
4. Chastre J., Trouillet J.L., Vuagnat A., et al. Nosocomial pneumonia in patients with acute respiratory distress syndrome. *Am J Respir Crit Care Med* **1998**;157:1165-72.
5. Marcowicz P., Wolff M., Djedaïni K., et al. Multicenter Prospective Study of Ventilator-Associated Pneumonia During Acute Respiratory Syndrome. *Am J Respir Crit Care Med* **2000**;161:1942-8.
6. Ibrahim E.H., Tracy L., Hill C., et al. The occurrence of ventilator-associated pneumonia in a community hospital: risk factors and clinical outcomes. *Chest* **2001**;120:555-61.
7. Marquette C.H., Wermert D., Wallet F., et al. Characterization of an animal model of ventilator-acquired pneumonia. *Chest* **1999**;115:200-9.
8. Crouch T.W., Higuchi J.H., Coalson J.J., Johanson W.G., Jr. Pathogenesis and prevention of nosocomial pneumonia in a nonhuman primate model of acute respiratory failure. *Am Rev Respir Dis* **1984**;130:502-4.
9. Johanson W.G., Jr., Seidenfeld J.J., de los Santos R., et al. Prevention of nosocomial pneumonia using topical and parenteral antimicrobial agents. *Am Rev Respir Dis* **1988**;137:265-72.
10. Marquette C.H., Wallet F., Copin M.C., et al. Relationship between microbiologic and histologic features in bacterial pneumonia. *Am J Respir Crit Care Med* **1996**;154:1784-7.
11. Johanson W.G., Jr., Holcomb J.R., Coalson J.J. Experimental diffuse alveolar damage in baboons. *Am Rev Respir Dis* **1982**;126:142-51.
12. Goldstein I., Bughalo M.T., Marquette C.H., et al. Mechanical ventilation-induced air-space enlargement during experimental pneumonia in piglets. *Am J Respir Crit Care Med* **2001**;163:958-64.
13. Goldstein I., Wallet F., Nicolas-Robin A., et al. Lung penetration of inhaled amikacin during experimental bronchopneumonia in ventilated piglets. *AJRCCM* **2001**;163:A928.
14. Elman M., Goldstein I., Marquette C.H., et al. The lung aeration influences pulmonary concentrations of nebulized and intravenous amikacin in ventilated piglets with severe bronchopneumonia. *Anesthesiology* **2002**;96.
15. Gattinoni L., Mascheroni D., Torresin A., et al. Morphological response to positive end expiratory pressure in acute respiratory failure. Computerized tomography study. *Intensive Care Med* **1986**;12:137-42.
16. Puybasset L., Cluzel P., Chao N., et al. A computed tomography scan assessment of regional lung volume in acute lung injury. *Am J Respir Crit Care Med* **1998**;158:1644-55.
17. Lu Q., Vieira S.R., Richecoeur J., et al. A simple automated method for measuring pressure-volume curves during mechanical ventilation. *Am J Respir Crit Care Med* **1999**;159:275-82.
18. Fabregas N., Torres A., El-Ebiary M., et al. Histopathologic and microbiologic aspects of ventilator-associated pneumonia. *Anesthesiology* **1996**;84:757-9.
19. Marquette C.H., Mensier E., Copin M.C., et al. Experimental models of tracheobronchial stenoses: a useful tool for evaluating airway stents. *Ann Thorac Surg* **1995**;60:651-6.
20. Kudsk K.A., Li J., Renegar K.B. Loss of upper respiratory tract immunity with parenteral feeding. *Ann Surg* **1996**;223:629-35; discussion 635-8.
21. Rouby J.J., Lherm T., Martin de Lassale E., et al. Histologic aspects of pulmonary barotrauma in critically ill patients with acute respiratory failure. *Intensive Care Med* **1993**;19:383-9.