

UNIVERSIDADE FEDERAL RIO GRANDE DO SUL
FACULDADE DE ODONTOLOGIA
PROGRAMA DE POS GRADUAÇÃO EM ODONTOLOGIA

YALIL AUGUSTO RODRÍGUEZ CÁRDENAS

**MUDANÇAS RADICULARES EM CANINOS SUPERIORES IMPACTADOS E PRÉ-
MOLARES ADJACENTES APÓS TRAÇÃO ORTODÔNTICA COM MOLAS
HELICOIDAIS: UM ESTUDO LONGITUDINAL RETROSPECTIVO COM EXAMES
DE TCFC**

Porto Alegre

2019

YALIL AUGUSTO RODRÍGUEZ CÁRDENAS

**MUDANÇAS RADICULARES EM CANINOS SUPERIORES IMPACTADOS E PRÉ-
MOLARES ADJACENTES APÓS TRAÇÃO ORTODÔNTICA COM MOLAS
HELICOIDAIS: UM ESTUDO LONGITUDINAL RETROSPECTIVO COM EXAMES
DE TCFC**

Tese apresentada ao Programa de Pós-Graduação em Odontologia, linha de pesquisa Diagnóstico das Afecções Buco-Faciais, da Universidade Federal do Rio Grande do Sul, como parte dos pré-requisitos necessários para a obtenção do título de Doutor em Clínica Odontológica.

Orientador: Prof. Dr. Heraldo Luís Dias da Silveira

Porto Alegre

2019

CIP - Catalogação na Publicação

Rodríguez Cárdenas, Yalil Augusto
MUDANÇAS RADICULARES EM CÁNINOS SUPERIORES
IMPACTADOS E PRÉ-MOLARES ADJACENTES APÓS TRAÇÃO
ORTODÔNTICA COM MOLAS HELICOIDAIS: UM ESTUDO
LONGITUDINAL RETROSPECTIVO COM EXAMES DE TCFC / Yalil
Augusto Rodríguez Cárdenas. -- 2019.
63 f.
Orientador: Heraldo Luis Dias da Silveira.

Tese (Doutorado) -- Universidade Federal do Rio
Grande do Sul, Faculdade de Odontologia, Programa de
Pós-Graduação em Odontologia, Porto Alegre, BR-RS,
2019.

1. Dente Canino. 2. Dente imactado. 3. Tomografia
Computadorizada de Feixe Cônico. I. Dias da Silveira,
Heraldo Luis, orient. II. Título.

Elaborada pelo Sistema de Geração Automática de Ficha Catalográfica da UFRGS com os
dados fornecidos pelo(a) autor(a).

Agradecimentos

À **Deus**, por estar comigo em todos os momentos.

À minha esposa **Ita**, por sua compreensão e apoio incondicional.

Ao meu filho **Adrián Tomás**, por ser o motor que move minha vida.

Aos meus pais, **Maria y Efrain**, pelo grande presente que através deles me foi dado.

Ao meu orientador, Prof Dr **Heraldo Luis Dias da Silveira**, por sua amizade, ensinamentos e orientação permanente.

Aos meus amigos e irmãos **Luis y Armando**, pelo constante apoio, entusiasmo e confiança neste projeto

À coordenação e professores do **Programa de Pós-graduação da FO-UFRGS**.

Resumo

Introdução: Os caninos superiores impactados (CSI) historicamente têm sido uma importante razão para a consulta ortodôntica devido ao alto impacto estético e funcional que representam em um indivíduo. Apesar de ser um tema amplamente estudado, existem poucos relatos encontrados na literatura sobre os efeitos da tração ortodôntica de caninos em sua raiz e em estruturas adjacentes. Os objetivos deste estudo foram: 1. Comparar alterações dimensionais radiculares entre os caninos superiores impactados (CSI) por vestibular e palatino, antes e após a tração ortodôntica; 2. Comparar as alterações dimensionais radiculares no osso alveolar e nos premolares adjacentes aos caninos superiores impactados por vestibular e palatino, antes e após a tração; e 3. Avaliar a influência da complexidade do tratamento de tração ortodôntica dos caninos superiores impactados sobre a sua dimensão radicular, do pré-molar adjacente e seu osso alveolar. **Metodologia:** Trata-se de um estudo retrospectivo longitudinal, sendo que para o primeiro objectivo, a amostra foi composta por exames de Tomografias Computadorizadas de Feixe Cônico (TCFC) de 30 indivíduos com CSI uni e bilateral, pré e pós tração ortodôntica, compondo um total de 43 CSI que foram divididos em 2 grupos: vestibular (n=17) e palatino (n=26). Para o segundo objectivo, a amostra compreendeu exames de TCFC de 25 indivíduos com CSI uni e bilateral pré e pós tração ortodôntica, e um total de 36 primeiros pré-molares adjacentes que foram divididos em 2 grupos de acordo com o lado de impacção: vestibular (n=17) e palatino (n=21). As medidas de comprimento e área do canino e pré-molar adjacente foram realizadas nas secções coronais, sagitais e axiais. As dimensões do osso alveolar adjacente foram avaliadas no corte coronal. Variáveis demográficas, características esqueléticas também foram obtidas. **Conclusões:** A posição do canino impactado não teve influencia sobre as alterações dimensionais em sua raiz após a tração, exceto na secção axial cervical onde houve aposição. No pré-molar e osso alveolar adjacentes, a tração ortodôntica não teve influencia sobre as alterações dimensionais. A complexidade da tração ortodôntica do CSI por vestibular ou palatino não interfere nas alterações dimensionais de sua raiz, do pré-molar e osso alveolar adjacentes.

Palavras-chave: Dente Canino, Dente impactado, Tomografia Computadorizada de Feixe Cônico.

Abstract

Introduction: Historically maxillary impacted canines (MIC) have been an important reason for an orthodontic appointment due to the high aesthetic and functional impact they represent in an individual. Despite being a widely studied topic, there are few reports in the literature about the effects of orthodontic traction on the root of themselves and on adjacent structures. The aims of this study were: 1. To compare dimensional root changes between buccal and palatal MIC, before and after the traction with coil springs; 2. To compare the dimensional root and alveolar bone changes in the first premolar adjacent to MIC (PAMIC), between buccal and palatine MICs, before and after the traction with coil springs; and 3. To determine the influence of the orthodontic traction treatment's complexity of MIC on the radicular dimensions, and adjacent premolar and its alveolar bone. **Methodology:** Longitudinal, retrospective study. For the first objective, the sample was constituted by Cone Beam Computed Tomographies (CBCTs) pre and post-orthodontic traction, of 30 subjects with unilateral and bilateral MIC, for a total of 43 MIC that were divided into 2 groups: buccal (n = 17) and palatal (n = 26). For the second objective, the sample consisted of CBCTs pre and post-orthodontic traction of MIC uni or bilateral of 25 subjects, for a total of 36 PAMICs that were divided into 2 groups: buccal (n = 15) and palatal (n = 21). MIC and PAMIC root changes in length and area were measured in the coronal, sagittal and axial sections. The alveolar bone dimensions of the PAMIC were evaluated in the coronal section. Demographic variables, occlusal and skeletal class characteristics were also obtained. **Conclusions:** The impacted canine position does not have an influence on the dimensional alterations in its root after traction except in the axial cervical section where there was apposition. The complexity of orthodontic traction of CSI by vestibular or palatal does not interfere with the dimensional alterations of its adjacent root, premolar, and alveolar bone.

Key-words: Tooth, impacted. Cuspid. Cone Beam Computed Tomography.

Lista de Abreviaturas e Siglas

MIC	<i>Maxillary impacted canine</i>
CSI	<i>Canino Superior Impactado</i>
CBCT	<i>Cone Beam Computed Tomography</i>
ANB	<i>Angle ANB (A point, Nasion point, B point)</i>
APDI	<i>Antero Posterior Dysplasia Indicator</i>
SNA	<i>Angle SNA (Sella point, Nasion point, A point)</i>
T₀	<i>Initial time, before canine traction</i>
T₁	<i>After canine traction</i>
SPSS	<i>Statistical Package for Social Sciences</i>
DICOM:	<i>Digital Imaging and Communication in Medicine</i>
FOV:	<i>Field of View</i>
MPR:	<i>Multiplanar Reconstruction</i>
MIP:	<i>Maximum Intensity Projection</i>
PAMIC	<i>First premolar adjacent to MIC</i>
RR	<i>Root resorption</i>
ICC	<i>Intraclass Correlation Coefficient</i>
mA	<i>miliamp</i>
kVp	<i>peak kilovoltage</i>
ALADA	<i>As Low As Diagnostically Acceptable</i>
ALARA:	<i>As Low As Reasonably Achievable</i>
RDA	<i>Root Dilaceration Angle</i>
LBD	<i>Length Before Dilaceration</i>
LAD	<i>Length After Dilaceration (LAD),</i>
TL	<i>Total Length</i>
ICP	<i>Iterative Closest Point</i>
BAT	<i>Buccal Alveolar Thickness</i>
PAT	<i>Palatal Alveolar Thickness</i>
AAA	<i>Alveolar Axial Axis</i>
MUAW	<i>Maximum Upper Alveolar Width</i>
BBH	<i>Buccal Bone Height</i>
PBH	<i>Palatal Bone Height</i>
FOV	<i>Field of View</i>

Sumário

Introdução	9
Objetivos	13
Artigo 1	14
Artigo 2	35
Considerações Finais	57
Referências	59
Anexo 1	61
Anexo 2	62
Anexo 3	63
Anexo 4	64

Introdução

Caninos superiores impactados (CSI) continuam a ser uma razão importante para a consulta odontológica. Eles são o segundo tipo de dente mais freqüentemente impactado, após os terceiros molares inferiores e a frente dos caninos e pré-molares inferiores [1,2]. Sua incidência apresenta diferença entre populações, variando de 2,39% na população norte-americana [3] a 5,2% em grupos europeus [4]. Em geral, sua prevalência maior é feminina sendo relatada proporções de até 3,2 vezes mais em mulheres [5], e é 3 a 6 vezes mais frequente por palatino que por vestibular [6-10].

A teoria da origem genética é suportado por Baccetti [4] e Peck e Kataja [5] que relatam fortes associações entre várias anomalias dentárias (aplasia do segundo pré-molares, pequenos incisivos superiores laterais, infraoclusão primeiros molares e hipoplasia do esmalte) e o canino maxilar deslocado para palatino. Becker [11] descreve um cenário alternativo, a teoria da guia, [6] em que a forma e tempo de desenvolvimento de raízes laterais incisivos, geralmente dilacerada em casos caninos impactados por palatino, juntamente com a presença de outras anomalias dentárias, poderia causar condições ambientais que poderiam gerar o deslocamento ectópico deste dente. Jacoby [8] apoia esta teoria adicionando factores anatómicos como localização do germe do canino cercado pela órbita, pela parede anterior do seio maxilar e pela fossa nasal. A presença de espaço extra dado por uma possível agenesia do incisivo lateral, ou sua erupção prematura e/ou do pré-molar, poderia gerar as condições necessárias para a impactação do canino por palatino. A deficiência no comprimento do arco maxilar explicaria apenas a impactação do canino por vestibular, uma vez que seu desenvolvimento acontece nesta área. Bishara [2] menciona a existência de factores gerais que favorecem impacção canino maxilar

como: doenças endócrinas, febre, factores locais, discrepância alveolodentária, presença prolongada ou perda prematura de germe do canino decíduo, presença de fenda palatina, anquilose dentária e cistos ou formas neoplásicas.

A avaliação dos efeitos produzidos pela tração de um canino maxilar impactado tem sido estudada historicamente em radiografias convencionais. A incorporação na odontologia de novas técnicas de imagem tridimensionais, como a Tomografia Computadorizada de Feixe Cônico (TCFC), permitiu avaliações espaciais por imagem antes e depois de tratamentos. Hettiarachchi, Olive e Monsour [12] estudaram a morfologia de canino impactado por vestibular utilizando TCFC e encontraram que as suas raízes são mais curtas em comparação com um grupo controle, sem impacção dentária, combinando sexo e idade. Silva *et al* [13] avaliaram os efeitos da tração ortodôntica no comprimento da raiz dos caninos e dentes adjacentes impactados. Utilizaram uma amostra de caninos superiores impactados unilaterais, com controle do lado oposto, não impactado. Por meio de medições em TCFC, concluíram que não houve diferenças significativas nos comprimentos. Apesar do acesso que muitas populações têm aos exames tomográficos, não existem estudos científicos até o momento em que são avaliados com TCFC pré e pós-tratamento, os efeitos da tração de um CSI em sua raiz e nas estruturas anatômicas vizinhas, nem as possíveis associações com sua posição inicial impactada.

Os dentes adjacentes a um CSI mais estudados são os incisivos laterais. A maioria das pesquisas se concentra em sua morfologia e envolvimento com base óssea em imagens antes do início da tração ortodôntica do canino. Seguem, nesta ordem, os incisivos centrais e os primeiros pré-molares. Woloshyn *et al* [14] avaliaram as radiografias intraorais e extra-orais convencionais bidimensionais de caninos

superiores unilateralmente impactados, antes e após o tratamento. Verificaram que há um encurtamento no comprimento das raízes dos pré-molares adjacentes, 1,27 mm, em média, em comparação com o lado contralateral. Yan *et al* [15] avaliaram TCFC pré-tratamento de CSI por palatino e vestibular. Concluíram que a proximidade física de menos de 1 mm entre a coroa do canino e a raiz do dente adjacente é preditor da reabsorção radicular, com uma prevalência de 27% nos incisivos laterais, 18% nos incisivos centrais e 10% nos primeiros pré-molares. Além disso, eles relatam o comprometimento pulpar em 36%, 57% e 0%, respectivamente. Não encontraram diferenças na prevalência de reabsorção por vestibular ou palatino. Eles também encontraram uma associação entre o estado de formação radicular do canino e o grau de reabsorção radicular dos incisivos laterais centrais superiores. Cao *et al.* [16] investigaram a influência de impacção vestibular sobre os pré-molares adjacentes a superfície da raiz por meio de TCFC de indivíduos com caninos superiores impactados e relataram alta prevalência de duas raízes separadas no primeiro pré-molar.

O tratamento dos caninos superiores impactados envolve a aplicação específica de uma força ortodôntica com molas de níquel titânio, cadeias de força ou fios com alguma modificação para tração que poderiam gerar reabsorções radiculares nos dentes vizinhos. Métodos que incluem uma grande ancoragem com arco rígido e botão Nance com suportes e projeções de fios para puxar o canino também são usados. Em média, a tração de um CSI leva cerca de seis meses em um tratamento convencional, mas a força requerida elevada pode causar reabsorções apicais, principalmente em incisivos, sem descartar pré-molares e molares até mesmo utilizados como unidade de ancoragem [17].

O presente estudo busca testar três hipóteses: 1. Não há mudanças na raiz entre os caninos superiores impactados vestibulares e palatinos após a tração com as molas de Ni-Ti fechadas. 2) Não há alterações radiculares e ósseas entre o primeiro pré-molar adjacente ao CSI por vestibular ou palatino após a tração com molas de Ni-Ti fechadas. 3) A complexidade do tratamento ortodôntico de um canino superior impactado não influencia a alteração dimensional radicular própria ou do pré-molar adjacente.

Objetivos

Objetivo geral

Comparar os efeitos da tração ortodôntica do CSI por vestibular versus palatino sobre a sua morfologia radicular, do pré-molar e osso adjacentes.

Específicos

- Comparar alterações dimensionais radiculares entre os caninos superiores impactados vestibular e por palatino, antes e depois da tração (contemplado no artigo 1).
- Comparar as alterações dimensionais radiculares no premolar e osso alveolar adjacentes aos caninos superiores impactados por vestibular e por palatino, antes e após a tração (contemplado no artigo 2).
- Determinar a influência da complexidade do tratamento ortodôntico dos caninos superiores impactados sobre a sua morfologia radicular e do pré-molar e osso adjacentes, antes e após a tração (contemplado nos artigos 1 e 2).

Root changes in buccal vs palatal maxillary impacted canine after orthodontic traction: a 3-dimensional before and after evaluation

Rodríguez-Cárdenas Yalil Augusto, Arriola-Guillén Luis Ernesto, Ruíz-Mora Gustavo Armando, Aliaga-Del Castillo Aron, Dias-Da Silveira Heraldo Luis

ABSTRACT

Background: The aim of this study was to evaluate the 3-dimensional root changes in buccal vs palatal maxillary impacted canines (MIC) after orthodontic traction.

Methods: Pretreatment and after traction cone beam computed tomography scans (CBCTs) of 30 subjects with unilateral/bilateral MIC were used. A total of 43 MIC were divided into 2 groups: buccal or palatal MIC. Root changes in length and area after orthodontic traction were measured at sagittal, coronal and axial sections. Intergroup comparison was carried out by t or U Mann-Whitney tests, depending on normality. Multiple linear regression analysis was used to evaluate the influence of all predictor variables on root changes ($P < 0.05$). **Results:** A significant difference between groups was found for root area changes in the upper limit of the cervical third at axial section that showed greater appositional values for the palatal impacted canine group (1.80 mm^2 ; $P = 0.024$). Position of impaction influenced the increase of root area in the coronal section and in the upper limit of the cervical third at axial section. Age influenced in the decrease of total length and root area in sagittal and coronal sections, respectively. **Conclusions:** Orthodontic traction of MIC produces similar root changes in both buccal and palatal impacted canines, except for root area change in the upper limit of the cervical third at axial section, which showed greater appositional changes in the palatal impaction group. Impaction position and age influence the increase and decrease of root area and length of some specific radicular regions.

Key words: Maxillary impacted canine, Cone Beam Computed Tomography, root changes.

BACKGROUND

Maxillary impacted canines (MIC) are considered one of the most difficult scenarios that orthodontist may face, due to the high control in biomechanics that its treatment requires. The most important sequel that they produce is root resorption (RR) of adjacent teeth, which represents an irreversible, asymptomatic and undesirable consequence.¹ To identify them, cone beam computed tomography (CBCT) has become one of the most reliable imaging methods for diagnosis, treatment planning and for evaluating the adjacent teeth at pre² and posttreatment.³

Changes in the MIC after its orthodontic traction have been mainly studied in the periodontal tissues.^{4,5} Root length evaluations after orthodontic traction⁶ or alignment/leveling phase⁷ with periapical radiographs, show controversial results; decrease or no difference in canine length when compared with groups with no canine impaction. One study using CBCT⁸ only taking into account the sagittal section, did not find significant differences after impacted canine traction when compared with the contralateral non-impacted canine. Literature regarding root changes in MIC after traction is limited and generally focuses on the characteristics before orthodontic traction and not in the effects that traction itself may cause to its root.

It could be thought that there are differences in the traction vectors between MIC buccal and palatal, being the latter more complex, since it consumes more time, and has a longer path of traction. It has to pass through a greater alveolar thickness that includes displacements in the three axes of space, while in buccal cases, the movement is directly to the vestibular cortical plate, always with a distal vector (X axis) and extrusive forces towards the occlusal plane (Y axis).

This biomechanical inequality could lead to a different biological response between both impaction conditions. Nevertheless, these aspects had not been previously evaluated. Therefore, the purpose of this study is to evaluate the 3-D root changes, in buccal vs palatal MIC after orthodontic traction, and to assess the factors that may influence these changes.

The hypothesis to test is that the position of impaction (buccal / palatal) does not influence on the root morphology changes of maxillary canine after its adequate orthodontic traction.

Materials and methods

This retrospective study was approved by the local Ethics in Research Committee. In addition, all patients and their legal guardians (when necessary) provided informed consent allowing the treatment and CBCT records acquisition. The study included 30 patients (with a total of 43 MIC) that received diagnostic and treatment in a private clinic. CBCT records were obtained at pretreatment (T_0) and after orthodontic traction of MIC, when the treated canine reached the occlusal plane (T_1). A minimum sample size of 17 teeth per group was necessary to have 80% of power, to detect a difference between groups of 1.85 mm^2 in the root area of the upper limit of the cervical third at axial section, using a standard deviation of 2.19 mm^2 (obtained from a previous pilot study) and with a level of significance of 0.05.

Inclusion criteria were: patients of both sexes, older than 12 years, with at least one canine, buccally or palatally impacted (unilateral or bilateral impaction); no loss of permanent teeth, with complete apical closure of the MIC at the beginning of traction. Complete records, including demographic information, study models, intra and extraoral photographs, panoramic and lateral radiographs and CBCT images, had to be available. Exclusion criteria were: craniofacial anomalies or syndromes, periapical lesions or odontomas circumscribed to the MIC, history of previous orthodontic treatment, and history of trauma. Skeletal sagittal relationships (ANB and APDI⁹), the characteristics of the impacted canine (condition, sector, angle α , angle β , height¹⁰) and the duration of orthodontic traction were recorded.

For training and calibration, three orthodontists were trained to perform the diagnostic of impaction and its classification by sector and position. In case of any discrepancy, the final diagnosis of impaction was decided by consensus. Inter-observer diagnostic and positional agreement was assessed by the Kappa coefficient, obtaining values greater than 0.9. For quantitative CBCT measurements, the same evaluator repeated the measurements after a 30-day interval. Then, intra-observer agreement was calculated with intraclass correlation coefficient (ICC) that was over 0.9. Random errors were calculated using the Dahlberg's formula and were smaller than 1 mm or 1 mm^2

From the 30 patients included, 43 MIC were obtained and classified into two groups according to their condition as buccal or palatal impacted canines. This classification was based in the evaluation of axial views, using the following criteria:^{11,12} visualization of the MIC and its interpretation, position of the impacted canine crown in relation to a midline drawn between the two cortical, and its location in relation to the neighboring lateral incisor or temporary canine. In addition, clinical visualization of mucoperiosteal prominence of the MIC and the place of surgical approach (buccal/palatal).

All CBCT scans were obtained using PaX-Uni 3D (Vatech Co., Ltd., Hwaseong, South Korea) with the following parameters: 4.7 mA, 89 kVp and exposure time 15 seconds. Each field of view mode was 8cm x 8cm, with a voxel size of 0.2 mm. DICOM images were analyzed with Dolphin-3D software (version 11.8 Dolphin Imaging, Chatsworth, Calif), with multiplanar and 3D reconstructions.

The diagnostic of impaction sector was made in panoramic images synthesized from the CBCTs. The classification by Ericson and Kurol was applied.¹⁰ The cusp tip of the canine was located in one of five sectors (Figure 1, right). To determine the canine position, the angles α , β , and the height defined by Ericson and Kurol were used.¹⁰ (Figure 1, left). The angle α is formed between the inter-incisor midline and long axis of canine; the angle β between long axis of canine and long axis of lateral incisor; and the canine vertical height was evaluated using the distance "d" defined as the perpendicular distance of the peak of the cuspid of the impacted canine to the occlusal plane formed by a tangent to the incisal edge of maxillary central incisor and the occlusal surface of the maxillary first molar.¹⁰

The initial lateral cephalometric radiographs of each patient were obtained with a digital cephalometric panoramic equipment (Pax 400C Vatech Co., Ltd., Hwaseong, South Korea), set at 90 Kv, 10mA, 13-15seconds. All cephalometric measurements were digitally obtained with Dolphin-3D software (version 11.8 Dolphin imaging Systems, Chatsworth, Calif), without magnification, and a scale 1:1. Skeletal relationship was expressed by the ANB and APDI angles. The maxillary sagittal position was determined using the SNA angle.

Initial radicular measurements

The Dicom of CBCTs were processed with the same software. Sagittal, coronal and axial sections of each MIC were obtained. The corresponding CBCT section was aligned with the longitudinal tooth axis in the coronal and sagittal plane, positioning the largest mesio-distal diameter of the MIC crown perpendicular to the sagittal plane in the coronal section, and perpendicular to the coronal plane in the coronal sagittal (Figure 2). Then, on the longitudinal tooth axis, the root lengths were measured in mm from a line connecting the mesial and distal enamel-cement junction in the coronal section, and buccal- palatal in the sagittal section up to the vertex of canine radicular apex (TL: total length).

In the event of presence of any root dilaceration, the angle formed by the dilacerated root segment (root dilaceration angle, RDA) with the axial axis of the MIC was measured along with the root length before dilaceration (LBD), and the root length after dilaceration (LAD), both in the coronal section (RAC) and in the sagittal section (RAS). In these cases, the total length (TL) was measured as the sum of LBD plus LAD. When the radicular evaluation in both sections did not show presence of some degree of radicular curvature, it was considered a zero degrees value. The root areas of the MIC in mm² were evaluated beginning from the distal enamel-cement junction along the root contour until the mesial enamel-cement junction in the coronal section; and from the buccal enamel-cement junction, continuing along the contour of the entire root until the palatal enamel-cement junction in the sagittal section (Figures 3 and 4). In axial sections the root areas were measured in three sectors. To define the sectors in each time, the total root length of the coronal section was divided into three thirds and the areas at the upper limit of the cervical and middle thirds in the axial sections were measured, together with the axial area of the root zone of dilaceration origin (Figure 5). The location of axial areas measured in T₀ was the same for T₁. The coronal section was taken as reference because it presented the broadest and most frequent dilaceration angles, compared to the sagittal section.

Canine traction technique and orthodontic treatment

A single rigid temporary anchorage device associated with an acrylic palatal button soldered on first permanent molar bands was used. The appliance was

customized with 1.2mm (0.047") stainless steel wire (Dentaurum, Ispringen, Germany) and included multiple palatal-occlusal-vestibular soldered hooks in 0.028" stainless steel wire to achieve MIC traction (Fig. 6). Nickel-titanium closed coil springs 0.010"x 0.036" 8mm and 13mm long exerting 100g or 150g force (Dentos Inc. Daegu, Korea) were used to perform the intraosseous transalveolar traction. They were activated (4-5mm) every 4 to 8 weeks until complete the MIC traction (until they reached the occlusal plane). After traction, CBCTs (T₁) were taken with the same technical characteristics of the initial one, to control the treatment and supervise the RR of maxillary incisors.¹³

Final measurement of roots and root changes

Length and root area were measured in the same sagittal, coronal and axial sections, as well as the angle of dilaceration in the sagittal and coronal sections. In order to measure changes in each canine, the final value (T₁) was subtracted from the initial value (T₀). Positive values of the difference indicate resorptive changes and negative values indicate appositional changes.

Statistical analyses

Statistical analysis was performed using SPSS Ver. 19.0 for Windows (IBM SPSS, Chicago, Illinois, USA). Descriptive statistics of root change in mm and area in mm² of each canine was calculated for both buccal and palatal impaction group. Data normality was determined with Shapiro-Wilk test. Independent-T or U Mann-Whitney tests were used (depending on data normality) for intragroup and intergroup comparisons. Finally, a multiple linear regression model was applied to evaluate the influence of each variable on the root change, considering all the variables as predictors. An initial regression analysis with all predictors followed by a second new regression analysis with only predictor variables showing P values smaller than 0.25 was performed for each tooth (over-fit method).¹⁴ Statistical significance was set at P<0.05 for all the tests.

RESULTS

The initial characteristics of the sample, according to impaction sector are summarized in Tables 1 and 2. Intragroup comparisons did not show significant

differences. Intergroup comparisons showed a statistically significant difference for root area changes in the upper limit of the cervical third, axial section (1.80 mm^2 ; $P=0.024$) that revealed appositional values for the palatal impacted canine group (-1.18 mm^2) and resorptive values for the buccal impacted canine group (0.62 mm^2) (Table 3).

Linear regression analysis based on the over-fit method ($P<0.25$) showed that the position of impaction significantly influenced the root area changes in the coronal section ($P=0.019$) and in the upper limit of the cervical third, axial section ($P=0.016$), increasing the root area in MIC with this position (Table IV). Age significantly influenced the total length ($P=0.013$) and root area changes ($P=0.003$) in sagittal and coronal sections, respectively by decreasing the total length and root area in these specific sections (Table 4). The other predictor variables did not show statistically significant influence ($P>0.05$).

DISCUSSION

The objective of this study was evaluate the root changes after orthodontic traction of palatal vs buccal maxillary impacted canines. This is one of the few studies that establishes this 3-D comparison. The CBCTs used in this study, were required to supervise and control RR of maxillary incisors after MIC traction. In this view it's essential familiarize the new concept of ALADA "as low as diagnostically acceptable",¹⁵ which is a modification of ALARA principles "as low as reasonably achievable";¹⁶ in the recommendations of SEDENTEXCT project,¹⁷ which conclude that in the context of diagnosis of RR, the CBCT can be indicated when the 2-D images are not enough; and in the recommendations of the AAO and the AAOMR¹⁸ about use of CBCT during treatment of dental position anomalies, defined as "possibly indicated" according to the complexity of the cases and the need to follow up possible RR and undesirable effects of the orthodontic traction on neighbor structures. These aspects are difficult to evaluate with conventional 2D radiographs.

It could be argued that a control group, including non-tractioned maxillary canines, should be used to compare our results. However, in this specific study we did not aimed to perform this comparison because of the evidently different mechanics

involved in MIC traction when compared with conventional retraction or orthodontic alignment and leveling in patients without MIC.

The only statistically significant difference between groups (Table 3) was showed in the axial area, upper limit of the cervical third. In this region, the palatal MIC group presented a negative change of -1.18 mm^2 and the buccal MIC group change was 0.62 mm^2 . The negative sign in the first group indicates root area increase, while in the buccal MIC traction induced RR. This interesting finding can be related to a higher tissue activity in this area, it may be related to cement apposition or resorption.

This outcome was reinforced by the multiple regression analysis results (Table 4) that indicates a significant influence of the impaction position on root area in the coronal section and in the upper limit of the cervical third of the axial section

Associating the results of intergroup comparisons and the multiple linear regression analysis, it could be suggested that palatal impaction is apparently able to produce increase in root areas in these specific regions. However, the influence of this variable combined to other variables included in the regression model, explains only 16% and 23% of the root area change in these regions (Table 4). The effect of other variables, such as the amount of force applied to the canine, the vectorial sequence of traction (magnitude, direction), the bone density around and other variables not taken into account (transverse maxillary dimensions, arch length, inter-premolar and molar width before and after traction), was not measured in this regression model.

In the opinion of the authors, another possible explanation of this significant finding it could be related with a hypercementosis. The region of significant change is located in the limit between the root cervical third and medium third, corresponding to an axial tomographic segment of the root that in the present study had 0.2 mm width and its axial area is higher in palatal MIC than in buccal MIC. Root cement is the most external tissue in this region. Therefore, it should be considered the likelihood of excessive production of cement (hypercementosis). Hunter and Brierley¹⁹ reported this as a common characteristic of unerupted teeth, periapical inflammation or associated to some syndromes. Manson-Hing²⁰ refers association in non-severe cases of mechanical trauma, similar to orthodontic traction. The differentiation of root cement kinds in this sample could not be studied in our dentomaxillofacial images, but

this finding suggests that it is necessary to conduct histologic studies to confirm these speculations.

A feasible explanation for the possible presence of hypercementosis in this root ring of palatal MIC is the proximity of this region with the anatomic site of the canine center of resistance and the different mechanics that includes different force vectors compared with buccal MIC. At the level of the center of resistance of the canine, the greatest tensions of a complex orthodontic mechanics will be reflected, like those from forced traction. Additionally, the palatal MIC have a longer traction path until the occlusal plane that could be associated with the cement apposition of around this area, which has a different behavior in the buccal MIC.

The linear regression analysis also shows the influence of age on root changes in the coronal area and total sagittal length (Table 4). The results indicate that palatal impacted canines have more tendency to present RR than buccal impacted canines in this sections. This finding is clinically relevant because indicates that in older patients is expected more RR in the whole crown area and in total sagittal length, particularly when the MIC is palatal. This finding is not coincident with Elhaddaoui *et al*²¹ that did not find association between age or canine position of impaction and RR in their study in panoramic radiographs. It is not either in agreement with Hettiarachchi *et al*²² that using CBCT reported the presence of shorter roots of impacted canines, compared with a control group, with the same age and sex, without dental impactions.

The presence of apposition and resorption in root areas, both in palatal and buccal MIC, supports the concept that a similar radicular behavior it is expected after similar traction procedures, but with differences among root regions, that could be positive in some and negative in other radicular regions. These differences reflect the dynamics of changes related to orthodontic traction.

The limitations of this CBCT study may be related to the sample size, which could be the cause of the non-significant differences found in the other comparisons, and the use of uni- and bi-dimensional tools to obtain a 3-D evaluation. There are now alternative methods to evaluate by CBCT, the structural changes in hard tissues, using advanced morphometry with semilandmarks, Euclidean distance matrix analysis, position curves, curve distances or tensor-based morphometry. However, these

methods include complex mathematic information that is not easy to interpret by clinicians.²³ The superimposition of CBCT, either by voxel based method²⁴ or by ICP (Iterative Closest Point)²⁵ has been successfully applied in some studies,^{26,27} and allows the evaluation of growth, treatment changes, stability, diagnostic of asymmetries, dental morphology and position, qualitative and quantitative analysis of dental and skeletal displacements and accurate evaluation of TMJ, among other applications.¹⁸

Some investigators consider the superimposition of CBCT as an accurate method,²⁸ but others criticize the accuracy of this technique.²⁹ The interpretation of results depends on the reference structure used for register and the training of the evaluator.³⁰ In the present study we used a method to describe root morphology in the three planes of the space using 2D tools, measuring length in mm and area in mm². The method may be easy to use and interpret by any clinician and it is reproducible. Despite its limitations, the findings provide useful information about the 3-D changes of MIC.

CONCLUSIONS

- Orthodontic traction of MIC produces similar root changes in both buccal and palatal impactions, except for root area change in the upper limit of the cervical third, at the axial section that showed greater appositional changes in a palatal impaction group.
- Position of impaction influenced the increase of root area in the coronal section and in the upper limit of the cervical third, at the axial section.
- Age has influence in the decrease of the total length and root area in sagittal and coronal sections, respectively.

TABLES

Table 1. Initial characteristics of the sample according to impaction condition – Qualitative variables.

Variable	Categories	Condition		Total
		Buccal	Palatal	
Sex (all cases were buccal or palatal in the bilateral group)	Male	6	7	13
	Female	5	12	17
	Total	11	19	30
Impacted canine location	Unilateral	7	12	19
	Bilateral	10	14	24
	Total	17	26	43
Impaction sector	Sector 1	2	2	4
	Sector 2	3	2	5
	Sector 3	8	9	17
	Sector 4	3	9	12
	Sector 5	1	4	5
	Total	17	26	43

Table 2. Initial characteristics of the sample according to impaction condition - Quantitative variables.

Measurements	Impaction condition				Mean difference	Lower limit CI -95%	Upper limit CI 95%
	Buccal = 17		Palatal = 26				
	Mean	SD	Mean	SD			
Age	15.82	6.06	21.12	6.97	-5.29	-9.47	-1.11
ANB	4.02	2.87	3.59	2.64	0.43	-1.29	2.15
APDI	80,16	5.90	84.29	4.77	-4.13	-7.42	-0.83
SNA	83.37	5.42	87.54	4.58	-4.17	-7.27	-1.07
Maxillary length ANS -PNS	49.09	6.76	49.90	4.47	-0.81	-4.26	2.64
Height of impacted canine	13.80	4.05	9.20	2.11	4.60	2.67	6.53
Angle α of impacted canine	52.02	17.48	44.93	14.16	7.09	-2.81	16.99
Angle β of impacted canine	54.63	22.45	42.36	12.87	12.27	0.91	23.64

Table 3. Comparison of maxillary canine root changes impacted (length and area) between T₀ and T₁, according to canine impaction groups.

Section	Measurements	Impaction condition				Mean difference	Confidence interval to 95%		P
		Buccal (n=17)		Palatal (n=26)			Lower limit	Upper limit	
		Mean	SD	Mean	SD				
Coronal	Root change in mm (LAD)†	-0.40	1.14	0.00	1.38	-0.40	-1.25	0.46	0.534
	Root change in mm (LBD)†	0.84	1.30	1.55	7.39	-0.71	-4.52	3.09	0.110
	Root change in mm (TL) ‡	0.30	1.11	0.15	0.96	0.15	-0.49	0.79	0.639
	Root angulation change in degrees (RAC) ‡	-0.01	18.43	2.98	17.39	-2.99	-14.20	8.23	0.594
	Root area change in mm ² ‡	-0.37	8.11	-4.19	10.99	3.82	-2.46	10.10	0.227
Sagittal	Root change in mm (LAD)‡	0.03	0.87	-0.98	2.37	1.00	-0.83	2.83	0.225
	Root change in mm (LBD)†	0.01	1.11	0.96	2.93	-0.95	-3.22	1.32	0.218
	Root change in mm (TL)†	-0.31	1.18	0.15	1.17	-0.45	-1.19	0.29	0.452
	Root angulation change in degrees (RAS)†	-2.92	24.12	-0.40	32.96	-2.52	-21.31	16.26	0.284
	Resorption area change in mm ² ‡	0.82	8.67	1.08	13.78	-0.26	-7.85	7.33	0.945
Axial	Root area change in upper limit of cervical third in mm ² ‡	0.62	2.19	-1.18	2.64	1.80	0.24	3.36	0.024*
	Resorption area change in upper limit of middle third in mm ² †	0.10	3.85	-1.74	5.21	1.84	-1.13	4.82	0.419
	Root area change in curve of dilaceration in mm ² †	-1.93	4.89	-0.95	5.66	-0.98	-4.44	2.48	0.688

***Statistically significant at P<0.05**

LAD, *length after dilaceration*; LBD, *length before dilaceration*; TL, *total length*.

†U Mann-Whitney Test

‡T-Test

Table 4. Influence of the predictor variables with *P* values smaller than 0.25 in the changes of total length at sagittal section and root area changes at coronal, sagittal, and cervical third at axial sections.

Predictor Variables	Total length (TL) in sagittal section (mm)	
	β	P
(Constant)	1.093	0.518
Position of canine	0.152	0.690
Sex	-0.672	0.068
Age	0.071	0.013*
Maxilar length	-0.052	0.162
Impaction sector	0.115	0.496
R2	0.262	
Predictor Variables	Root area changes in coronal section (mm ²)	
	β	P
(Constant)	-11.130	0.008*
Position of canine	-7.416	0.019*
Age	0.680	0.003*
R2	0.233	
Predictor Variables	Root area changes in sagittal section (in mm ²)	
	β	P
(Constant)	0.719	0.920
Duration	1.211	0.106
Angle α	-0.261	0.209
Complexity (angle $\alpha >40^\circ$)	6.652	0.269
R2	0.083	
Predictor Variables	Root area changes in the upper limit of the cervical third of axial section (in mm ²)	
	β	P
(Constant)	2.068	0.132
Position of canine	-2.145	0.016*
Duration	-0.145	0.271
R2	0.161	

* Statistically significant at $P < 0.05$

FIGURES

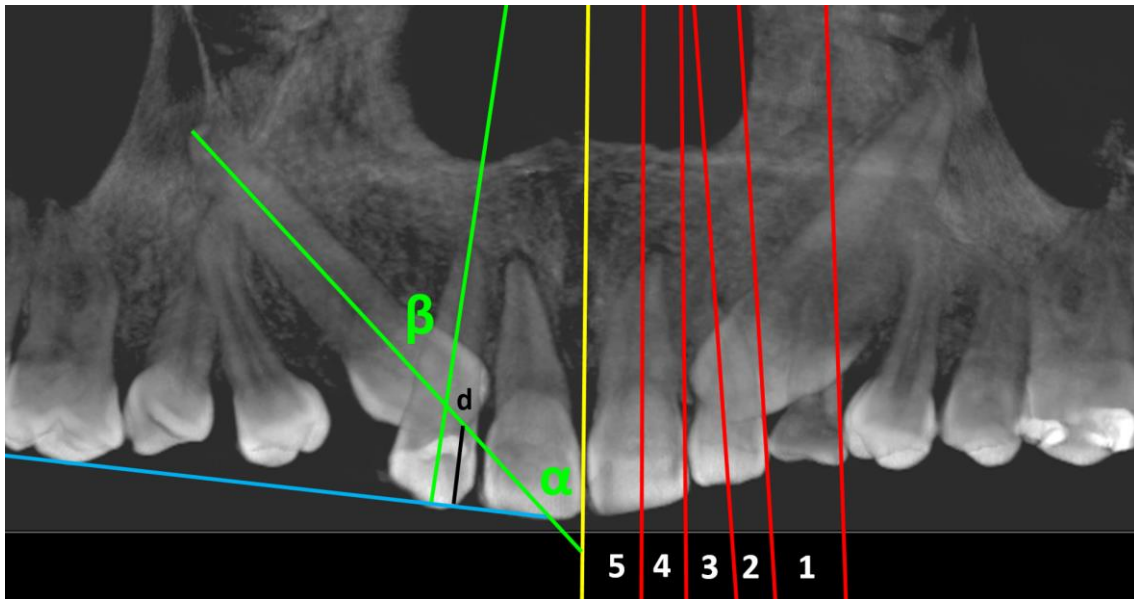


Figure 1. Right side: Anteroposterior assessment of MIC position, according to Ericson and Kurol.¹⁰ Left side: Evaluation of α , β angles and "d" distance.

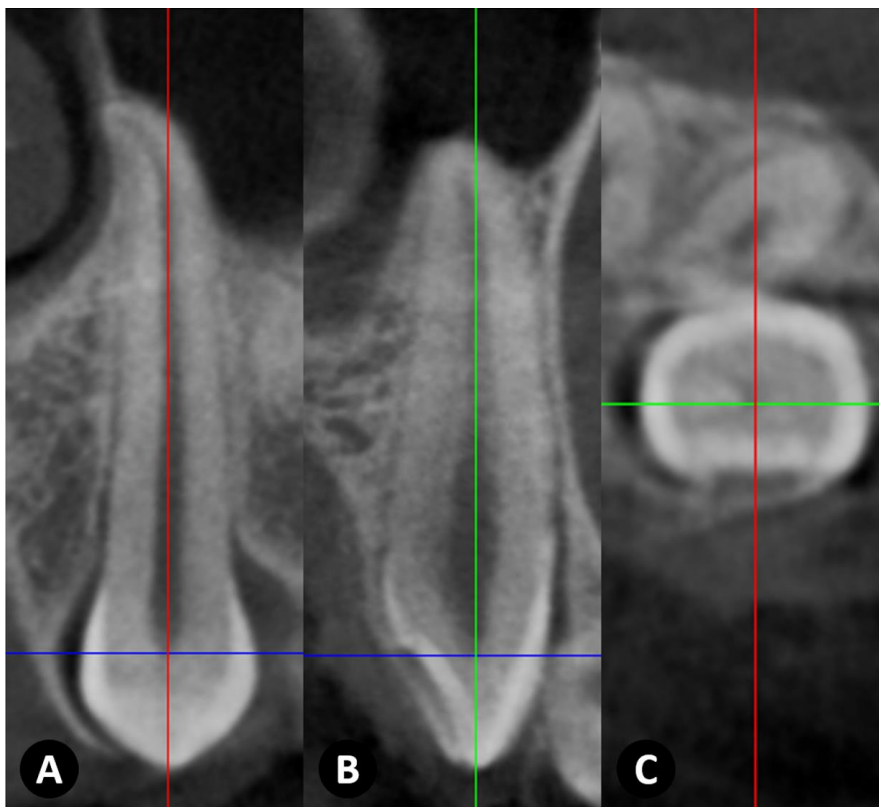


Figure 2. Location of the MIC main axis in A, coronal; B, sagittal; and C, axial sections; previous to the assesment of the variables.

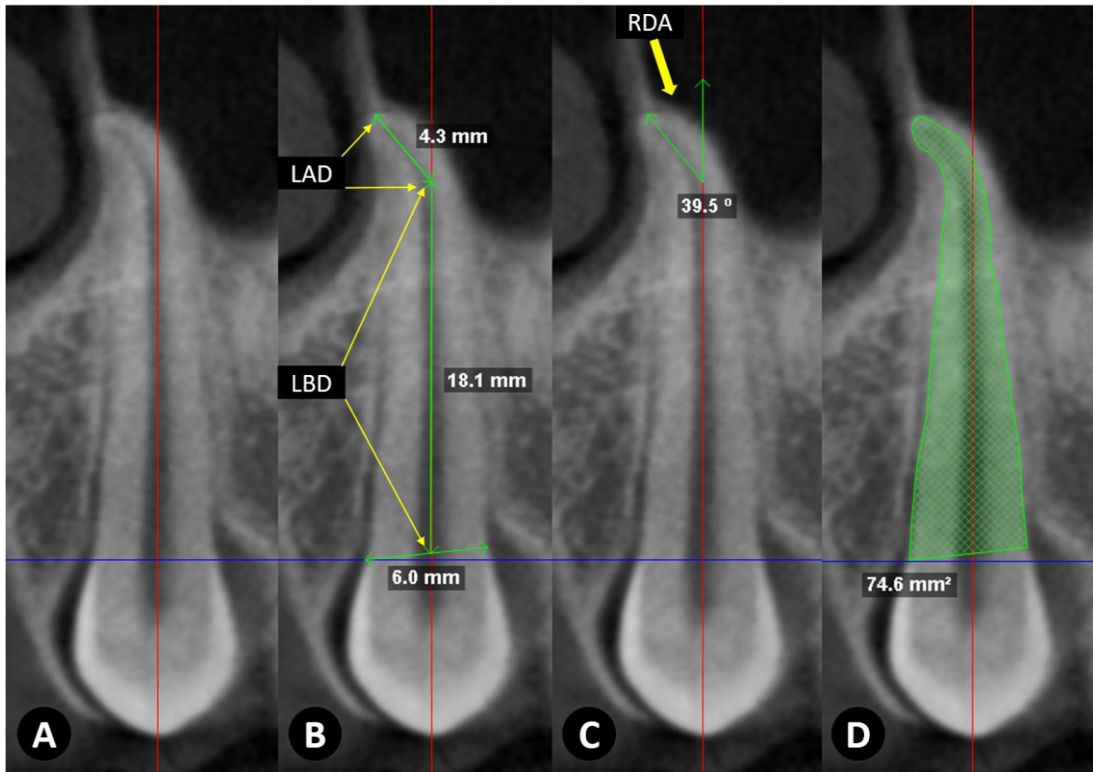


Figure 3. Coronal section measurements. A, main axis location. B, length in mm before dilaceration (LBD), and length in mm after dilaceration (LAD). C, evaluation of the angle of radicular dilaceration, in degrees (RDA). D, evaluation of root area in mm².

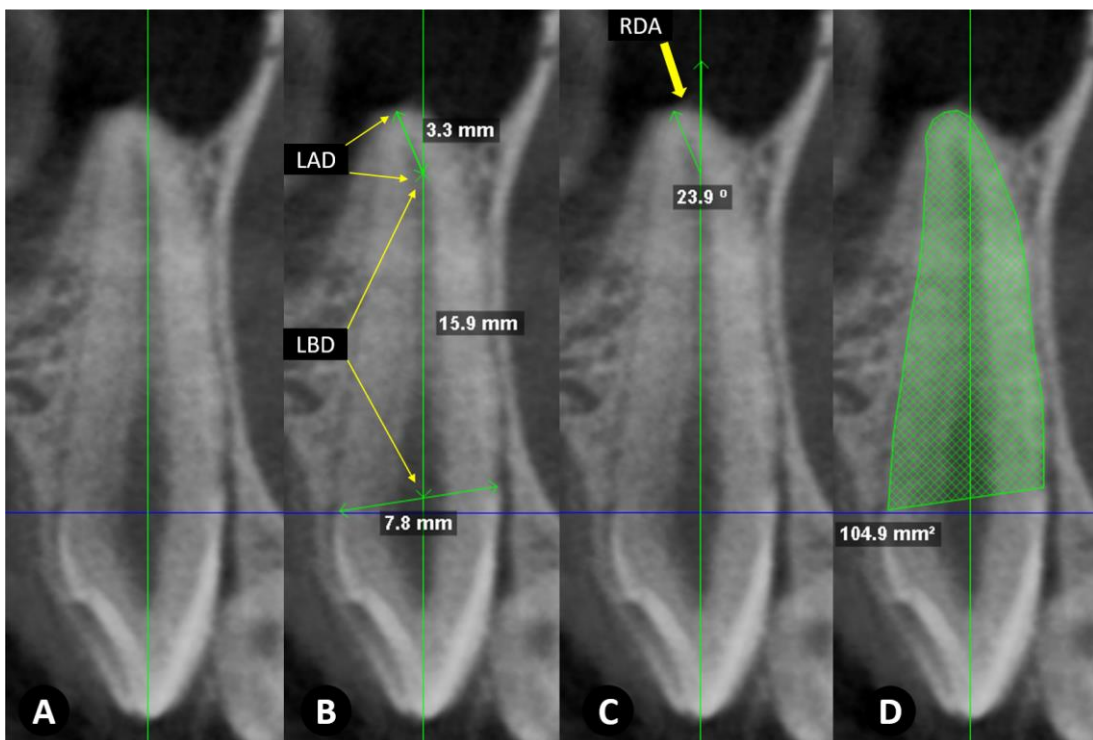


Figure 4. Sagittal section measurements. A, main axis location. B, length evaluation in mm before dilaceration (LBD), and length in mm after dilaceration (LAD). C, evaluation of root dilaceration angle in degrees (RDA). D, evaluation of root area in mm².

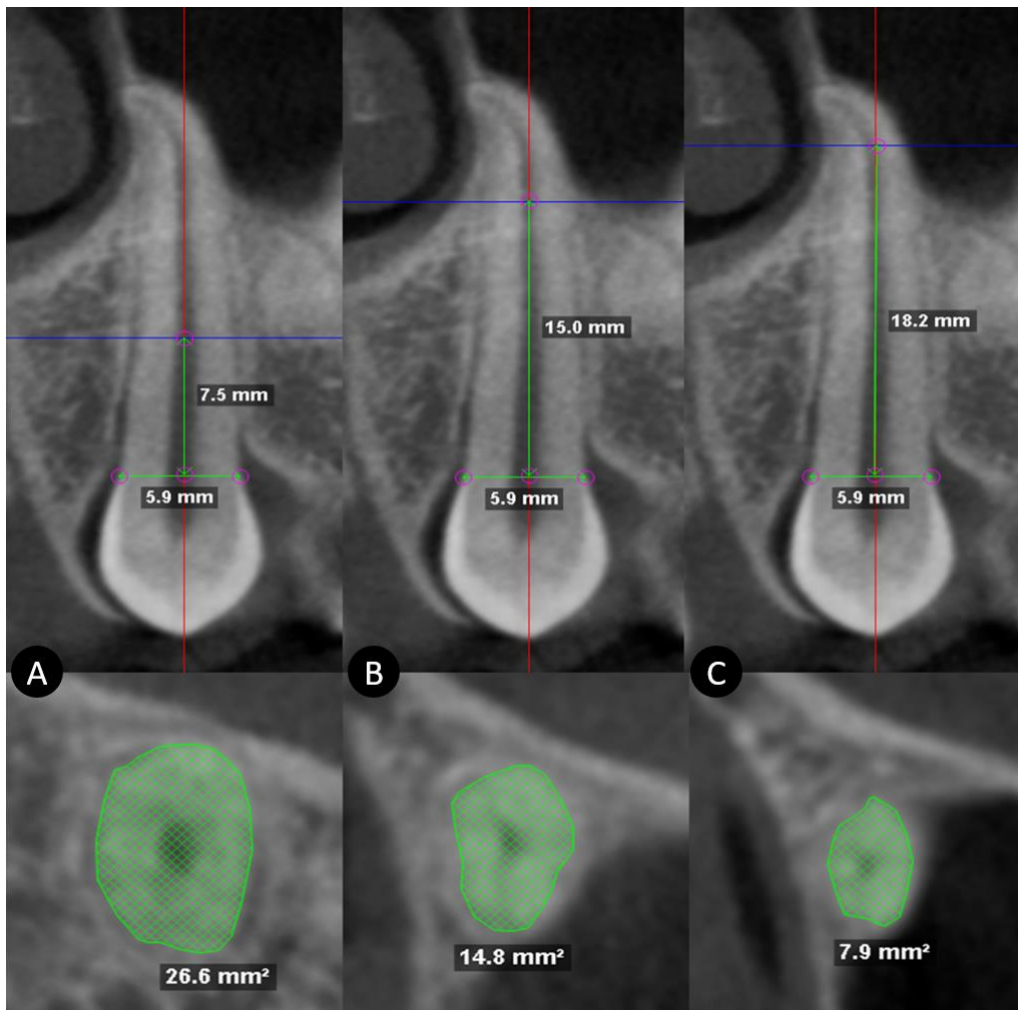


Figure 5. Axial section measurements. A, location of the upper limit of the cervical third and area with and without measure in mm². B, location of the upper limit of the middle third and area with and without measure in mm². C, location of the region of origin of the dilaceration and area with and without measure in mm².

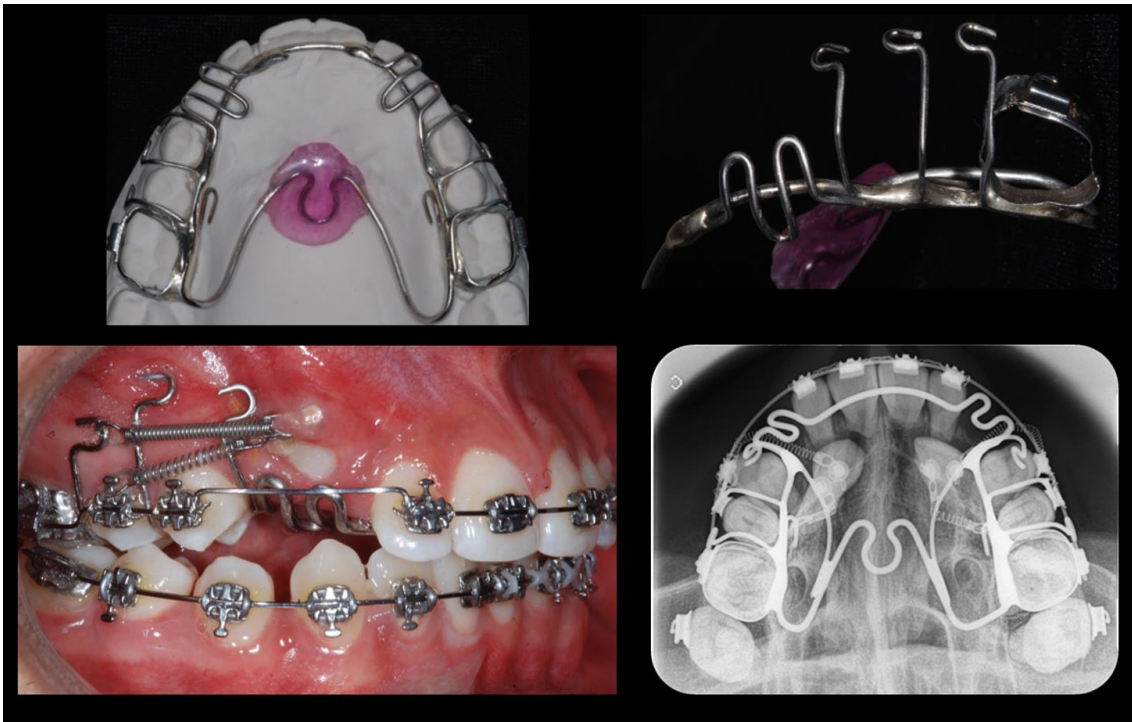

Figure 6. Rigid Anchorage appliance used for MIC orthodontic traction, with hooks and vestibular extensions.

REFERENCES

1. Ericson S, Kurol J. Incisor resorption caused by maxillary cuspids. A radiographic study. *Angle Orthod* 1987;57:332-346.
2. Algerban A, Jacobs R, Fieus S, Willems G. Comparison of two cone beam computed tomographic systems versus panoramic imaging for localization of impacted maxillary canines and detection of root resorption. *Eur J Orthod* 2011;33:93-102.
3. Lund H, Grondahl K, Hansen K, Grondahl HG. Apical root resorption during orthodontic treatment. A prospective study using cone beam CT. *Angle Orthod* 2012;82:480-487.
4. Burden DJ, Mullally BH, Robinson SN. Palatally ectopic canines: closed eruption versus open eruption. *Am J Orthod Dentofacial Orthop* 1999;115:640-644.
5. Parkin NA, Milner RS, Deery C, Tinsley D, Smith AM, Germain P et al. Periodontal health of palatally displaced canines treated with open or closed surgical technique: a

multicenter, randomized controlled trial. *Am J Orthod Dentofacial Orthop* 2013;144:176-184.

6. Schmidt AD, Kokich VG. Periodontal response to early uncovering, autonomous eruption, and orthodontic alignment of palatally impacted maxillary canines. *Am J Orthod Dentofacial Orthop* 2007;131:449-455.

7. Blair GS, Hobson RS, Leggat TG. Posttreatment assessment of surgically exposed and orthodontically aligned impacted maxillary canines. *Am J Orthod Dentofacial Orthop* 1998;113:329-332.

8. Silva AC, Capistrano A, Almeida-Pedrin RR, Cardoso MA, Conti AC, Capelozza LF. Root length and alveolar bone level of impacted canines and adjacent teeth after orthodontic traction: a long-term evaluation. *J Appl Oral Sci* 2017;25:75-81.

9. Kim YH, Vietas JJ. Anteroposterior dysplasia indicator: an adjunct to cephalometric differential diagnosis. *Am J Orthod* 1978;73:619-633.

10. Ericson S, Kuroi J. Early treatment of palatally erupting maxillary canines by extraction of the primary canines. *Eur J Orthod* 1988;10:283-295.

11. Kumar S, Mehrotra P, Bhagchandani J, Singh A, Garg A, Kumar S et al. Localization of impacted canines. *J Clin Diagn Res* 2015;9:ZE11-14.

12. Chaushu S, Kaczor-Urbanowicz K, Zadurska M, Becker A. Predisposing factors for severe incisor root resorption associated with impacted maxillary canines. *Am J Orthod Dentofacial Orthop* 2015;147:52-60.

13. Arriola-Guillén LE R-MG, Rodríguez-Cárdenas YA, Aliaga-Del Castillo A, Díaz-Da Silveira HL. Root resorption of maxillary incisors after traction of unilateral vs bilateral impacted canines with reinforced anchorage *Am J Orthod Dentofacial Orthop* 2018;154:646-657.

14. Hosmer DW, Lemeshow S, Sturdivant RX. *Applied Logistic Regression*. Hoboken, N.J, USA: Jhon Wiley & Sons; 2013.

15. Jaju PP, Jaju SP. Cone-beam computed tomography: Time to move from ALARA to ALADA. *Imaging Sci Dent* 2015;45:263-265.

16. Gelskey DE, Baker CG. The ALARA concept. Population exposures from x rays in dentistry--as low as reasonably achievable? *J Can Dent Assoc* 1984;50:402-403.
17. SEDENTEXCT project consortium. Radiation Protection N°172, Cone Beam CT for Dental and Maxillofacial Radiology: Evidence Based Guidelines 2011; European Commission - The Seventh Framework Programme of the European Atomic Energy Community (Euratom), Assessed October 15, 2012, Luxembourg:pp 1-154.
18. American Academy of O, Maxillofacial R. Clinical recommendations regarding use of cone beam computed tomography in orthodontics. [corrected]. Position statement by the American Academy of Oral and Maxillofacial Radiology. *Oral Surg Oral Med Oral Pathol Oral Radiol* 2013;116:238-257.
19. Hunter K, Brierley D. Pathology of the teeth: an update. *Diagnostic Histopathology* 2017;23:275-283.
20. Manson-Hing LR. X-ray evidence of mechanical trauma. 1959. *Oral Surg Oral Med Oral Pathol Oral Radiol Endod* 2005;100:S67-74.
21. Elhaddaoui R, Benyahia H, Azeroual MF, Zaoui F, Razine R, Bahije L. Resorption of maxillary incisors after orthodontic treatment--clinical study of risk factors. *Int Orthod* 2016;14:48-64.
22. Hettiarachchi PV, Olive RJ, Monsour P. Morphology of palatally impacted canines: A case-controlled cone-beam volumetric tomography study. *Am J Orthod Dentofacial Orthop* 2017;151:357-362.
23. Ruellas AC, Tonello C, Gomes LR, Yatabe MS, Macron L, Lopinto J et al. Common 3-dimensional coordinate system for assessment of directional changes. *Am J Orthod Dentofacial Orthop* 2016;149:645-656.
24. Cevidanes LH, Bailey LJ, Tucker GR, Jr., Styner MA, Mol A, Phillips CL et al. Superimposition of 3D cone-beam CT models of orthognathic surgery patients. *Dentomaxillofac Radiol* 2005;34:369-375.
25. Tai K, Park JH, Mishima K, Hotokezaka H. Using superimposition of 3-dimensional cone-beam computed tomography images with surface-based registration in growing patients. *J Clin Pediatr Dent* 2010;34:361-367.

26. LeCornu M, Cevidanes LH, Zhu H, Wu CD, Larson B, Nguyen T. Three-dimensional treatment outcomes in Class II patients treated with the Herbst appliance: a pilot study. *Am J Orthod Dentofacial Orthop* 2013;144:818-830.
27. Hino CT, Cevidanes LH, Nguyen TT, De Clerck HJ, Franchi L, McNamara JA, Jr. Three-dimensional analysis of maxillary changes associated with facemask and rapid maxillary expansion compared with bone anchored maxillary protraction. *Am J Orthod Dentofacial Orthop* 2013;144:705-714.
28. Kapila S, Conley RS, Harrell WE, Jr. The current status of cone beam computed tomography imaging in orthodontics. *Dentomaxillofac Radiol* 2011;40:24-34.
29. Nada RM, Maal TJ, Breuning KH, Berge SJ, Mostafa YA, Kuijpers-Jagtman AM. Accuracy and reproducibility of voxel based superimposition of cone beam computed tomography models on the anterior cranial base and the zygomatic arches. *PLoS One* 2011;6:e16520.
30. Cevidanes LH, Ruellas AC, Jomier J, Nguyen T, Pieper S, Budin F et al. Incorporating 3-dimensional models in online articles. *Am J Orthod Dentofacial Orthop* 2015;147:S195-204.

Root and Alveolar Bone Changes of First Premolars Adjacent to the
Traction of Buccal vs Palatal Maxillary Impacted Canines: A 3-
Dimensional Evaluation Before and After

Rodríguez-Cárdenas Yalil Augusto, Arriola-Guillén Luis Ernesto, Ruíz-Mora Gustavo Armando,
Aliaga-Del Castillo Aron, Mariana Boessio-Vizzotto, Dias-Da Silveira Heraldo Luis

ROOT AND ALVEOLAR BONE CHANGES IN FIRST PREMOLARS ADJACENT TO THE TRACTION OF BUCCAL VERSUS PALATAL MAXILLARY IMPACTED CANINES

ABSTRACT

Objective: To compare the root and alveolar bone changes in first premolars adjacent to the orthodontic traction of buccal versus palatal maxillary impacted canines (MIC).

Materials and Methods: Before and after traction, cone beam computed tomographies (CBCTs) of 25 subjects with unilateral/bilateral MIC were included in this follow-up and retrospective study. Thirty-six first premolars were divided into 2 groups, buccal (n=15) or palatal (n=21) MIC, and the tomographic images were evaluated before and after orthodontic traction. Root changes in length and area were measured in sagittal, coronal and axial sections. Dimensions of alveolar bone were evaluated in coronal sections. Intergroup and intragroup comparisons were performed using t or Mann-Whitney U tests, depending on normality. Then, multiple linear regressions analyses were used to evaluate the influence of all predictor variables on root and alveolar bone changes ($P<0.05$).

Results: Root and alveolar bone changes produced by orthodontic traction were not significant between groups. Root changes were smaller than 1 mm (length) and 2.51 mm² (area). Alveolar bone changes between buccal and palatal MIC groups ranged from 0.13 mm to 1.69 mm. Furthermore, the multivariate analysis showed no significant influence of the impaction condition (buccal or palatal) on root change. Nevertheless, some different predictor variables influenced the changes of some root lengths and areas.

Conclusions: Orthodontic traction of buccal or palatal MIC produces similar dynamic resorptive and appositional root and alveolar bone changes in the adjacent first premolars.

KEY WORDS: Impacted canine; first premolar; Cone-beam CT

INTRODUCTION

One concern after the traction of a maxillary impacted canine (MIC) is the effect produced on neighboring structures. The most frequently identified sequel is root resorption (RR), which is defined as an irreversible change that is asymptomatic but produces undesirable consequences, and it has been primarily studied in the maxillary incisors.^{1,2} However, few studies have examined the effect of MIC traction in the first premolars, and these reports focused on evaluations of RR in the diagnostic phase. Woloshyn *et al.*³ used conventional radiographs and found a shortening in root length (approximately 1.27 mm) compared to the unaffected contralateral side. Likewise, reports on pretreatment cone beam computed tomographies (CBCTs) primarily focused on the prevalence of RR in neighboring teeth, and it oscillated from 4.48% to 27.1% in first premolars.^{4,5} Yan *et al.*⁵ did not detect significant differences in the RR of the first premolars between buccal versus palatal MIC. The side effects of MIC traction were primarily studied in periodontal soft tissues.^{6,7} However, changes in the alveolar bone of first premolars adjacent to the maxillary impacted canine (PAMIC) and root length and area before and after traction of MIC are not clear.

The PAMIC plays an important role in the process of impaction. The canine in buccal cases may be impacted against the distal surface of the lateral incisor or beyond it. Frequently, its root is located at the apex of the PAMIC and reaches the upper alveolar bone zone of this teeth. Otherwise, the crown in palatal cases may contact the posterior radicular incisor surface. The MIC root is generally close to the PAMIC root, and both are in contact in many cases. Of the teeth adjacent to the MIC, the first premolar has the largest root, and it is a pillar or immediate anchorage element that directs the traction and determines the final position of the canine in many cases.

These aspects suggest that the type of MCI and its traction could influence the degree of RR and the surrounding alveolar bone of the PAMIC. Premolars are responsible for 30% to 40% of the masticatory efficiency.⁸ Therefore, the finding of significant effects on the PAMIC and its alveolar bone after MIC traction would be relevantly clinically important for its long-term prognosis. However, no studies evaluated this issue. Therefore, the present study compared root and alveolar bone changes of PAMIC after the orthodontic traction of buccal versus palatal maxillary impacted canines.

MATERIAL AND METHODS

The Ethics Committee of the [REDACTED], [REDACTED], approved this retrospective and follow-up study (protocol number [REDACTED]). This research evaluated 50 CBCTs (25 before and 25 after traction of MIC) from subjects treated at a private clinic ([REDACTED]). The sample consisted of 36 first premolars adjacent to permanent maxillary impacted canines that underwent traction until the occlusal plane. All MIC were classified into two groups according to location of impaction, i.e., buccal MIC (15) and palatal MIC (21).⁹ This condition was defined on CBCT axial cuts that evaluated the following parameters: position of the MIC crown in relation to a midline drawn between the two cortical layers, and its location in relation to the neighboring lateral incisor or temporary canine.

CBCTs were obtained at pretreatment (T_0) and after orthodontic traction of MIC when the canine reached the occlusal plane (T_1). The following inclusion criteria were used: patients older than 12 years of both sexes with buccal or palatal MIC; unilateral or bilateral impaction; PAMIC erupted, uniradicular or with roots fused into one, with complete apical closure at the beginning of the orthodontic traction; and no loss of permanent teeth. Patients with craniofacial anomalies or syndromes, periapical lesions circumscribed to the MIC at pretreatment, a history of previous orthodontic treatment, history of trauma or supernumerary teeth in the impaction zone were excluded.

The complete clinical records of each patient were registered, including demographic information, study models, intra- and extraoral photographs, panoramic and lateral radiographs and CBCTs.

Skeletal sagittal relationships (ANB¹⁰ and APDI¹¹) were evaluated on lateral radiographs. All characteristics of the MIC (sector, height, α and β angles) and the duration of orthodontic traction were also registered.⁹ The diagnosis of impaction sector was applied on panoramic images synthesized from CBCTs according to Ericson and Kurol's classification.¹² (Fig 1).

All CBCT scans were obtained using a PaX-Uni 3D (Vatech Co., Ltd., Hwaseong, South Korea) with the following parameters: 4.7 mA, 89 KVP and exposure time 15 seconds. Each field of view mode was 8 cm x 8 cm, with a voxel size of 0.2 mm. DICOM images were analyzed with Dolphin-3D software (version 11.8 Dolphin Imaging, Chatsworth, CA, USA) using multiplanar and 3D reconstructions.

Initial root measurements

DICOM images were analyzed using the same software. Coronal, sagittal and axial sections of each PAMIC were obtained. The corresponding section was aligned with the longitudinal tooth axis in the coronal and sagittal planes via locating the largest mesiodistal diameter of the premolar crown perpendicular to the sagittal plane in the coronal section and perpendicular to the coronal plane in the sagittal section (Fig 2). Root lengths were measured in mm from the center of a line that connected the buccal-palatal or mesial-distal enamel-cement junction (in the coronal or sagittal sections, respectively) to the vertex of premolar radicular apex (TL: total length). In the event of presence of any root dilaceration, the TL was measured as the sum of the root length before dilaceration LBD plus root length after dilaceration LAD (Figs 3 and 4).

PAMIC root areas in mm² were evaluated beginning from the buccal enamel-cement junction along the contour of the entire root until the palatal enamel-cement junction in the coronal section, and from the distal enamel-cement junction along the root contour until the mesial enamel-cement junction in the sagittal section. Root areas in axial views were measured at three sectors. Sectors were defined by dividing the total root length of the sagittal section into thirds. The areas at the upper limit of the cervical and middle thirds and the area of the root zone of dilaceration origin were measured in the axial sections. (Fig 5).

Initial measurement of the alveolar bone

The premolar was aligned with the axial axis of each tomographic section. Buccal alveolar thickness (BAT) and palatal alveolar thickness (PAT) were measured from the outermost root surface of each side to the outermost surface of the palatal and buccal cortical bones, respectively. This same section was aligned with the alveolar axial axis (AAA), and a perpendicular line representing the maximum upper alveolar width (MUAW) was drawn. The perpendicular distances from MUAW to the edge of the premolar bone crest were measured on the buccal (buccal bone height, BBH) and palatal sides (palatal bone height, PBH) (Fig 6). Table 1.

Canine traction technique

Traction was performed following a strict orthodontic protocol in all cases using an individualized rigid anchorage device that included an acrylic palatal button soldered onto first

permanent molar bands and multiple palatal-occlusal-vestibular soldered hooks of 0.028" stainless steel wire. (Fig 7). The orthodontic treatment included bracket slots of 0.022" x 0.028" (Synergy RMO, Inc., Rocky Mountain Orthodontics Denver, Colorado, USA). The buccal hooks of the anchor were used to fasten the buckles of NiTi closed coil springs 0.010 "x 0.036", 13 mm long and 150 g force (Dentos Inc. Daegu, Korea) to perform intraosseous transalveolar traction until the MIC reached the occlusal plane. CBCTs (T₁) were taken at this moment using the same technical characteristics of the initial CBCT to control the treatment and supervise the RR of maxillary incisors.^{13,14} All of the necessary procedures to complete the orthodontic treatment were performed.

Final measurement of roots and bone changes

The root lengths and area and alveolar bone variables on this second CBCT (T₁) were measured in the same sections. To measure changes in each PAMIC and the surrounding alveolar bone, the final value (T₁) was subtracted from the initial value (T₀). Positive values of the difference indicated resorptive changes, and negative values indicated appositional changes.

Reliability

Three orthodontists performed the diagnosis of impaction. Interobserver diagnostic and positional agreement was assessed using the Kappa coefficient. Values greater than 0.9 were obtained. The primary evaluator for quantitative variables repeated their measurements after a 30-day interval. The intraclass correlation coefficient (ICC) was used to evaluate intraobserver agreement. All values were greater than 0.9. Random errors were calculated using Dahlberg's formula, and the results were smaller than 1 mm or 1 mm².

Statistical analyses

Statistical analyses were performed using SPSS for Windows (version 19.0; IBM, Armonk, NY, USA). Descriptive statistics of root changes in mm and area in mm² of each canine were calculated for the buccal and palatal impaction groups. Data normality was determined using the Shapiro-Wilk's test. Intergroup comparisons were performed using t or Mann-Whitney U tests, depending on data normality. Multiple linear regression models were used to evaluate the influence of each variable on root and alveolar bone changes, considering all of the variables as predictors (overfit method). Statistical significance was set at $P < 0.05$ for all tests.

RESULTS

The initial characteristics of the sample are summarized in Tables 2 and 3. No significant differences were found in intra- or intergroup comparisons of root changes of PAMIC in coronal, sagittal and axial sections. The changes in millimeters and areas between groups were smaller than 1 mm and 2.51 mm² in both groups (Table 4).

Alveolar bone changes of PAMIC in thickness, width and height were not significantly different in intra- or intergroup comparisons. Changes between buccal and palatal MIC groups ranged from 0.13 mm to 1.69 mm (Table 5).

The linear regression models, considering root changes as outcome variables, did not significantly influence the impaction condition (buccal or palatal) on root changes. However, the ANB angle ($P=0.034$) and duration of traction ($P=0.010$) significantly influenced the total length (TL) change in the sagittal section. APDI ($P=0.008$) significantly influenced the changes in root area in the upper limit of the cervical third in the axial section, and age ($P=0.047$) significantly influenced the root area change in the upper limit of the middle third of the axial section (Table 6).

Similarly, the linear regression models showed no significant influence of the impaction condition (buccal or palatal) on alveolar bone changes. However, buccal alveolar thickness (BAT) was significantly influenced by the height of the MIC ($P=0.037$). Palatal alveolar thickness (PAT) was influenced by the APDI ($P=0.043$). The maximum upper alveolar width (MUAW) was significantly influenced by sex ($P=0.001$), SNA ($P<0.001$), ANB ($P=0.011$), APDI ($P=0.017$), maxillary length ($P<0.001$), duration of traction ($P=0.003$), and impaction sector ($P=0.002$). Buccal bone height (BBH) was significantly influenced by the ANB ($P=0.007$) and β angle ($P=0.033$). Palatal bone height (PBH) was influenced by age ($P=0.001$), maxillary length ($P=0.001$) and impaction sector ($P=0.034$) (Table 7).

DISCUSSION

The present study compared root and alveolar bone changes of the first premolars adjacent to the orthodontic traction of buccal versus palatal MIC and determined which factors affected these changes. The present study used a reproducible method that described PAMIC root morphology in three planes of space and used measurements of length and areas.

This report is the first study to establish these three-dimensional comparisons in the first premolars after orthodontic traction of MIC. The CBCTs in this study were required to evaluate, monitor and control the RR of maxillary incisors after MIC traction. This evaluation is based on the statement by the American Academy of Oral and Maxillofacial Radiology¹⁵, which recommends tomographic supervision according to the complexity of the case and the need for follow up of possible RR and the undesirable effects of orthodontic traction on neighboring structures. The CBCT indicate when 2D images are not sufficient.^{13,14,16}

The sample in the present study was limited exclusively to uniradicular premolars because of the great difficulty in the standardization of a reliable method of measurement in a sample composed of biradicular or three-radicular PAMIC. This aspect influenced the sample size, and it may be the cause of the nonsignificant differences found in this study. Our results do not reflect all of the possible evaluations of root morphology, but it provides an approximation of the tissue response to the traction of MIC on the first premolar and the surrounding alveolar bone.

The intergroup comparisons did not show significant differences for root or alveolar bone changes of PAMIC after MIC traction. Our hypothesis suggests that the PAMIC suffers greater root resorption and alveolar changes depending on the condition of MIC (buccal or palatal) and as a consequence of the traction process. This idea was based on some factors, such as the different bone configurations between these two conditions, different eruption direction between buccal and palatal MIC to a probable friction between roots in the traction process, and the typical morphology of PAMIC. However, differences between groups were not observed. The results in both groups showed primarily resorption, which was not become clinically relevant because it does not exceed 1 mm of length or 2 mm² of area. The presence of negative values in these analyses, primarily root area change in the cervical and middle third, indicates dynamic resorptive and appositional root changes in PAMIC. More studies using a similar methodology should be performed to confirm our results.

Multiple regression analysis showed a significant influence of some skeletal sagittal variables (ANB and APDI) and maxillary size and position (SNA) on the root change of PAMIC caused by the orthodontic traction of the MIC at the level of total length in the sagittal section and the area of the limit of the cervical third in the axial section and on the alveolar bone in PAT, BBH, PBH and mainly in MUAW. Our findings show great sensitivity in this last area because most variables were considered in this study, which were responsible for 88% of

this change. These findings show the changes in maxilla dimensions when a canine is impacted and reflect a great dynamic in this area, which was likely due to the contact between the roots of the MIC and the PAMIC during traction.

The present analysis also showed that a longer the duration of traction produced more RR in the sagittal LT and more bone loss in the MUAW. More RR in an older patient will have the axial area in the middle third of the PAMIC and more bone loss in PBH. More bone loss at the BBH level will be present as the beta angle increases. MUAW and PBH will be more affected by the traction if the MIC is further away from the middle line because the traction will have to traverse a longer distance; The BAT tended to decrease with traction when the MIC was farther from the occlusal plane because its small dimensions focused on the behavior of the buccal cortical. These important findings should be considered in the initial planning and prognosis of buccal or palatal MIC treatment, and the results justify future studies specifically focused on these aspects.

CONCLUSIONS

- Similar dynamic resorptive and appositional root and alveolar bone changes in the PAMIC were observed after traction of buccal and palatal MIC.
- The orthodontic traction of MIC is not a risk for radicular integrity and alveolar bone support of the first premolars adjacent to MIC.

REFERENCES

1. Ericson S, Kurol J. Early treatment of palatally erupting maxillary canines by extraction of the primary canines. *Eur J Orthod.* Nov 1988;10(4):283-295.
2. Brusveen EM, Brudvik P, Boe OE, Mavragani M. Apical root resorption of incisors after orthodontic treatment of impacted maxillary canines: a radiographic study. *Am J Orthod Dentofacial Orthop.* Apr 2012;141(4):427-435.
3. Woloshyn H, Artun J, Kennedy DB, Joondeph DR. Pulpal and periodontal reactions to orthodontic alignment of palatally impacted canines. *Angle Orthod.* 1994;64(4):257-264.
4. Silva AC, Capistrano A, Almeida-Pedrin RR, Cardoso MA, Conti AC, Capelozza LF. Root length and alveolar bone level of impacted canines and adjacent teeth after orthodontic traction: a long-term evaluation. *J Appl Oral Sci.* Jan-Feb 2017;25(1):75-81.
5. Yan B, Sun Z, Fields H, Wang L. Maxillary canine impaction increases root resorption risk of adjacent teeth: a problem of physical proximity. *Am J Orthod Dentofacial Orthop.* Dec 2012;142(6):750-757.
6. Hansson C, Rindler A. Periodontal conditions following surgical and orthodontic treatment of palatally impacted maxillary canines--a follow-up study. *Angle Orthod.* Apr 1998;68(2):167-172.
7. Parkin NA, Milner RS, Deery C, et al. Periodontal health of palatally displaced canines treated with open or closed surgical technique: a multicenter, randomized controlled trial. *Am J Orthod Dentofacial Orthop.* Aug 2013;144(2):176-184.
8. Shao Z, Guo X, Zhang Q, Bronkhorst EM, Zou D, Creugers NHJ. Masticatory efficiency in patients with partially dentate dentitions. *J Dent.* Aug 2018;75:41-47.
9. Kumar S, Mehrotra P, Bhagchandani J, et al. Localization of impacted canines. *J Clin Diagn Res.* Jan 2015;9(1):ZE11-14.
10. Steiner C. Cephalometrics for you and me. *Am J Orthod.* 1953;39:729-755.
11. Kim YH, Vietas JJ. Anteroposterior dysplasia indicator: an adjunct to cephalometric differential diagnosis. *Am J Orthod.* Jun 1978;73(6):619-633.
12. Ericson S, Kurol J. Radiographic examination of ectopically erupting maxillary canines. *Am J Orthod Dentofacial Orthop.* Jun 1987;91(6):483-492.
13. Arriola-Guillen LE, Ruiz-Mora GA, Rodriguez-Cardenas YA, Aliaga-Del Castillo A, Boessio-Vizzotto M, Dias-Da Silveira HL. Influence of impacted maxillary canine orthodontic traction complexity on root resorption of incisors: A retrospective longitudinal study. *Am J Orthod Dentofacial Orthop.* Jan 2019;155(1):28-39.
14. Arriola-Guillen LE, Ruiz-Mora GA, Rodriguez-Cardenas YA, Aliaga-Del Castillo A, Dias-Da Silveira HL. Root resorption of maxillary incisors after traction of unilateral vs bilateral impacted canines with reinforced anchorage. *Am J Orthod Dentofacial Orthop.* Nov 2018;154(5):645-656.
15. American Academy of O, Maxillofacial R. Clinical recommendations regarding use of cone beam computed tomography in orthodontics. [corrected]. Position statement by the American Academy of Oral and Maxillofacial Radiology. *Oral Surg Oral Med Oral Pathol Oral Radiol.* Aug 2013;116(2):238-257.
16. MF D-A, Arriola-Guillen LE, Rodriguez-Cardenas YA, Ruiz-Mora GA. Skeletal and dentoalveolar bilateral dimensions in unilateral palatally impacted canine using cone beam computed tomography. *Progress in orthodontics.* Dec 2017;18(1):7.

FIGURE LEGENDS

Figure 1. Left side: MIC position according to Ericson and Kuroi.² Right side: Evaluation of α and β angles and "d" distance of MIC.

Figure 2. Location of PAMIC. A, coronal; B, sagittal; and C, axial sections.

Figure 3. Coronal section measurements. A, total length (TL). B, length before dilaceration (LBD), length after dilaceration (LAD). C, evaluation of root area.

Figure 4. Sagittal section measurements. A, total length (TL). B, length before dilaceration (LBD), length after dilaceration (LAD). C, evaluation of root area.

Figure 5. Axial section measurements. A, cervical third. B, middle third. C, region of origin of the dilaceration.

Figure 6. Measurements of alveolar bone. A, Location of PAMIC. B, (Middle of TL), buccal alveolar thickness (BAT) and palatal alveolar thickness (PAT). C, location of the alveolar axial axis (AAA), maximum upper alveolar width (MUAW), buccal bone height (BBH) and palatal bone height (BPH).

Figure 7. Rigid Anchorage appliance used for MIC traction.

TABLES

Table 1. Definitions of the measurements used in this study

Variables	Definition
Skeletal sagittal relationship parameters	
ANB	The angle between points A, N and B in degrees.
APDI	The anterior-posterior dysplasia indicator was obtained from the algebraic sum of the angles N-Pg-FH (Facial Plane) plus/minus the angle AB- Facial Plane (is positive when the point B is ahead of point A and is negative when the point A is ahead of point B) and plus/minus the angle FH-PP (palatal plane) (is negative when PP is tilted upward and positive when tilted down).
Sagittal parameters of position and maxillary size	
SNA	The angle between points Sella (S), Nasion (N) and Sub nasal (A) in degrees.
Maxillary length	Distance between the anterior nasal spine (ANS) and posterior nasal spine (PNS).
Root parameters of PAMIC	
LT	Total length: distance from the center of a line that connected the vestibular-palatal or mesial-distal enamel-cement junction until the vertex of premolar radicular apex on the axial axis of the tooth in the coronal and sagittal section. With presence of dilaceration, was measured as the sum of the root length before dilaceration (LBD) and root length after dilaceration (LAD).
Areas	Five areas in mm ² were measured: the coronal, from the buccal enamel-cement junction, along the contour of the entire root until the palatal enamel-cement junction; sagittal, from the distal enamel-cement junction along the root contour until the mesial enamel-cement junction; and three axial root areas: in the upper limit of the cervical and middle third, and in the root zone of dilaceration.
Alveolar bone parameters of PAMIC	
BAT	The buccal alveolar thickness was measured in coronal section, from the outermost root surface to the outermost surface of the buccal cortical bone, on a horizontal lines at the middle of the total length (TL), parallel to another line built from the buccal enamel-cement junction until the palatal enamel-cement junction and perpendicular to the axial axis line.
PAT	The palatal alveolar thickness was measured in coronal section, from the outermost root surface to the outermost surface of the palatal cortical bone, on the same horizontal line in which BAT was measured.
MUAW	The maximum upper alveolar width was drawn and measured in the widest alveolar area, from the outermost point of the buccal and palatal cortex, perpendicular to the alveolar axial axis (AAA).
BBH	The buccal bone height was the perpendicular distance from MUAW to the edge of the premolar bone crest on the buccal side.
PBH	The palatal bone height was the perpendicular distance from MUAW to the edge of the premolar bone crest on the palatal side.

Table 2. Initial characteristics of the sample according to impaction condition of maxillary canine - Qualitative variables

Variable	Categories	Condition		Total	p Chi square
		Buccal	Palatal		
Sex	Male	7	7	14	0.332
	Female	4	7	11	
	Total (subjects)	11	14	25	
Impacted canine location		Unilateral	Bilateral	Total	
		16	9	25	
Impaction sector of maxillary canine		Buccal	Palatal	Total	0.529
	Sector 1	0	2	2	
	Sector 2	3	2	5	
	Sector 3	6	7	13	
	Sector 4	3	8	11	
	Sector 5	3	2	5	
	Total (teeth)	15	21	36	

Table 3. Initial characteristics of the sample according to impaction condition of maxillary canine - Quantitative variables

Measurements	Impaction condition				P	Mean difference	Lower limit CI - 95%	Upper limit CI - 95%
	Buccal = 15		Palatal = 21					
Age*	14.27	3.47	21.05	7.55	0.009	-6.78	-11.78	-1.85
ANB	4.04	2.04	3.37	2.81	0.49	0.66	-1.29	2.63
APDI*	78.91	4.84	84.93	4.97	0.003	-6.02	-9.77	-2.27
SNA*	81.56	4.81	86.79	4.34	0.004	-5.23	-8.65	-1.80
Maxillary length ANS –PNS	48.88	3.21	50.21	4.37	0.383	-1.32	-4.38	1.73
Height of impacted canine*	12.92	3.33	8.70	1.88	<0.001	4.22	2.37	6.07
Angle α of impacted canine	47.85	19.41	43.18	14.00	0.427	4.67	-7.17	16.52
Angle β of impacted canine	49.63	25.29	43.12	13.28	0.34	6.51	-7.10	20.22

*Statistically significant at $P < 0.05$

t test

Table 4. Comparison of root length and area changes (T0-T1) of PAMIC between buccal and palatal MIC groups

CBCT section	Measurements	Impaction condition of maxillary canine				Mean difference	Confidence interval to 95%		p
		Buccal (n=15)		Palatal (n=21)			Lower limit	Upper limit	
		Mean	SD	Mean	SD				
Coronal	Root change in mm (TL)	0.21	1.00	0.81	1.56	-0.60	-1.74	0.53	0.288
	Root area change in mm ²	1.84	8.10	1.35	9.97	0.48	-7.11	8.07	0.897
Sagittal	Root change in mm (LAD)	0.48	0.70	0.57	3.59	-0.08	-3.03	2.86	0.951
	Root area change in mm ²	1.41	2.48	-0.43	4.47	1.84	-1.95	5.64	0.115
	Root change in mm (LBD)	0.32	1.38	0.68	3.53	-0.35	-3.34	2.64	0.806
	Root change in mm (TL)	0.71	0.98	0.80	1.12	-0.09	-0.97	0.79	0.836
Axial	Root area change in cervical third in mm ²	-0.83	2.51	-2.50	3.81	1.75	-1.02	4.52	0.205
	Root area change in middle third in mm ²	-0.80	4.60	-1.16	3.76	0.36	-2.99	4.82	0.825
	Root area change in curve of dilaceration in mm ²	0.80	4.13	-1.87	9.06	2.67	-5.12	10.46	0.478

LAD, length after dilaceration; LBD, length before dilaceration; TL, total length.

Table 5. Comparison of alveolar bone changes (T0-T1) of PAMIC between buccal and palatal MIC groups

CBCT section	Measurements	Impaction condition of maxillary canine				Mean difference	Confidence interval to 95%		p
		Buccal (n=15)		Palatal (n=21)			Lower limit	Upper limit	
		Mean	SD	Mean	SD				
Coronal	Buccal alveolar thickness (BAT) †	0.28	0.98	0.13	0.62	0.15	-0.48	0.79	0.621
	Palatal alveolar thickness (PAT) †	1.06	1.20	1.69	1.27	-0.62	-1.72	0.47	0.250
	Maximum upper alveolar width (MUAW) †	1.50	1.98	1.15	1.57	0.34	-1.10	1.78	0.628
	Buccal bone height (BBH) ‡	0.35	1.75	0.99	2.04	-0.63	-2.28	1.00	0.743
	Palatal bone height (PBH) †	-0.29	1.7	1.05	2.78	-1.33	-3.43	0.75	0.200

† *t* test

‡ Mann-Whitney U test

Table 6. Linear regression model to evaluate the influence of the predictor variables in the root changes of total length at sagittal section and root area changes at sagittal, and cervical and middle third at axial sections of PAMIC

Total length (TL) in section sagittal (in mm)		
Predictor Variables	β	p
(Constant)	2.418	0.657
ANB	-0.461	0.034 *
APDI	-0.033	0.612
Duration traction	0.204	0.010*
Impaction condition	-0.437	0.380
Impaction sector	0.391	0.063
R²		0.479
Root area changes in upper limit of the cervical third of axial section (in mm ²)		
Predictor Variables	β	p
(Constant)	-61,591	0.016
Age	-0.329	0.063
APDI	0.628	0.008*
Maxillary length	0.257	0.279
Impaction condition	-2.796	0.113
Alfa angle	0.043	0.395
R²		0.368
Root area changes in upper limit of the middle third of axial section (in mm ²)		
Predictor Variables	β	p
(Constant)	-59.805	0.164
Age	-0.566	0.047*
APDI	0.610	0.087
Maxillary length	0.420	0.297
Height impacted canine	-0.141	0.722
Alfa angle	-0.030	0.795
Complexity traction ($\alpha > 40^\circ$)	-0.193	0.942
R²		0.367

*Statistically significant at $P < 0.05$

Table 7. Influence of predictor variables with P values smaller than 0.030 in the alveolar bone changes of PAMIC at coronal section (in mm)

Predictor Variables	Buccal alveolar thickness (BAT)	
	β	p
(Constant)	1.920	0.021
Impaction condition	-0.692	0.089
Height impacted canine	-0.120	0.037 *
R²	0.182	
Predictor Variables	Palatal alveolar thickness (PAT)	
	β	p
(Constant)	12.882	0.026
APDI	-0.130	0.043 *
Impacted condition	1.020	0.222
Height impacted canine	0.036	0.774
Beta angle	-0.029	0.146
R²	0.248	
Predictor Variables	Maximum upper alveolar width (MUAW)	
	β	p
(Constant)	7.557	0.660
Sex	-1.776	0.001 *
SNA	0.245	<0.001 *
ANB	-0.555	0.011 *
APDI	-0.155	0.017 *
Maxillary length	-0.261	<0.001 *
Duration of traction	0.245	0.003 *
Impaction sector	-0.613	0.002 *
R²	0.888	
Predictor Variables	Buccal bone height (BBH)	
	β	p
(Constant)	-5.457	0.548
Sex	-1.247	0.288
SNA	0.072	0.470
ANB	-1.074	0.007*
Duration of traction	0.314	0.112
Height impacted canine	-0.469	0.094
Beta angle	0.110	0.033*
R²	0.477	
Predictor Variables	Palatal bone height (PBH)	
	β	p
(Constant)	21.145	<0.001
Age	0.235	0.001 *
Maxillary length	-0.445	0.001 *
Impaction sector	-0.770	0.034 *
R²	0.587	

* Statistically significant at $P < 0.05$.

FIGURE LEGENDS

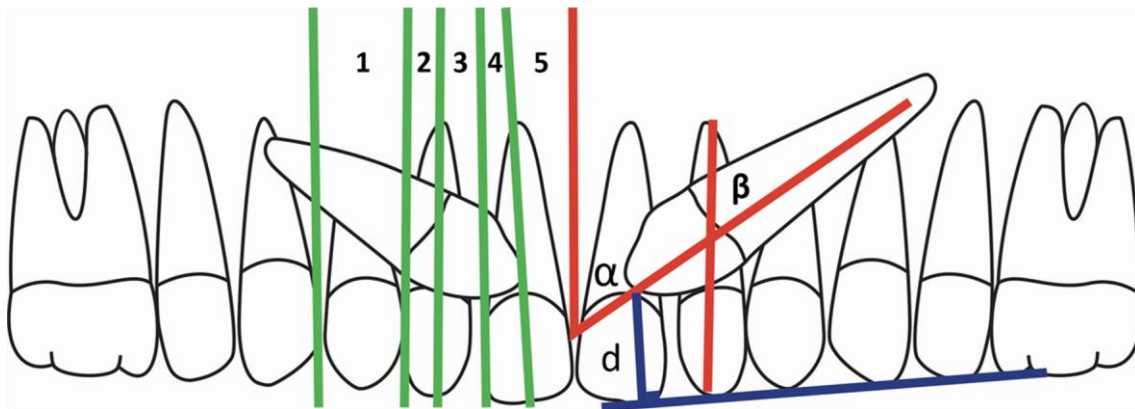


Fig 1. Left side: Anteroposterior assessment of maxillary impacted canines (MIC) position, according to Ericson and Kuroi.² Right side: Evaluation of α , β angles and "d" distance as impacted canine height.

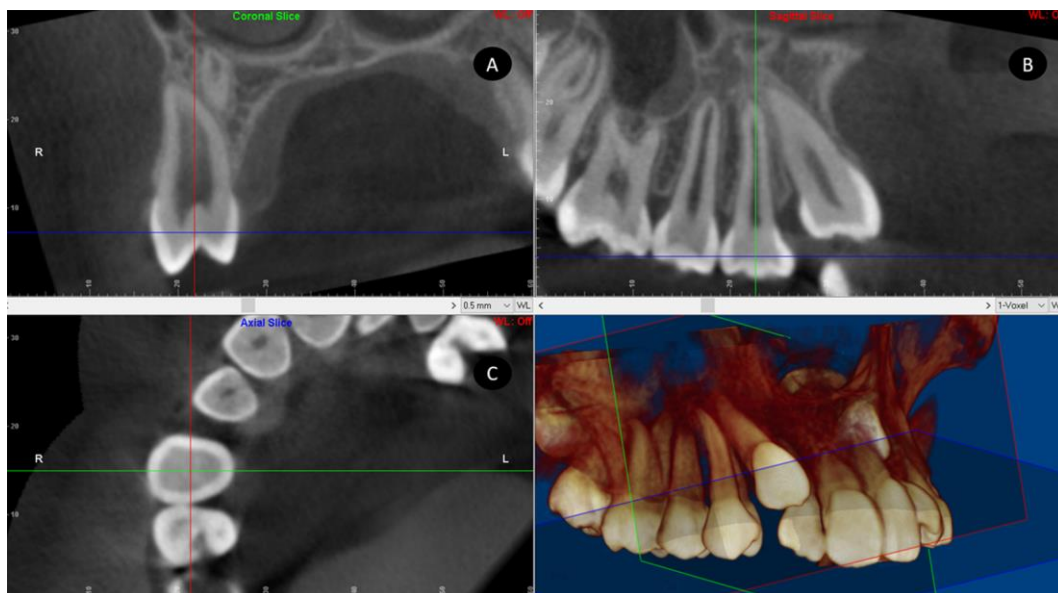


Fig 2. Location of premolar adjacent to maxillary impacted canines (PAMIC) main axis in A, coronal; B, sagittal; and C, axial sections; before the assessment of the variables.

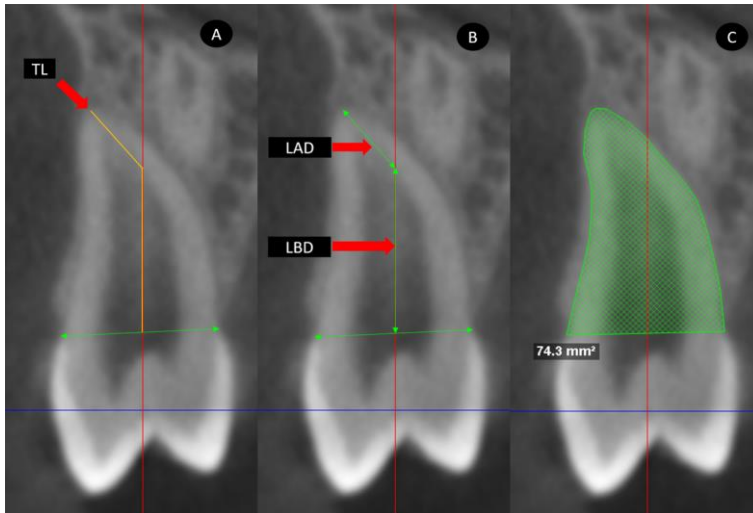


Fig 3. Coronal section measurements. A, main axis location with total length (TL). B, length in mm before dilaceration (LBD), length in mm after dilaceration (LAD). C, evaluation of root area in mm^2 .

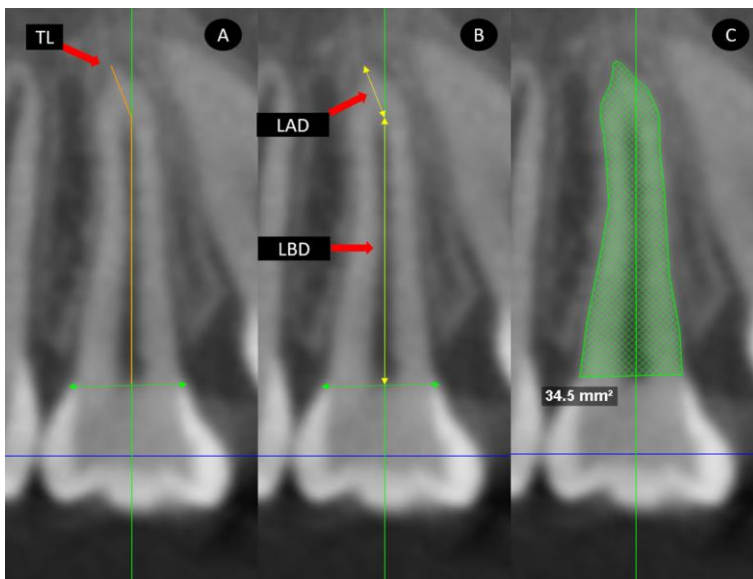


Fig 4. Sagittal section measurements. A, main axis location with total length (TL). B, length evaluation in mm before dilaceration (LBD), length in mm after dilaceration (LAD). C, evaluation of root area in mm^2 .

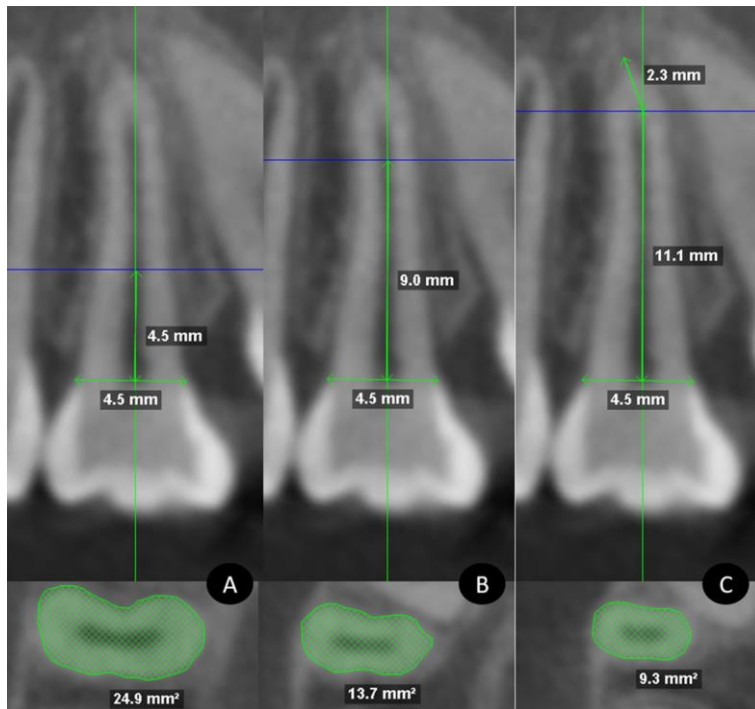


Fig 5. Axial section measurements. A, location of the upper limit of the cervical third and area in mm². B, location of the upper limit of the middle third and area in mm². C, location of the region of origin of the dilaceration and area in mm².

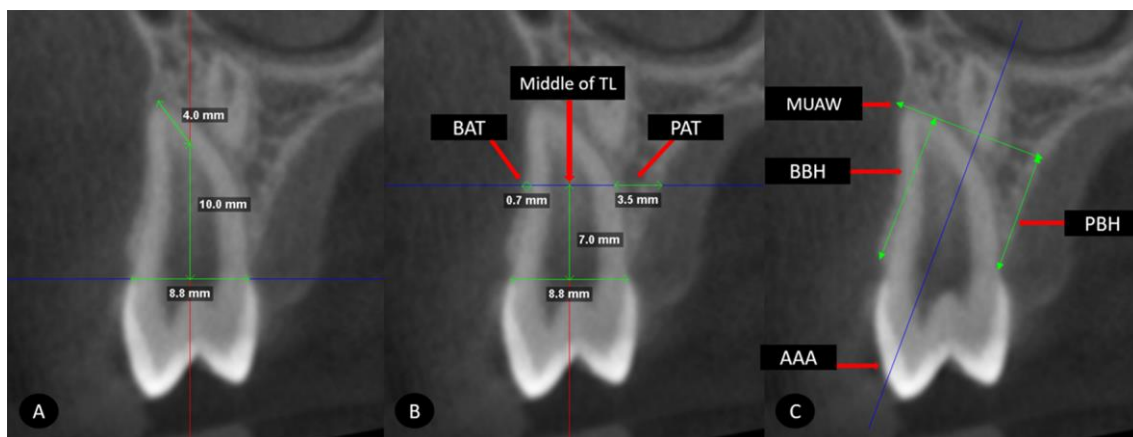


Fig 6. Measurements of alveolar bone. A, horizontal line from the buccal enamel-cement junction until the palatal enamel-cement junction perpendicular to the axial axis of the coronal section after the alignment of premolar. B, horizontal parallel line located in the middle of the total length (Middle of TL), buccal alveolar thickness (BAT) and palatal alveolar thickness (PAT). C, location of the alveolar axial axis (AAA), maximum upper alveolar width (MUAW), buccal bone height (BBH) and palatal bone height (BPH).

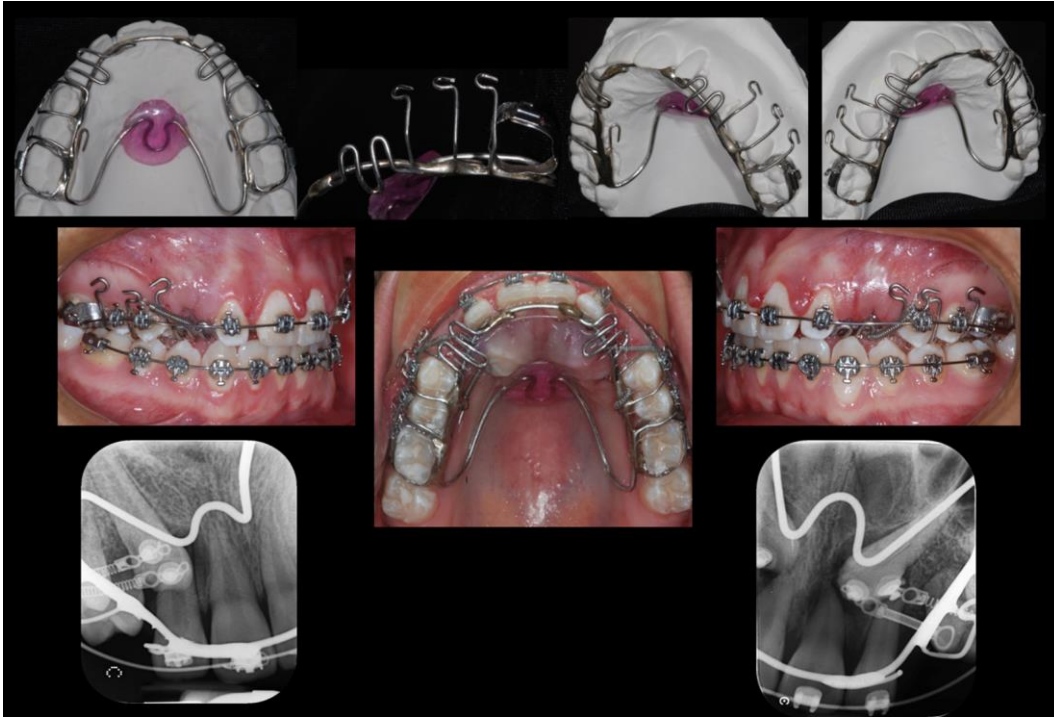


Fig 7. Rigid Anchorage appliance used for maxillary impacted canines (MIC) orthodontic traction with hooks and vestibular extensions for activation of NiTi coil springs.

Considerações Finais

Considerações Finais

A tração dos caninos superiores impactados representa um desafio biomecânico de tratamento. Além de exigir um planejamento cuidadoso na vetorização sequencial das forças ortodônticas necessárias para a sua desimpactação, a seleção correta dos acessórios e dispositivos para aplicá-los é crucial. Neste contexto, as molas helicoidais de NiTi são a melhor opção devido à possibilidade de aplicação de forças contínuas sem decaimento [18]. A evidência sugere que no processo de ativação e desativação, a carga varia de uma força fisiológica de 50 gramas a até 474 gramas [19].

A identificação precisa dos efeitos produzidos por esta tensão e a sua relação com o grau de complexidade do CSI continua a ser um assunto muito estudado, principalmente em relação aos incisivos, mas não em relação a raiz do próprio canino, nem sobre pré-molares e osso alveolar adjacentes. O presente trabalho permite fazer conclusões sobre esses aspectos. A tração ortodôntica de um CSI produz alterações radiculares semelhantes entre os casos de impacção vestibular e palatina, exceto pela mudança na área axial da raiz no limite superior ao terço cervical, que apresentaram maiores alterações de aposição no grupo palatino. Esta alteração poderia ser uma hiper cementose, como resposta resultante de um movimento ortodôntico sinuoso e longo, em comparação com o movimento ortodôntico de um CSI vestibular. No entanto, a elucidação precisa desse aspecto requer estudos futuros para avaliar aspectos histológicos e de elementos finitos. A tração ortodôntica de uma CSI por vestibular ou palatino produz alterações de reabsorção e aposição radiculares e alveolares similares na região dos primeiros pré-molares superiores.

Finalmente, este estudo mostrou que a complexidade da impactação do Canino Superior não tem influência nas alterações dimensionais radiculares produzidas pela tração, em sua raiz, na raiz do pré-molar e no osso alveolar adjacentes. A tração ortodôntica do canino superior impactado, com a metodologia empregada mostrou-se um procedimento seguro e não provocou aumento de reabsorção da raiz do CSI, do pré-molar e osso alveolar adjacentes.

Referências

1. Brown LH, Berkman S, Cohen D, Kaplan AL, Rosenberg M. A radiological study of the frequency and distribution of impacted teeth. *J Dent Assoc S Afr* 1982;37:627-630.
2. Bishara SE. Impacted maxillary canines: a review. *Am J Orthod Dentofacial Orthop* 1992;101:159-171.
3. Grover PS, Lorton L. The incidence of unerupted permanent teeth and related clinical cases. *Oral Surg Oral Med Oral Pathol* 1985;59:420-425.
4. Baccetti T. A controlled study of associated dental anomalies. *Angle Orthod* 1998;68:267-274.
5. Peck S, Peck L, Kataja M. The palatally displaced canine as a dental anomaly of genetic origin. *Angle Orthod* 1994;64:249-256.
6. Becker A, Smith P, Behar R. The incidence of anomalous maxillary lateral incisors in relation to palatally-displaced cuspids. *Angle Orthod* 1981;51:24-29.
7. Fournier A, Turcotte JY, Bernard C. Orthodontic considerations in the treatment of maxillary impacted canines. *Am J Orthod* 1982;81:236-239.
8. Jacoby H. The etiology of maxillary canine impactions. *Am J Orthod* 1983;84:125-132.
9. Ericson S, Kurol J. Radiographic assessment of maxillary canine eruption in children with clinical signs of eruption disturbance. *Eur J Orthod* 1986;8:133-140.
10. Ericson S, Kurol J. Radiographic examination of ectopically erupting maxillary canines. *Am J Orthod Dentofacial Orthop* 1987;91:483-492.
11. Becker A. In defense of the guidance theory of palatal canine displacement. *Angle Orthod* 1995;65:95-98.
12. Hettiarachchi PV, Olive RJ, Monsour P. Morphology of palatally impacted canines: A case-controlled cone-beam volumetric tomography study. *Am J Orthod Dentofacial Orthop* 2017;151:357-362.

13. Silva AC, Capistrano A, Almeida-Pedrin RR, Cardoso MA, Conti AC, Capelozza LF. Root length and alveolar bone level of impacted canines and adjacent teeth after orthodontic traction: a long-term evaluation. *J Appl Oral Sci* 2017;25:75-81.
14. Woloshyn H, Artun J, Kennedy DB, Joondeph DR. Pulpal and periodontal reactions to orthodontic alignment of palatally impacted canines. *Angle Orthod* 1994;64:257-264.
15. Yan B, Sun Z, Fields H, Wang L. Maxillary canine impaction increases root resorption risk of adjacent teeth: a problem of physical proximity. *Am J Orthod Dentofacial Orthop* 2012;142:750-757.
16. Cao D, Zhu L, Chen Y, Xie L, Yan B, Sun Z. Buccally impacted maxillary canines increase the likelihood of root separation in adjacent first premolars. *Oral Dis* 2017;23:36-41.
17. Stewart JA, Heo G, Glover KE, Williamson PC, Lam EW, Major PW. Factors that relate to treatment duration for patients with palatally impacted maxillary canines. *Am J Orthod Dentofacial Orthop* 2001;119:216-225.
18. Dixon V, Read MJ, O'Brien KD, Worthington HV, Mandall NA. A randomized clinical trial to compare three methods of orthodontic space closure. *J Orthod* 2002;29(1):31-6.
19. Maganzini AL, Wong AM, Ahmed MK. Forces of various nickel titanium closed coil springs. *Angle Orthod* 2010;80(1):182-7.

Anexo 1

Aprovação no Comissão de Pesquisa – FO-UFRGS

https://www1.ufrgs.br/PortalServidor/Pesquisa/Pesquisador/forms/form_index.php

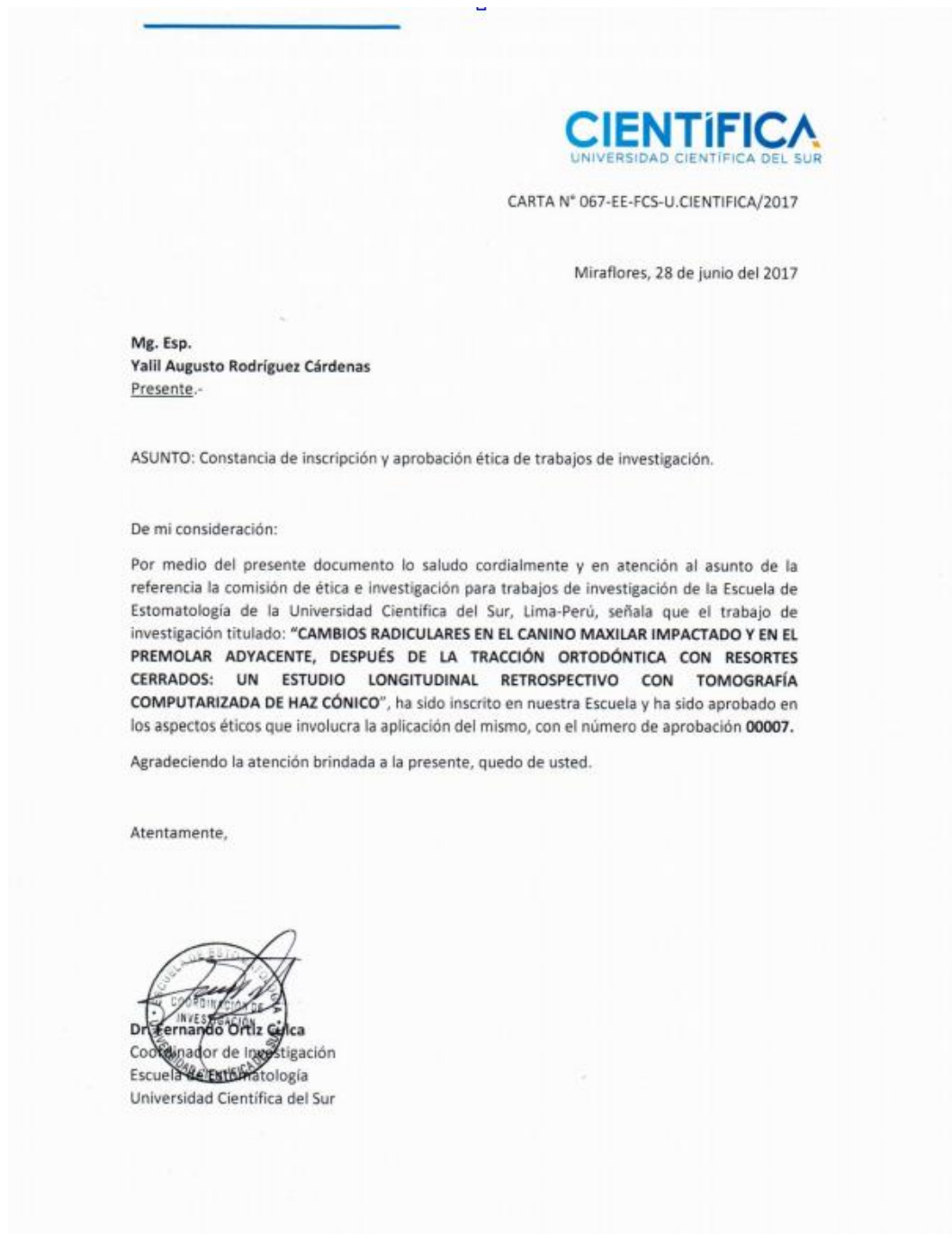Sistema Pesquisa - Pesquisador: Heraldo Luis Dias Da Silveira

Dados Gerais:

Projeto Nº:	33768	Título:	MUDANÇAS RADICULARES EM CANINOS SUPERIORES IMPACTADOS E PREMOLARES ADJACENTES, APOS A TRACAO ORTODONTICA COM MOLAS NI-TI, UM ESTUDO LONGITUDINAL RETROSPECTIVO COM EXAMES DE TCFC
Área de conhecimento:	Radiologia Odontológica	Início:	16/08/2017 Previsão de conclusão: 17/07/2021
Situação:	Projeto em Andamento	Projeto da linha de pesquisa:	DIAGNÓSTICO DE AFECÇÕES BUCO-FACIAIS
Origem:	Faculdade de Odontologia Programa de Pós-Graduação em Odontologia		
Local de Realização:	não informado		
Objetivo:	Introducción: Históricamente los caninos maxilares impactados (CMI) han sido un importante motivo de consulta ortodóntica por el alto impacto estético y funcional que representan en un individuo. A pesar de ser un tema ampliamente estudiado, son escasos los reportes que se encuentran en la literatura sobre su morfología radicular y la del premolar adyacente (primer premolar), y el impacto de su tracción sobre ellos. Para aprovechar las ventajas que da el uso de la TCHC, el objetivo del presente estudio será: 1. Comparar los cambios radiculares (en mm y mm2) entre		
Palavras Chave:	CANINO MAXILAR IMPACTADO, TCFC		
Equipe UFRGS:	Nome: HERALDO LUIS DIAS DA SILVEIRA Coordenador - Início: 16/08/2017 Previsão de término: 17/07/2021 Nome: Yalli Augusto Rodriguez Cárdenas Outra: Aluno de Doutorado - Início: 16/08/2017 Previsão de término: 17/07/2021		
Avaliações:	Comissão de Pesquisa de Odontologia - Aprovado em 25/08/2017 Clique aqui para visualizar o parecer		

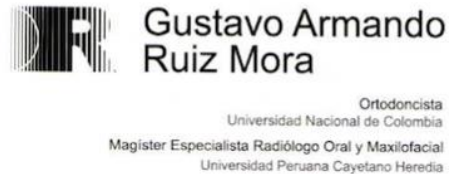Anexo 2

Aprovação no Comissão de Pesquisa e Ética – FO-UCSUR



Anexo 3

Termo de compromiso para uso de datos



Porto Alegre, July 19 2007

I, **GUSTAVO ARMANDO RUIZ MORA** with ID. # PE130267, authorize and consent to **YALIL AUGUSTO RODRIGUEZ CARDENAS**, with ID # AS 483636 to use tomographic records of my database related to treatment of maxillary impacted canines.

These files must be kept confidential, and should only be used by the researcher only and exclusively to execute the project namely:

"ROOT CHANGES IN MAXILLARY IMPACTED CANINE AND ADJACENT PREMOLAR AND ITS ALVEOLAR BONE, AFTER THE ORTHODONTIC TRACTION WITH COIL SPRINGS: A RETROSPECTIVE LONGITUDINAL STUDY WITH CONE BEAM COMPUTED TOMOGRAPHY (CBCT)."

All information may be used strictly of form anonymous.



Anexo 4

Autorização para o uso de informação tomografica

TERMINO DE COMPROMISO PARA USO DE DATOS

Title of research project

“ROOT CHANGES IN THE IMPACTED MAXILLARY CANINE AND ADJACENT PREMOLAR, AFTER THE ORTHODONTIC TRACTION WITH COIL SPRINGS: A RETROSPECTIVE LONGITUDINAL STUDY WITH CONE BEAM COMPUTED TOMOGRAPHY (CBCT)

The researchers of the present project commit themselves to preserve the privacy of patients whose data will be collected in medical records and databases of Dr. Gustavo Ruíz's Clinic, (Bogotá, Colombia). They also agree that this information will be used solely and exclusively for the execution of this project. The information may only be disclosed anonymously.

Porto Alegre, July 1, 2015.

Principal Author	Signature
Yalil Augusto Rodríguez Cárdenas	