

## Late Hyaluronidase Injection in Local Anesthesia: Morphofunctional Evaluation in Rat Sciatic Nerve Block

### Abstract

**Introduction:** Despite the enhancing effects of hyaluronidase (HYAL) over duration of anesthesia, this enzyme could cause adverse effects when injected concomitantly with local anesthetics in dental blocks. **Objective:** This study aimed to assess the tissue alterations caused by a local anesthetic protocol consisting of a late HYAL injection and confirm its functional effectiveness. **Materials and Methods:** The protocol efficacy was proved by evaluating sensory and motor functions in rats. The sciatic nerve was blocked with 2% lidocaine (LID) with epinephrine ( $n = 25$ ). Thirty minutes later, 75 TRU/ml HYAL was injected into the same site (experimental group, LID/HYAL). One week later, this protocol was repeated in the contralateral hindlimb, injecting only HYAL's vehicle (control group, LID/vehicle [LID/V]). To observe the integrity of the local tissues, histological specimens were obtained 1, 24, 48, and 72 h after treatment with LID/HYAL or LID/V ( $n = 16$  each) and stained with hematoxylin/eosin and picosirius red. **Results:** Local inflammation was similar in both groups. The integrity of the nerve fibers was preserved, in spite of some inflammation-associated injuries in the surrounding tissues. The reversible tissue disorganization caused by HYAL, probably facilitated the diffusion of the residual anesthetic to the nerve, resulting in a prolonged anesthetic effect ( $P < 0.05$ ). **Conclusions:** No irreversible morphological alterations are caused by the administration of HYAL prior the end of the LID-induced block. Moreover, this protocol prolongs LID's anesthetic effect.

**Keywords:** Anesthesia adjuvants, anesthetics, hyaluronic acid, hyaluronoglucosaminidase

### Introduction

Among the few long-acting local anesthetics, none can be safely used in certain systemically compromised individuals, such as cardiac patients.<sup>[1,2]</sup> As an alternative to these long-acting drugs, several anesthetic adjuvants, such as the enzyme hyaluronidase (HYAL), have been developed. In ophthalmology, the concomitant use of local anesthetics with HYAL has shown advantages such as improving the anesthetic effect in retrobulbar and peribulbar blocks,<sup>[3,4]</sup> reducing the onset time,<sup>[3,5]</sup> and protecting the periocular muscles against bupivacaine-induced injury.<sup>[4]</sup> Its mechanism of action is focused on the hyaluronan cleavage. HYAL reversibly cleaves the  $\beta$ -1,4 glycosidic bond of hyaluronan, a polysaccharide found in the extracellular matrix of connective tissues,<sup>[6]</sup> decreasing the viscosity of this matrix ("spreading factor"), and facilitating the diffusion of injected substances through the tissues.<sup>[6,7]</sup>

This is an open access journal, and articles are distributed under the terms of the Creative Commons Attribution-NonCommercial-ShareAlike 4.0 License, which allows others to remix, tweak, and build upon the work non-commercially, as long as appropriate credit is given and the new creations are licensed under the identical terms.

For reprints contact: [reprints@medknow.com](mailto:reprints@medknow.com)

The coadministration of local anesthetics with HYAL has not been so useful in other peripheral blocks – such as inferior alveolar nerve block – in which it showed potential tissue-damaging effect, clinically observed as severe local pain and trismus.<sup>[8]</sup> A different protocol consisting of the late administration of HYAL, 30 min after the anesthetic onset in inferior alveolar nerve block, was effective in prolonging anesthesia;<sup>[9,10]</sup> however, the histological effect of this protocol or those in ophthalmology using HYAL has never been assessed before. We hypothesize that by injecting HYAL at the moment when there would probably be a small amount of local anesthetic in the tissue, the drug's excessive dispersion and the related undesirable effects, brought by the concomitant administration, might be prevented.

The aim of this study was to identify the morphological alterations caused by a single dose of 75 TRU/ml HYAL injected before the end of the anesthetic effect, after evaluating whether this protocol was able

**How to cite this article:** Tempestini-Horliana AC, Lamers ML, Yonamine M, Aulestia-Viera PV, Santos MF, Borsatti MA. Late hyaluronidase injection in local anesthesia: Morphofunctional evaluation in rat sciatic nerve block. *Indian J Dent Res* 2019;30:692-6.

Anna Carolina Ratto Tempestini-Horliana, Marcelo Lazzaron Lamers<sup>1</sup>, Maurício Yonamine<sup>2</sup>, Patricia Verónica Aulestia-Viera<sup>3</sup>, Marinilce Fagundes Dos Santos<sup>4</sup>, Maria Aparecida Borsatti<sup>3</sup>

Biophotonics Program, School of Dentistry, University Nove De Julho, São Paulo, <sup>1</sup>Department of Morphological Sciences, Federal University of Rio Grande Do Sul, Institute of Health Science, Porto Alegre, <sup>2</sup>Department of Clinical and Toxicological Analysis, Faculty of Pharmaceutics Sciences, University of São Paulo, Cidade Universitária, São Paulo, <sup>3</sup>Department of Stomatology, School of Dentistry, University of São Paulo, Cidade Universitária, São Paulo, <sup>4</sup>Department of Cell and Developmental Biology, University of São Paulo, Institute of Biomedical Sciences, Cidade Universitária, São Paulo, Brazil

### Address for correspondence:

Dr. Maria Aparecida Borsatti, Av. Prof. Lineu Prestes 2227, Cidade Universitária, São Paulo, Brazil. E-mail: [maborsat@usp.br](mailto:maborsat@usp.br)

Received : 22-11-2016  
Revised : 26-05-2017  
Accepted : 15-09-2017  
Published : 18-12-2019

### Access this article online

Website: [www.ijdr.in](http://www.ijdr.in)

DOI: 10.4103/ijdr.IJDR\_745\_16

### Quick Response Code:



to extend the duration of sensory and motor block in rat sciatic nerve.

## Materials and Methods

This study was approved by the local Ethics Committee for Animal Research (026/2013). Fifty-seven 12-week-old male rats (*Rattus norvegicus*, albinus, Wistar), weighing 250–350 g, were used. The animals were housed in a quiet room at 22°C, on a 12-h light/dark cycle, with food and water provided *ad libitum*. The rats were acquainted with the experimental conditions twice in the week before to avoid stress.

### Nociceptive and motor block evaluation

Before the morphological analysis, the anesthetic efficacy of this protocol was evaluated. Twenty-five rats were anesthetized with 0.14 ml of 2% lidocaine (LID) hydrochloride with 1:100,000 epinephrine (DFL, Rio de Janeiro, Brazil) for sciatic nerve block. All the injections were performed by the same operator in the periarticular region of the hindlimb (popliteal space) using the Truant technique.<sup>[11]</sup> In the 30<sup>th</sup> minute after the beginning of the anesthetic effect, 0.18 ml of 75 TRU/ml HYAL (Apsen Farmacêutica, São Paulo, Brazil) was injected into the same site (experimental side: LID/HYAL). The injection moment was determined in a preliminary experiment ( $n = 4$ ) where the average (mean  $\pm$  standard deviation) duration of action of LID with epinephrine was found to be  $40 \pm 9$  min. One week later, the LID injection was repeated in the contralateral hindlimb and 30 min later, 0.18 ml of the HYAL's vehicle was injected (control side: LID/vehicle [LID/V]). Each hindlimb was used as an experimental unit.

The mechanical-nociceptive response was evaluated by applying painful pressure stimuli with an analgesy-meter (Analgesy-meter<sup>TM</sup>, Ugo Basile, Monvalle, Italy) every 10 min. A linearly increasing force (16 g/s) was applied in the dorsal part of the hind paw, between the third and fourth metatarsals. When there was paw withdrawal reflex or vocalization, the pressure was interrupted. The duration of the nociceptive block corresponded to the period when the paw withdrawal reflex was absent with score 25 (rat supports 250 g pressure, the cutoff to avoid injury) and no pain. The painful stimulus was stopped with the return of pain.

To evaluate the motor block, the animals were raised by the dorsal part, and their hindlimbs were lifted off in a supporting surface (platform balance, Ohaus Lopro, Fisher Scientific, Bridgewater, NJ). Under these circumstances, the tibiotarsal joint normally extends to reach the floor (extensor postural thrust), but this reflex is lost under anesthesia. Complete block of motor function was defined as the complete absence of extension of the tibiotarsal joint and its duration comprised the period from the beginning of complete absence of extension of this joint to the recovery

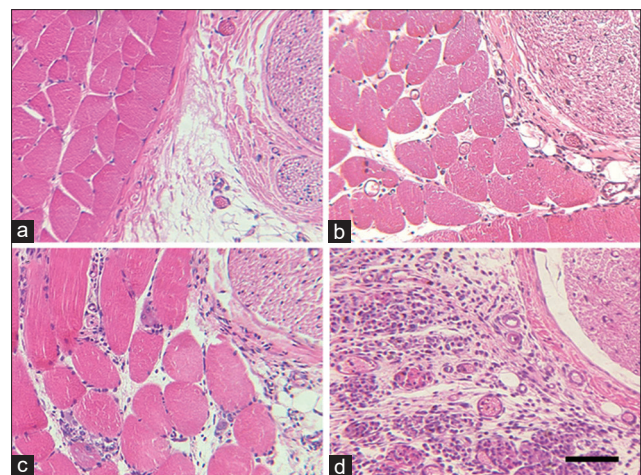
of movement.<sup>[12]</sup> All tests were performed every 10 minute, starting 10 minute before the injection of local anesthesia and continuing until complete functional recovery.

### Morphological analysis

The animals were randomly assigned into two groups ( $n = 16$  each): LID/V and LID/HYAL. The LID/V group was treated with 1.4 ml LID with epinephrine and 0.18 ml HYAL's vehicle (sterile distilled water, benzalkonium chloride, mannitol, and sodium chloride). The LID/HYAL group was treated with 1.4 ml LID with epinephrine and 0.18 ml HYAL (75 TRU/ml). In both groups, the injection for sciatic nerve block was performed by the Truant technique and the second injection occurred 30 minute after the nerve block began.

After 1, 24, 48, or 72 h from the last injection ( $n = 4$ /time/group), the animals were sacrificed by an anesthetic overdose of ketamine and xylazine (CEVA, Paulinia, Brazil). The sciatic nerve and surrounding tissues were dissected and fixed in methacarn solution (60% methanol, 30% chloroform, and 10% acetic acid) at 4°C for 3 h, processed, and embedded in paraffin. Transversal 5  $\mu$ m-thick sections were stained with hematoxylin and eosin for morphological analysis and with picosirius red for fibrillar collagen observation. Samples were observed under a microscope (Leitz Aristoplan, Wetzlar, Germany) with polarized light for picosirius red staining. Two researchers independently and blindly evaluated the micrographs.

Images were captured with a CCD 72S (MTI) camera and processed with Adobe Photoshop 7.0. The integrity of the sciatic nerve fibers and the local connective tissue was analyzed using a score scale (set before the experiment began) from 0 to 3 [Figure 1], according to the degree of inflammation and tissue injury: (a) No sign of inflammation (score 0), (b) Minor infiltration of inflammatory cells



**Figure 1: Score scale for morphological alterations: (a) No sign of inflammation, (b) Minor infiltration of inflammatory cells, (c) Moderate infiltration of inflammatory cells and degeneration of a few muscle fibers, and (d) Major infiltration of inflammatory cells and significant muscle fiber degeneration (H and E stain)**

(score 1), (c) Moderate infiltration of inflammatory cells and degeneration of a few muscle fibers (score 2), and (d) Major infiltration of inflammatory cells and significant muscle fiber degeneration (score 3). The reversibility of the inflammatory process was considered with reduction in the score.

### Statistical analysis

Normal distribution and equality of variance were evaluated with Kolmogorov–Smirnov and Bartlett’s tests. Sensory block duration was analyzed by paired *t*-test and motor block duration was analyzed by Wilcoxon test. The morphological results were analyzed with Kruskal–Wallis and Dunn’s tests with an alpha level of 0.05 (GraphPad Prism 7.0; San Diego, CA, USA).

## Results

### Nociceptive and motor block evaluation

Table 1 shows the results of sensory and motor block duration. Compared with the treatment with vehicle, HYAL significantly ( $P < 0.0001$ ) increased the sensory block duration by almost 60%. The LID/HYAL complete motor block duration was also prolonged ( $P = 0.0011$ ) when compared with LID/V. In group LID/HYAL, the complete sensory recovery (return to baseline) occurred in approximately 110 min. All animals showed full recovery from the sciatic nerve block, with no signs of local or systemic toxicity over 24 h.

### Morphological analysis

The morphological results are presented in Figure 2 and Table 2. LID/V showed inflammatory cells after 24 h (median score: 1.5) and abundant macrophages, plasma cells, neutrophils, and lymphocytes after 48 h. This reaction slightly declined over 72 h. LID/HYAL showed a burst of inflammatory cells after 24 h and moderate tissue injury (median score: 2). The inflammation was increased after 48 h (median score: 3), with copious neutrophils,

extravasation of red blood cells into the connective tissue, and disorganization of the fibrous extracellular matrix, suggesting disarrangement of the collagen fibers. Numerous macrophages were largely associated with degenerating/regenerating muscle fibers. There was a decline in the inflammatory process over 72h (median score: 2). No significant differences were observed between both groups at any timepoint [Table 2].

Interestingly, the integrity of the nerve fibers was always preserved, even in the presence of some degree of inflammation-associated injury in the surrounding tissues. Although there was some disorganization of the connective tissue, especially of collagen fiber bundles, the collagen

**Table 1: Sensory and motor block duration**

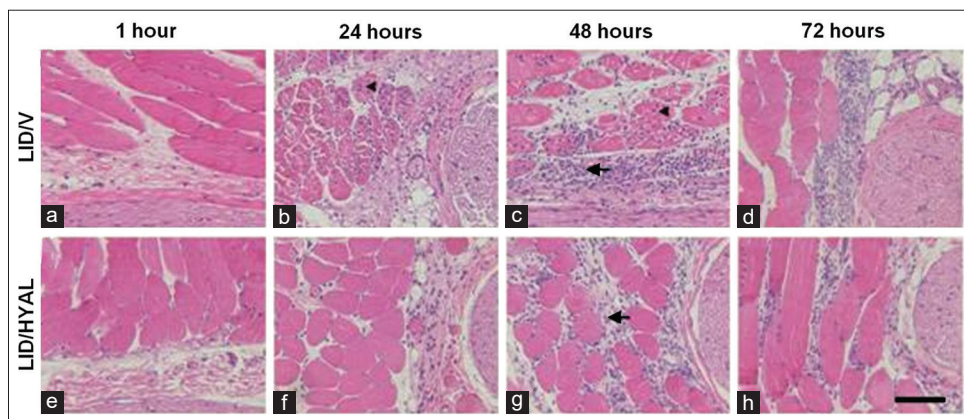
	Group (n)	Mean±SD	Median (IR)	P
		(min)	(min)	
Sensory	LID/V (25)	49.4±9.1	50.0 (42.5-55.0)	<0.0001*
	LID/HYAL (25)	79.0±16.5	80.0 (70.0-87.5)	
Motor	LID/V (25)	40.8±13.8	40.0 (32.5-45.0)	0.0011†
	LID/HYAL (25)	58.8±16.4	55.0 (50.0-75.0)	

\*Statistically significant after paired *t*-test, †Statistically significant after Wilcoxon matched-pairs signed rank test. LID/V=Lidocaine/vehicle, LID/HYAL=Lidocaine/hyaluronidase, SD=Standard deviation, IR=Interquartile range

**Table 2: Scores (0-3) obtained in the morphological analysis**

Timepoints (n=4)	LID/V		LID/HYAL	
	Median (IR)	Mean±SD	Median (IR)	Mean±SD
1 h	0 (0-0)	0±0	0 (0-0.75)	0.25±0.5
24 h	1.5 (1-2.75)	1.75±0.96	2 (2-2.75)	2.25±0.5
48 h	2 (1.25-2.75)	2±0.82	3 (1.5-3)	2.5±1
72 h	1.5 (1-2.75)	1.75±0.96	2 (2-2.75)	2.25±0.5

No statistically significant differences ( $P>0.05$ ) were found between groups within the same timepoint or between timepoints within the same group (Kruskal–Wallis and Dunn’s tests). LID/V=Lidocaine/vehicle, LID/HYAL=Lidocaine/hyaluronidase, SD=Standard deviation, IR=Interquartile range



**Figure 2: Tissue alterations after H and E stain. (a-d) Treatment with lidocaine followed by hyaluronidase’s vehicle (lidocaine/vehicle), (e-h) Treatment with lidocaine followed by hyaluronidase (lidocaine/hyaluronidase). Inflammatory cells are indicated by arrows and degenerating muscle fibers by arrowheads. Scale bar = 150 μm**



in the external nerve sheath was only partially affected, always in accordance with the degree of inflammation. The dense, picosirius red-stained connective tissue involving the nerve showed slight alterations [Figure 3].

## Discussion

The initial experimental approach intended to prove the efficacy of a late HYAL injection in prolonging LID-induced anesthesia. In this study, the rat sciatic nerve was chosen for testing because it is a mixed nerve, similar to the inferior alveolar nerve and because it is considered a valid model for the experimental evaluation of anesthesia.<sup>[12,13]</sup> Our results indicated that the use of HYAL before the end of the anesthetic effect postponed the conclusion of the complete nociceptive block induced by LID. The motor block was also extended although motor block has more frequently been observed with long-lasting anesthetics, such as bupivacaine.<sup>[1,2,14]</sup> HYAL probably facilitated the diffusion of residual anesthetic molecules surrounding the nerves at the time before anesthetic recovery and redirected these molecules to the nerve fibers, prolonging the nerve block. Nevertheless, further research is required to clarify the complete mechanisms by which this event might occur.

The interest in extending the anesthetic effect obtained with intermediate-action local anesthetics is due to their lower propensity to induce cardiotoxic and neurotoxic effects when compared with the long-acting types. This applies especially in accidental intravascular injections, as observed in animals<sup>[15]</sup> and in some case reports that have shown life-threatening cardiotoxicity caused by bupivacaine,<sup>[16,17]</sup> levobupivacaine,<sup>[18]</sup> and ropivacaine<sup>[19]</sup> in humans. The mean value obtained for the duration of the sensory block with this protocol (79 min) is close to the duration of action of long-acting anesthetics such as 0.5% ropivacaine

(about 85 min)<sup>[20]</sup> and 0.5% bupivacaine ( $90 \pm 13$  min). Therefore, HYAL could provide clinical advantages for use in medically compromised patients who have restrictions on the dosage of anesthetics or contraindications to adrenergic vasoconstrictors and long-acting local anesthetics.<sup>[1,16,21,22]</sup>

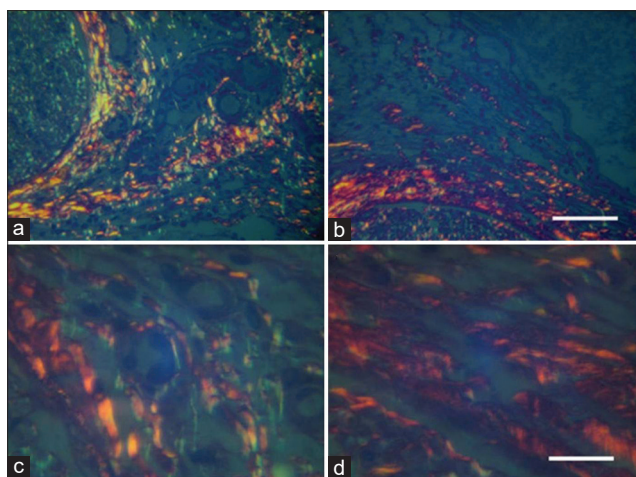
We injected HYAL 30 min after the complete block began, to ensure that the remaining local anesthetic molecules would be available to reach the nerve fibers, but this protocol could be experienced in other time intervals. Further research is also needed for testing higher concentrations of HYAL and different intermediate-acting local anesthetics.

In addition to confirming the functional effectiveness of this anesthetic protocol, histological parameters were evaluated for the first time. The results demonstrated that the anesthetic injection with HYAL did not cause more local inflammation compared with the control group that received only HYAL's vehicle. This suggests that tissue disorganization and inflammation were mainly caused by the LID injection and not by the action of HYAL. Kalichman *et al.*<sup>[23]</sup> found tissue injury after LID injection (without HYAL) near the sciatic nerve of rats, which decreased within about 2 days, confirming this hypothesis.

Compared to the control, HYAL did not cause significant inflammation and local tissue injury, even though its vehicle was also present. This fact is in agreement with the study of Fronza *et al.*<sup>[24]</sup> that showed that HYAL modulates the inflammatory response and even accelerates wound healing in rat skin. Although alterations in the extracellular matrix had occurred and that this effect may be an important step in the mechanism by which HYAL prolonged anesthesia, signs of repair were observed in the last timepoints [Figure 2 and Table 2].

A small degree of tissue injury was observed, which was always associated with chronic inflammation. From 24 to 72h after the injury, there was an influx of macrophages that probably digested the degenerating muscle fibers, followed by another population of macrophages that were associated with muscle regeneration, respectively. Although HYAL itself is unlikely to be responsible for the inflammatory cell recruitment, this mechanism could be enhanced when combined with some factor that stimulates the recruitment of these cells, for example, hyaluronan fragments could participate in macrophage recruitment.<sup>[25]</sup>

Even though HYAL administration was not expected to lead to collagen digestion,<sup>[26]</sup> we observed the disorganization of the extracellular matrix collagen fibers. As these collagen fibers are closely associated with hyaluronan,<sup>[27]</sup> the digestion of hyaluronan by HYAL might explain these effects. Nevertheless, even in the presence of inflammation, there was no damage or disruption to the nerve fibers although the dense connective tissue involving the nerve showed slight



**Figure 3:** Collagen fiber observation after picosirius red stain. Brightness reduction indicates collagen damage in the connective tissue sheath surrounding the nerve (a and c) in lidocaine/vehicle; b and d in lidocaine/hyaluronidase). Nerve fibers remained intact. (c and d) show a higher magnification of figures a and b, respectively. Scale bar = 80  $\mu$ m (a and b) and 16  $\mu$ m (c and d)

alterations when stained with picosirius red [Figure 3]. Thus, the tissue injury was restricted to the muscle and connective tissues. In addition, the full functional recovery of the animals after local anesthesia, with or without HYAL, confirms the absence of neural injury.

## Conclusion

Taken together, our results suggest that HYAL, when administered prior to the end of the LID-induced block, can be employed to prolong the local anesthetic effect without irreversible morphological alterations and reducing the need for supplementary anesthetic doses. This extended duration might be sufficient for ending most clinical procedures and could be particularly helpful in patients with medical restrictions, in whom the use of local anesthetics or vasoconstrictors is limited.

## Acknowledgments

The authors acknowledge the Coordination for the Improvement of Higher Education Personnel (CAPES). We also thank Emilia Ribeiro for her excellent technical assistance.

## Financial support and sponsorship

Foundation for Supporting Research in the State of São Paulo (FAPESP no. 07/57872-9).

## Conflicts of interest

There are no conflicts of interest.

## References

- Naguib M, Magboul MM, Samarkandi AH, Attia M. Adverse effects and drug interactions associated with local and regional anaesthesia. *Drug Saf* 1998;18:221-50.
- Leone S, Di Cianni S, Casati A, Fanelli G. Pharmacology, toxicology, and clinical use of new long acting local anesthetics, ropivacaine and levobupivacaine. *Acta Biomed* 2008;79:92-105.
- Remy M, Pinter F, Nentwich MM, Kampik A, Schönfeld CL. Efficacy and safety of hyaluronidase 75 IU as an adjuvant to mepivacaine for retrobulbar anesthesia in cataract surgery. *J Cataract Refract Surg* 2008;34:1966-9.
- Hynes WL, Walton SL. Hyaluronidases of Gram-positive bacteria. *FEMS Microbiol Lett* 2000;183:201-7.
- Palte HD. Ophthalmic regional blocks: Management, challenges, and solutions. *Local Reg Anesth* 2015;8:57-70.
- Girish KS, Kemparaju K. The magic glue hyaluronan and its eraser hyaluronidase: A biological overview. *Life Sci* 2007;80:1921-43.
- Lee A, Grummer SE, Kriegel D, Marmur E. Hyaluronidase. *Dermatol Surg* 2010;36:1071-7.
- Ridenour S, Reader A, Beck M, Weaver J. Anesthetic efficacy of a combination of hyaluronidase and lidocaine with epinephrine in inferior alveolar nerve blocks. *Anesth Prog* 2001;48:9-15.
- Tempestini Horliana AC, de Brito MA, Perez FE, Simonetti MP, Rocha RG, Borsatti MA, *et al.* Hyaluronidase increases the duration of mepivacaine in inferior alveolar nerve blocks. *J Oral Maxillofac Surg* 2008;66:286-90.
- Satish SV, Shetty KP, Kilaru K, Bhargavi P, Reddy ES, Bellutgi A, *et al.* Comparative evaluation of the efficacy of 2% lidocaine containing 1:200,000 epinephrine with and without hyaluronidase (75 IU) in patients with irreversible pulpitis. *J Endod* 2013;39:1116-8.
- Thalhammer JG, Vladimirova M, Bershadsky B, Strichartz GR. Neurologic evaluation of the rat during sciatic nerve block with lidocaine. *Anesthesiology* 1995;82:1013-25.
- Popitz-Bergez FA, Leeson S, Strichartz GR, Thalhammer JG. Relation between functional deficit and intraneural local anesthetic during peripheral nerve block. A study in the rat sciatic nerve. *Anesthesiology* 1995;83:583-92.
- Wang CF, Djalali AG, Gandhi A, Knaack D, De Girolami U, Strichartz G, *et al.* An absorbable local anesthetic matrix provides several days of functional sciatic nerve blockade. *Anesth Analg* 2009;108:1027-33.
- Neal JM, Bernards CM, Butterworth JF 4<sup>th</sup>, Di Gregorio G, Drasner K, Hejtmanek MR, *et al.* ASRA practice advisory on local anesthetic systemic toxicity. *Reg Anesth Pain Med* 2010;35:152-61.
- Groban L, Deal DD, Vernon JC, James RL, Butterworth J. Cardiac resuscitation after incremental overdosage with lidocaine, bupivacaine, levobupivacaine, and ropivacaine in anesthetized dogs. *Anesth Analg* 2001;92:37-43.
- Levsky ME, Miller MA. Cardiovascular collapse from low dose bupivacaine. *Can J Clin Pharmacol* 2005;12:e240-5.
- Rosenblatt MA, Abel M, Fischer GW, Itzkovich CJ, Eisenkraft JB. Successful use of a 20% lipid emulsion to resuscitate a patient after a presumed bupivacaine-related cardiac arrest. *Anesthesiology* 2006;105:217-8.
- Foxall G, McCahon R, Lamb J, Hardman JG, Bedford NM. Levobupivacaine-induced seizures and cardiovascular collapse treated with intralipid. *Anaesthesia* 2007;62:516-8.
- Huet O, Eyrolle LJ, Mazoit JX, Ozier YM. Cardiac arrest after injection of ropivacaine for posterior lumbar plexus blockade. *Anesthesiology* 2003;99:1451-3.
- Hung YC, Chen CY, Lirk P, Wang CF, Cheng JK, Chen CC, *et al.* Magnesium sulfate diminishes the effects of amide local anesthetics in rat sciatic-nerve block. *Reg Anesth Pain Med* 2007;32:288-95.
- Freysz M, Timour Q, Bertrix L, Loufoua-Moundanga J, Omar S, Faucon G, *et al.* Enhancement by ischemia of the risk of cardiac disorders, especially fibrillation, in regional anesthesia with bupivacaine. *Acta Anaesthesiol Scand* 1993;37:350-6.
- Compagna R, Vigliotti G, Coretti G, Amato M, Aprea G, Puzziello A, *et al.* Comparative study between levobupivacaine and bupivacaine for hernia surgery in the elderly. *BMC Surg* 2012;12 Suppl 1:S12.
- Kalichman MW, Moorhouse DF, Powell HC, Myers RR. Relative neural toxicity of local anesthetics. *J Neuropathol Exp Neurol* 1993;52:234-40.
- Fronza M, Caetano GF, Leite MN, Bitencourt CS, Paula-Silva FW, Andrade TA, *et al.* Hyaluronidase modulates inflammatory response and accelerates the cutaneous wound healing. *PLoS One* 2014;9:e112297.
- Chiarella P, De Santis S, Fazio VM, Signori E. Hyaluronidase contributes to early inflammatory events induced by electrotransfer in mouse skeletal muscle. *Hum Gene Ther* 2013;24:406-16.
- Turkovski II, Paramonov BA, Antonov SF, Kozlov DN, Klimova OA, Pomorski KP, *et al.* Comparative evaluation of the depth of collagen and hyaluronic acid hydrolysis *in vitro* by collagenase and hyaluronidase preparations. *Bull Exp Biol Med* 2008;146:81-2.
- Junqueira L, Carneiro J. *Basic Histology: Text and Atlas*. 11<sup>th</sup> ed. New York: McGraw-Hill; 2005. p. 554.

Copyright of Indian Journal of Dental Research is the property of Wolters Kluwer India Pvt Ltd and its content may not be copied or emailed to multiple sites or posted to a listserv without the copyright holder's express written permission. However, users may print, download, or email articles for individual use.