

Treatment of Canine Multicentric Lymphoma Through Vascular Access Port vs. Peripheral Venous Catheter*

Brunna de Souza Barni¹, José Ricardo Herrera Becerra¹, Silvana Bellini Vidor¹, Mariana Pires de Oliveira¹, Luciane Cristina Vieira², Calvin Braga Gnoatto³, Stella de Faria Valle⁴, Cristiano Gomes⁴, Giordano Cabral Gianotti² & Emerson Antonio Contesini⁴

ABSTRACT

Background: Vascular access port (VAP) was developed for the administration of chemotherapeutic agents, minimizing local drug reactions and complications associated with migration of peripheral venous catheter (PVC) in humans. The device is widely used in human oncology and has gained importance in veterinary oncology, especially in long treatment regimens, as in the case of canine lymphoma. VAP favors therapy and the animals life quality. The aim of this study was to describe the use of VAP in dogs, comparing to PVC access, during canine lymphoma chemotherapeutic treatment.

Materials, Methods & Results: Eleven dogs with multicentric lymphoma which required chemotherapy were selected for the study. The dogs were randomly allocated to two groups with five and six animals, and each group received the chemotherapy protocol through the PVC (n= 5) or VAP (n= 6). For the sake of standardization, assessments were made whenever the dogs received vincristine sulfate, despite the use of the infusion system in all sessions of the Madison-Wisconsin protocol. A VAP was implanted into the right external jugular vein of six dogs under inhalational anesthesia, using the Seldinger technique. Systolic blood pressure (SBP) levels and handling time during chemotherapy sessions were compared in both groups in three time periods during the procedures: 10 min after arrival to each chemotherapy (P1); immediately after placement of the PVC or puncture of the VAP reservoir (P2); and at the end of chemotherapy (P3). The arithmetic mean of five consecutive assessments was used in each time period. In the chemotherapy sessions, the mean of SBP variation decreased statistically significant in the VAP group compared to PVC group. SBP decreased from P1 to P2 and from P1 to P3 in all sessions (S1, S2, and S3) in the VAP group, and increased in the PVC group. The handling time of VAP group was 110.6 ± 8.4 s, compared to 219.2 ± 24.7 s (mean \pm standard error) in the PVC group, showing statistically significant difference ($P < 0.001$). VAP surgical implantation time averaged 37 min, decreasing gradually from the first (55 min) to the last patient (21 min).

Discussion: SBP levels suggest that the VAP group was calmer from the beginning to the end of the sessions, showed lower SBP levels, and required shorter handling time than did the PVC group. Blood pressure is one of the most objective ways to assess welfare or stress in dogs. When dog feels threatened or scared, its body automatically enters a state of emergency and, among several changes, blood pressure increases. VAP surgical implantation in dogs have easy learning, as previously described, proven by implantation time progressive reduction. The Seldinger technique is the method of choice for catheter implantation in humans. Dissection of the jugular vein is an alternative, however, the technique with a single incision and venipuncture is less invasive than its modifications. The jugular vein was used because is the site of choice for central accesses in veterinary practice, with a shorter path to the right atrium and smaller rates of catheter misplacement, reducing the risk of pneumothorax, venous thrombosis, and pinch-off syndrome. VAP surgical implantation in dogs have easy learning, proven by the implantation time progressive reduction. The study confirmed that VAP promoted animal welfare, shortened chemotherapy sessions, and caused less discomfort to dogs treated for multicentric lymphoma, as indicated by the reduction in SBP, when compared to the PVC group.

Keywords: antineoplastic therapy, canine, oncology, port-a-cath.

DOI: 10.22456/1679-9216.102523

Received: 6 February 2020

Accepted: 24 May 2020

Published: 16 June 2020

*Article based on a Thesis submitted by the first author in partial fulfillment of requirements for the Master's Degree. ¹Programa de Pós-Graduação em Ciências Veterinárias (PPGCV); ²Hospital de Clínicas Veterinárias (HCV); ³Faculdade de Veterinária (FAVET) & ⁴Departamento de Medicina Animal (DMA) - FAVET, Universidade Federal do Rio Grande do Sul (UFRGS), Porto Alegre, RS, Brazil. CORRESPONDENCE: B.S. Barni [brunnabarni@hotmail.com]. PPPG-CV - UFRGS. Av. Bento Gonçalves n. 9090. CEP 91540-000 Porto Alegre, RS, Brazil.

INTRODUCTION

Multicentric lymphoma accounts for approximately 50% of cases of canine lymphoma [7], and the Madison-Wisconsin protocol, is a chemotherapy conducted for a long time period, until remission and/or survival [6]. Intravenous drugs used cause necrosis and detachment of the subcutaneous tissue in case of extravasation, requiring constant monitoring of the patient during their application [30].

Vascular access port (VAP) was developed for the administration of chemotherapeutic agents, minimizing local drug reactions and complications associated with migration of peripheral venous catheter (PVC) in humans [9]. The device is widely used in human oncology and has gained importance in veterinary oncology as well, especially in long treatment regimens, as in the case of lymphoma [16]. VAP favors therapy and the animals' quality of life [24].

Utilization of VAP is not a regular practice and is not commonly investigated in the veterinary medicine literature [18]. It is suggested that the device reduces the discomfort caused by PVC, promoting animal welfare with multicentric lymphoma during the long treatment regimen [14]. The aim of this study was to describe the use of VAP in dogs, comparing to PVC access, during canine lymphoma chemotherapeutic treatment.

MATERIALS AND METHODS

Selection of animals

Eleven dogs with multicentric lymphoma treated with chemotherapy at the Veterinary Teaching Hospital were included in the study. The dogs were male or female, of different breeds, weights, and ages, no aggressive behavior, were not on antihypertensive medication and without heart disease, discarded on electrocardiogram and echocardiogram. Before than start chemotherapeutic treatment, the dogs were randomly allocated to two groups with five and six animals, and each group received the chemotherapy protocol through the PVC (n= 5) or VAP (n= 6). For the sake of standardization, assessments were made whenever the dogs received vincristine sulfate¹, despite the use of the infusion system in all sessions of the Madison-Wisconsin protocol, which lasted 25 weeks.

Methodology

A VAP was implanted into the right external jugular vein of six dogs under inhalational anesthesia. The dogs received preoperative intravenous antibiotic prophylaxis with sodium ampicillin² (22 mg.kg⁻¹) and were then placed on left lateral decubitus with the right thoracic limb caudally. Catheter length was estimated, and it should reach the fourth rib region, at the junction of the cranial vena cava with the right atrium. Hair was shaved and antiseptics were performed at ventral and lateral neck. An anesthetic block was made with lidocaine hydrochloride³ (4 mg.kg⁻¹) in the skin incision area where the catheter reservoir would be inserted.

VAP implantation was timed since percutaneous puncture until last skin suture. BardPort M.R.I.[®] Hard Base Port (6.6 French)⁴, a plastic single lumen, open-ended catheter of radiopaque silicone, was the VAP used. The Seldinger implantation technique was performed always by the same surgeon. The procedure started with percutaneous puncture of the jugular vein in blood flow direction, in the region between the mandibular angle and the manubrium, using a needle and a 10-mL syringe containing 5 mL of sodium chloride⁵ (NaCl 0.9%) [Figure 1A], provided with implantation kit. A metal guidewire was advanced through needle until it reached the vessel lumen, and the needle was removed (Figure 1B). A specific dilator from the kit was inserted up to the jugular vein (Figure 1C), which was dilated, permitting the removal of the guidewire and catheter insertion through the dilator. After the catheter insertion into the blood vessel, the dilator was split apart and removed (Figure 1D). Thereafter, a semilunar skin incision was made 5 cm above the puncture site in the medial dorsal neck region (Figure 1E) for placement of the catheter reservoir. The catheter was then advanced through the subcutaneous tissue to the incision area using the tunneler equipment provided with the implantation kit (Figure 1F & 1G) and connected to the reservoir. The reservoir was then attached to the muscle fascia below the incision with mononylon (3-0)⁶ threads through the holes (Figure 1H). The system functionality was tested by aspirating blood with a 10-mL syringe through the Huber⁷ needle connected to the reservoir. The skin was sutured over the reservoir with mononylon 3-0/6 threads (Figure 1I). The catheter was flushed with heparin sodium³ (100 IU.mL⁻¹).

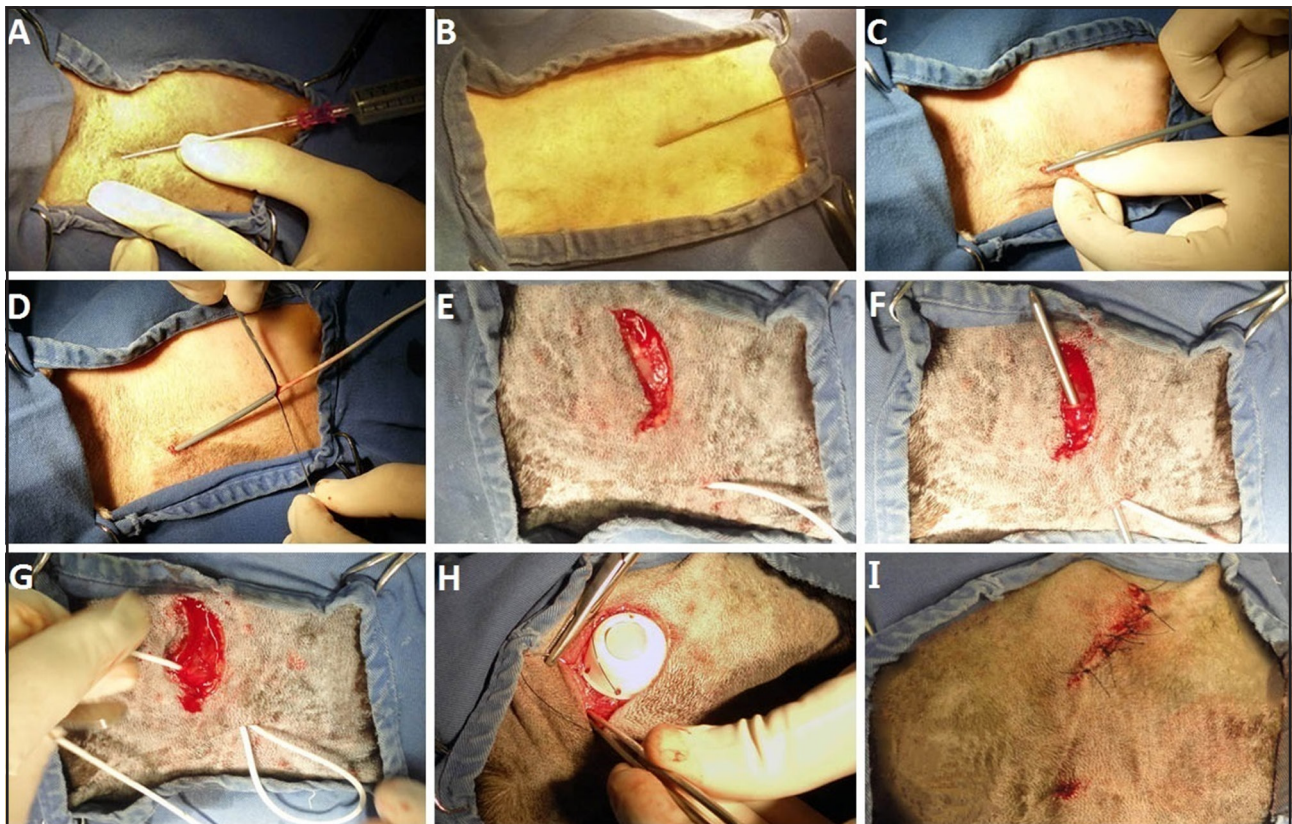


Figure 1. Vascular access port implantation in a dog (skull shown on the right side). A- Jugular vein puncture with needle and syringe, in blood flow direction. B- Insertion of guidewire into the blood vessel. C- Dilation of tissues with specific tool. D- Placement of catheter and removal of dilator. E- Semilunar skin incision for catheter reservoir placement. F- Insertion of tunneler towards the skin incision. G- Advancement of the catheter connected to the tunneler through the subcutaneous tissue. H- Attachment of the reservoir to the neck musculature. I- Skin suture and final aspect.

The dogs were discharged on sodium dipyrone⁸ (25 mg.kg⁻¹, every 8 h for three days) and the owners were instructed to cleanse the stitches with NaCl 0.9%⁵ until their removal at 10 days. Two days after implantation, the dogs were ready for chemotherapy, but assessments began only after the stitches were removed, to not interfere in needle fixation.

Hair was shaved and antisepsis of reservoir region was performed before the infusion of chemotherapeutic drugs. A Huber needle⁷ (20 G and 20 mm) and a 10-mL syringe were used whenever the VAP reservoir was punctured. The owner restrained the animal during all the procedure. The Huber needle⁷ was inserted into the reservoir, and aspiration with a syringe was performed to confirm the proper operation of VAP through blood return.

Chemotherapy protocol

The chemotherapeutic agent was administered via a NaCl 0.9%⁵ infusion system connected to VAP. The patients were kept on NaCl 0.9%⁵ until approxi-

mately 20 mL was infused, thus eliminating any residues of the chemotherapeutic agent from the catheter. After that, the catheter was flushed with heparin - see manufacturer's values (0.6 mL for the reservoir plus 0.01 mL for each centimeter of the catheter), and the Huber needle⁷ was removed. The VAP was handled always by the same veterinarian.

The remaining five dogs received conventional chemotherapeutic treatment. In all sessions, the dogs were physically restrained by an assistant. Hair was shaved and antisepsis of right or left thoracic limb was performed, in cranial radio and ulna region. Afterwards, the cephalic vein was punctured for PVC placement (Radiopaque Safelet catheter)⁹, with manual tourniquet applied in the limb by the assistance. The catheter gauge depended of the dog size. The venipuncture was performed always by the same veterinarian. The chemotherapeutic agent was administered using a NaCl 0.9%⁵ infusion system connected to the PVC, removed at the end of the infusion.

Noninvasive systolic blood pressure (SBP) was checked in both groups (doppler vascular¹⁰ and aneroid sphygmomanometer¹¹) in three time period during procedures: 10 min after arrival to each chemotherapy (P1); immediately after placement of the PVC or puncture of the VAP reservoir (P2); and at the end of chemotherapy (P3). The arithmetic mean of five consecutive assessments was used in each time period. To compare SBP assessments of each dog, the percent variation in blood pressure levels between P1 and P2 and P1 and P3 was calculated using the formula: $[(P2-P1)/P1]*100$ and $[(P3-P1)/P1]*100$.

Handling time during each session was recorded, not including SBP assessments and infusion of the chemotherapeutic drug. The patients were assessed for 60 days in three chemotherapy sessions (S1, S2, and S3). At the end of the treatment protocol, VAP was maintained in place, as owner's option, and the dogs returned for heparinization every four weeks.

Statistical analysis

The statistical analysis was performed using IBM SPSS version 22¹² SBP and handling time were denoted as mean and standard error and compared by generalized estimating equations (GEEs). The significance level was set at 0.05.

RESULTS

In the chemotherapy sessions, the mean of SBP variation decreased statistically significant in the VAP group compared to PVC group. SBP decreased from P1 to P2 and from P1 to P3 in all sessions (S1, S2, and S3) in the VAP group, and increased in the PVC group. Only SBP from P1 to P3 in S2 was not statistically significant between the two groups (Figure 2). The handling time of VAP group was 110.6 ± 8.4 s, compared to 219.2 ± 24.7 s (mean \pm standard error) in the PVC group, showing statistically significant difference ($P < 0.001$). The larger handling time in the PVC group resulted from the difficulty in puncturing the vein and positioning the catheter in the frequent vascular accesses.

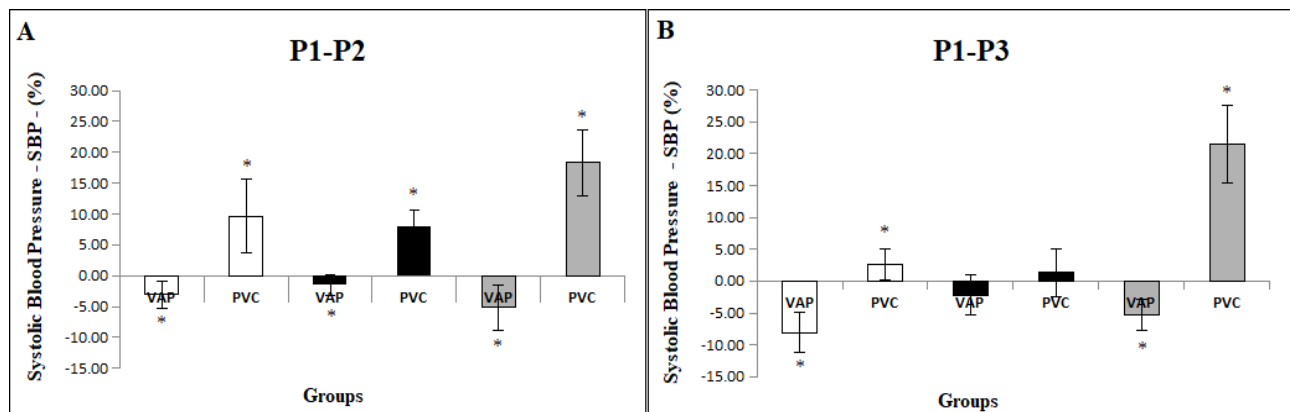


Figure 2. Systolic blood pressure (SBP) variation in dogs subjected to chemotherapy through vascular access port (VAP) or peripheral venous catheter (PVC). The boxes represent the mean percentage of SBP variation in different sessions (S1 - white, S2 - black, S3 - gray) and in the groups (VAP and PVC). Vertical bars indicate standard errors. A- Variation between P1 (rest) and P2 (after venipuncture). Groups followed by * are statistically different according to GEE: $P = 0.047$ in S1, $P = 0.002$ in S2, and $P < 0.001$ in S3. B- Variation between P1 (rest) and P3 (end of chemotherapy). Groups followed by * are statistically different according to GEE: $P = 0.008$ in S1 and $P < 0.001$ in S3.

VAP implantation time averaged 37 min, decreasing gradually from the first (55 min) to the last patient (21 min). All VAP were implanted using the Seldinger technique. A 6.6 French catheter was chosen, and its use was slightly difficult in smaller animals because of venous lumen diameter.

Estimating the length of the VAP to be inserted was a hindrance, since imaging resources were not available in the surgical ward. Positioning was confirmed by chest X-ray only at the time of stitch removal.

In the smallest dog (6.2 kg), VAP was long and reached the caudal vena cava, without any complications in echocardiogram and electrocardiogram.

The largest three dogs (13.5, 25 and 26 kg) had thick skin and developed seroma around the VAP reservoir. Two dogs did not have any relapse after drainage. The dog weighing 13.5 kg, in which the catheter was advanced along a larger subcutaneous path, had major seroma and relapse after drainage, and the dead space had to

be eliminated with polyglactin 910 (3-0)⁶ sutures on a single plane with single stitches under general anesthesia. In the same dog, because of thick skin, the reservoir was directed cranial towards the skin incision after advancement of the VAP through the subcutaneous tissue, as the angle would be too acute at the reservoir inlet. Thus, the catheter was advanced caudally, with longer subcutaneous tunneling. Probably catheter long and seroma resulted in catheter looping (Figure 3).

A dog of VAP group was excluded from SBP measuring results, and had the VAP removed, because of subcutaneous catheter tip migration 24 days after implantation and after two chemotherapy sessions. The catheter length estimate at implant procedure was inaccurate and the catheter did not reach the correct site in at the junction of the cranial vena cava with the right atrium (Figure 4A). The problem was detected when there was no blood return through the catheter in third chemotherapy session, confirmed by radiography (Figure 4B).

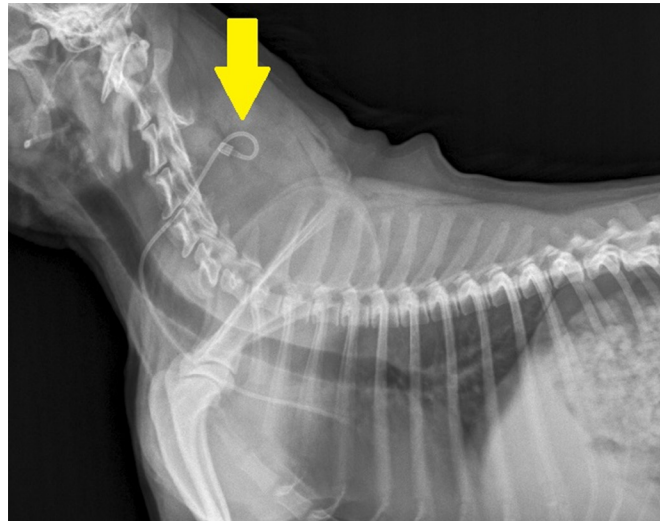


Figure 3. Plain radiograph (lateral view) of a dog with vascular access port (VAP) catheter looping close to the reservoir, in the neck region (arrow).

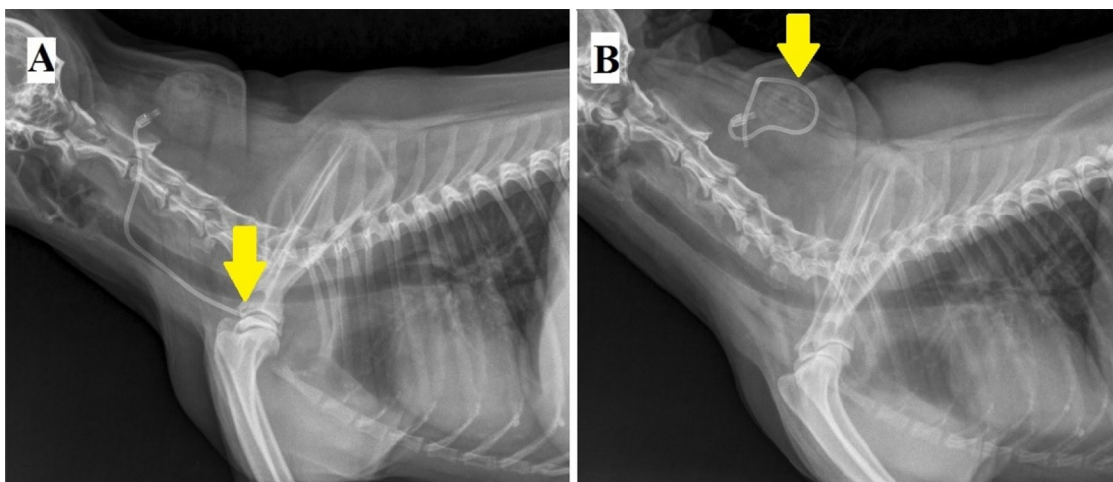


Figure 4. Plain radiograph (lateral view) of a dog with vascular access port (VAP). A- VAP shorter than would be necessary (arrow); B- VAP migration into subcutaneous tissue (arrow).

DISCUSSION

SBP levels suggest that the VAP group was calmer from the beginning to the end of the sessions, showed lower SBP levels, and required shorter handling time than did the PVC group. Blood pressure is one

of the most objective ways to assess welfare or stress in dogs [31]. When dog feels threatened or scared, its body automatically enters a state of emergency and, among several changes, blood pressure increases [22]. SBP is also influenced by stress and anxiety during

veterinary care (“white-coat syndrome”) [28], but this may be minimized with VAP. It may be also inferred that VAP reduced pain, although to a lesser extent, caused by venipuncture, increasing the circulating levels of catecholamines and, consequently, of blood pressure [23]. This study, to some extent, assessed the discomfort of animals caused by venipunctures and demonstrated the VAP benefits for pain relief and reduction patient discomfort in repeated venipunctures [14]. Another factor that might have contributed to lower SBP in the VAP group, compared to the PVC group, was restraint by the owners that keeping the dogs comfortable and reducing their stress [27]. Our results suggest that the VAP could be an alternative for stressed and aggressive animals or those of difficult containment.

VAP surgical implantation in dogs have easy learning, as previously described [24], proven by implantation time progressive reduction. The Seldinger technique is the method of choice for catheter implantation in humans; in addition, it is less time-consuming and has a higher success rate at the first attempt [19], even in smaller animals, since there is no correlation between a successful implantation and weight of the patients [1]. Dissection of the jugular vein is an alternative, as in the experiment that used #5 and 7 French catheters for animals weighing up to 15 kg and over 15 kg, respectively [14]. However, the technique used, with a single incision and venipuncture, is less invasive than its modifications [14]. The jugular vein was used because is the site of choice for central accesses in veterinary practice, with a shorter path to the right atrium and smaller rates of catheter misplacement, reducing the risk of pneumothorax, venous thrombosis, and pinch-off syndrome [17]. Previous studies have used the jugular vein to placed VAP for chemotherapy in dogs [24,29], and also other sites such as the femoral vein, left atrium, and aorta [3,5].

In our study, catheter length was estimated up to the fourth rib, as the VAP should be advanced to the level of the right atrium [29]. The chest X-ray confirmed the position, as indicated [8]. Imaging made by a fluoroscope, electrocardiogram, or ultrasound guides the implantation and minimizes the risk of catheter misplacement [15], but a study did not find any differences between the use of an electrocardiogram or the blind technique used herein [8]. Catheter misplacement may cause cardiac ar-

rhythmia, cardiac tamponade, phlebitis, hemothorax, sepsis, and even cardiac perforation [8]. These complications were not observed, even in the dog that VAP reached the caudal vena cava, as a similar case previously reported [24].

Seroma is a minor complication described in veterinary [11] and human medicine [2,25]. In dogs here related the seroma had to be drained, unlike in felines, in which the seroma resolved spontaneously [2]. Reduction of the dead space is recommended, as dogs are prone to seroma development in neck region [26], besides the potential to develop atypical and aggressive bacterial infection in the seromatous fluid [10], which could predispose to VAP contamination. Others complications such as edema, hematoma, catheter fracture, sepsis, occlusion, self-harm events, thromboembolism, extravasation, fistula formation, and disconnection of the catheter from the reservoir [4,25], were not observed in our study. The maneuver performed in the thick-skinned dog prevented the catheter from bending, which could cause obstruction and catheter failure [21]. Late migration of VAP into the subcutaneous tissue in this study has been described in humans [20], but classified as early migration, occurring between two and seven days after implantation or until the first chemotherapy session [12]. The dog here described was overweight and thin-skinned, factors that might have contributed to the migration of the VAP tip, suggesting non-recommending of the device in these cases.

We observed other advantage of VAP as the lack of external components that could disturb the animal, the prevention of multiples peripheral veins punctures, and no worries with catheter management by owners during treatment [4,13,26]. Our results demonstrated that VAP device was effective in canine lymphoma regarding duration of Madison-Wisconsin therapy protocol, preserving peripheral vessels [29].

CONCLUSIONS

The study confirmed that VAP promoted animal welfare, shortened chemotherapy sessions, and caused less discomfort to dogs treated for multicentric lymphoma, as indicated by the reduction in SBP, when compared to the PVC group. The Seldinger technique is feasible for dogs, its complications could be managed without any harm to the animals, and its frequent use in veterinary medicine should be therefore encouraged.

MANUFACTURERS

- ¹Zodiac Produtos Farmacêuticos S/A. Pindamonhangaba, SP, Brazil.
²Teuto Brasileiro S/A. Anápolis, GO, Brazil.
³Cristália Produtos Químicos Farmacêuticos Ltda. Itapira, SP, Brazil.
⁴Bard Access Systems Inc. Salt Lake City, UT, USA.
⁵Halex Istar Indústria Farmacêutica S.A. Goiânia, GO, Brazil.
⁶Shalon fios cirúrgicos Ltda. Alto da Boa Vista, RR, Brazil.
⁷Sterylab S.r.l. Milan, Lombardia, Italy.
⁸EMS S/A. Hortolândia, SP, Brazil.
⁹Nipro Medical Ltda. Sorocaba, SP, Brazil.
¹⁰Parks Medical Electronics Inc. Aloha, OR, USA.
¹¹Incoterm Ltda. Porto Alegre, RS, Brazil.
¹²SPSS Inc. IBM Company. Chicago, IL, USA.

Acknowledgments. VET Medical; Saavedra Representações Ltda.; Veterinary doctors Luciana Branquinho Queiroga e Luciana Oliveira de Oliveira.

Ethical approval. This study was approved by the Ethics Committee on Animal Research of Universidade Federal do Rio Grande do Sul (CEUA-UFRGS), Brazil (protocol 29601).

Declaration of interest. The authors report no conflicts of interests. The authors alone are responsible for the content and writing of paper.

REFERENCES

- 1 Araújo C.C., Lima M.C. & Falbo G.H. 2007.** Percutaneous subclavian central venous catheterization in children and adolescents: success, complications and related factors. *Jornal de Pediatria*. 83(1): 64-70.
- 2 Aubert I., Abrams-Ogg A.C.G., Sylvestre A.M., Dyson D.H., Allen D.G. & Johnstone I.B. 2011.** The use of vascular access ports for blood collection in feline blood donors. *Canadian Journal of Veterinary Research*. 75(1): 25-34.
- 3 Bartoli C.R., Okabe K., Akiyama I., Coull B. & Godleski J.J. 2008.** Repeat microsphere delivery for serial measurement of regional blood perfusion in the chronically instrumented conscious canine. *Journal of Surgery Research*. 145(1): 135-141.
- 4 Bryson V., Fox L.E. & Crum H. 2005.** Long-term totally implantable venous access ports in dogs and cats receiving chemotherapy. *Veterinary Comparative Oncology*. 3(1): 37.
- 5 Cahalane A.K., Rassnick K.M. & Flanders J.A. 2007.** Use of vascular access ports in femoral veins of dogs and cats with cancer. *Journal of American Veterinary Medical Association*. 231(9): 1354-1360.
- 6 Cápuá M.L.B., Coleta F.E.D., Canesin A.P.M.N., Godoy A.V., Calazans S.G., Miotto M.R., Daleck C.R. & Santana A.E. 2011.** Canine lymphoma: clinical and hematological aspects and treatment with the Madison-Wisconsin protocol. *Ciência Rural*. 41(7): 1245-1251.
- 7 Cardoso M.J.L., Machado L.H.A., Moutinho F.Q. & Padovani C.R. 2004.** Clinical signs of the canine lymphoma. *Archives of Veterinary Science*. 9(2): 19-24.
- 8 Claude A.K., Riedesel D.H. & Riedesel E.A. 2010.** Electrocardiography-guided and retrospective analysis of central venous catheter placement in the dog. *Veterinary Anaesthesia and Analgesia*. 37(2): 97-105.
- 9 Dalton M.J. 1985.** The vascular access port. *Laboratory Animals*. 14(7): 21-30.
- 10 Diniz P.P.V.P., Wood M., Maggi R.G., Sontakke S., Stepnik M. & Breitschwerdt E.B. 2009.** Co-isolation of *Bartonella henselae* and *Bartonella vinsonii* subsp. *berkhoffii* from blood, joint and subcutaneous seroma fluids from two naturally infected dogs. *Veterinary Microbiology*. 138(3-4): 368-372.
- 11 Farrow H.A., Rand J.S., Burgess D.M., Coradini M. & Vankan D.M. 2013.** Jugular vascular access port implantation for frequent, long-term blood sampling in cats: methodology, assessment, and comparison with jugular catheters. *Research of Veterinary Sciences*. 95(2): 681-686.
- 12 Froehner Júnior I. 2005.** Cateteres venosos centrais totalmente implantáveis para quimioterapia em 100 pacientes portadores de neoplasia maligna. 75f. Florianópolis, SC. Trabalho de Conclusão de Curso (Graduação em Medicina), Faculdade de Medicina da Universidade Federal de Santa Catarina.
- 13 Graham M.L., Rieke E.F., Wijkstrom M., Dunning M., Aasheim T.C., Graczyk M.J., Pilon K.J. & Hering B.J. 2008.** Risk factors associated with surgical site infection and the development of short-term complications in macaques undergoing indwelling vascular access port placement. *Journal of Medical Primatology*. 37(4): 202-209.
- 14 Guérios S.D., Silva D.M., Souza C.H.M. & Bacon N.J. 2015.** Surgical placement and management of jugular vascular access ports in dogs and cats: description of technique. *Revista Colombiana de Ciencias Pecuarias*. 28(3): 265-271.
- 15 Jesus P.O.B, Freitas M.V., Ferreira F.S. & Silva J.F.S. 2010.** Central venous access in dogs and cats - a review. *Medvep - Revista Científica de Medicina Veterinária*. 8(27): 736-741.
- 16 Massari F. & Romanelli G. 2008.** Clinical experience with subcutaneous implant systems for intravenous therapies. *Veterinaria (Cremona)*. 22(5): 43-50.

- 17 Melchert A., Meneses A.M.C., Brant J.R.A.C., Balbi A.L., Caramori J. & Barretti P. 2008. Hemodialysis vascular access with temporary double-lumen catheter in dogs with acute renal failure. *Ciência Rural*. 38(4): 1010-1016.
- 18 Nies K.S., Kruitwagen H.S., Straten G., Bruggen L.W.L., Robben J.H., Schotanus B.A., Akkerdaas I. & Kummelin A. 2019. Innovative application of an implantable venous access system in the portal vein: technique, results and complications in three dogs. *BMC Veterinary Research*. 15(1): 240.
- 19 Nocito A., Wildi S., Rufibach K., Clavien P.A. & Weber M. 2009. Randomized clinical trial comparing venous cutdown with the Seldinger technique for placement of implantable venous access ports. *British Journal of Surgery*. 96(10): 1129-1134.
- 20 Oliveira S.C.V., Steckert J.S., Russi R.F & Steckert Filho A. 2008. Totally implantable catheter in cancer patients: 178 consecutive cases analysis. *Arquivos Catarinenses de Medicina*. 37(1): 43-48.
- 21 Ortolani L., Gasparino R.C. & Traldi M.C. 2013. Complications associated with the use of the indwelling catheter in children and adolescents. *Revista Brasileira de Cancerologia*. 59(1): 51-56.
- 22 Prada I.L.S., Massone F., Cais A., Costa P.E.M. & Seneda M.M. 2002. Methodological and neurofunctional bases for the evaluation of pain / suffering presence in animals. *Revista de Educação Continuada em Medicina Veterinária e Zootecnia do CRMV-SP*. 5(1): 1-13.
- 23 Saccò M., Meschi M., Regolisti G., Detrenis S., Bianchi L., Bartonelli M., Pioli S., Magnano A., Spagnoli F., Giuri P.G., Fiaccadori E. & Caiazza A. 2013. The relationship between blood pressure and pain. *Journal of Clinical Hypertension (Greenwich)*. 15(8): 600-605.
- 24 Santos E.R., Rosa N.S., Barni B.S., Oliveira M.P., Venâncio J.S., Contesini E.A., Muccillo M.S. & Driemeier D. 2016. Implant of Port-o-Cath for antineoplastic chemotherapy in a canine: case report. *Arquivo Brasileiro de Medicina Veterinária e Zootecnia*. 68(6): 1453-1457.
- 25 Silva F.S. & Campos R.G. 2009. Complications of the use of the totally implantable catheter in oncological patients: an integrative review. *Cogitare enfermagem*. 14(1): 159-164.
- 26 Swindle M.M., Nolan T., Jacobson A., Wolf P., Dalton M.J. & Smith A.C. 2005. Vascular access port (VAP) usage in large animal species. *Journal of American Association of Laboratory Animal Sciences*. 44(3): 7-17.
- 27 Tebaldi M., Lourenço M.L.G., Machado L.H.A., Sudano M.J. & Carvalho L.R. 2012. Study of blood pressure by the indirect oscillometric method (petmap®) in domestic unanesthetized dogs. *Arquivo Brasileiro de Medicina Veterinária e Zootecnia*. 64(6): 1456-1464.
- 28 Tebaldi M., Machado L.H.A. & Lourenço M.L.G. 2015. Blood pressure in dogs: a review. *Veterinária e Zootecnia*. 22(2): 198-208.
- 29 Valentini F., Fassone F., Pozzebon A., Gavazza A. & Lubas G. 2013. Use of totally implantable vascular access port with mini-invasive Seldinger technique in 12 dogs undergoing chemotherapy. *Research in Veterinary Sciences*. 94(1): 152-157.
- 30 Withrow S.J. 2013. Why worry about cancer in pets? In: *Small Animal Clinical Oncology*. New York: Elsevier Saunders, pp.xv-xvii.
- 31 Yamamoto K.C. M., Silva E.Y.T., Costa K.N., Souza M.S., Silva M.L.M., Albuquerque V.B., Pinheiro D.M., Bernabé D.G. & Oliva V.N.L.S. 2012. Physiological and behavioral assessment in dogs used in Animal-Assisted Therapy (ATT). *Arquivo Brasileiro de Medicina Veterinária e Zootecnia*. 64(3): 568-576.