



Onychomycosis caused by *Arthrinium arundinis* in leprosy patient: Case report

Rodrigo Vettorato^{a,b}, Daiane Heidrich^a, Letícia Maria Eidt^c, Danielle Machado Pagani^d,
Amanda Carvalho Ribeiro^e, Priscila Dallé da Rosa^a, Gerson Vettorato^b, Taís Guarienti Amaro^b,
Maria Lúcia Scroferneker^{a,e,*}

^a Postgraduate Program in Medicine: Medical Sciences, Universidade Federal do Rio Grande do Sul, Rua Ramiro Barcelos, 2400, 2nd floor, Porto Alegre, CEP: 90035-003, Brazil

^b Dermatology Service of Complexo Hospitalar Santa Casa de Misericórdia de Porto Alegre, Rua Professor Annes Dias - 135, Porto Alegre, CEP: 90020-090, Brazil

^c Ambulatory of Sanitary Dermatology of Porto Alegre, Av. João Pessoa, 1327, Porto Alegre, CEP: 90040-001, Brazil

^d Postgraduate Program in Agricultural and Environmental Microbiology, ICBS, Universidade Federal do Rio Grande do Sul, Rua Sarmento Leite, 500 - 210, Porto Alegre, CEP: 90050170, Brazil

^e Department of Microbiology, ICBS, Universidade Federal do Rio Grande do Sul, Rua Sarmento Leite, 500, Porto Alegre, CEP: 90050-170, Brazil

ARTICLE INFO

Keywords:

Onychomycosis
Arthrinium
Leprosy
Non-dermatophyte

ABSTRACT

We report a case of a 56-year-old Brazilian woman, with relapsing lepromatous leprosy, and onychomycosis caused by a non-dermatophyte filamentous fungi. The pathogenic fungi was identified as *Arthrinium arundinis* and treated with chemical abrasion of the nail with 40% urea and application of terbinafine cream. Onychomycosis caused by *Arthrinium* species is rare, and this is the second reported case.

1. Introduction

Onychomycosis are fungal infections of the nail plate. Commonly caused by dermatophytes, but also by yeasts and non-dermatophyte filamentous fungi (NDFF) [1]. Most NDFF do not have keratinophilic activity, it is a secondary invader of previously traumatized or damaged nails [2].

The NDFF most often described causing onychomycosis are *Scopulariopsis brevicaulis*, *Fusarium* sp., *Acremonium* sp., *Aspergillus* sp., *Scitellidium* sp., and *Scedosporium* sp [3–5]. This species are usually resistant to conventional onychomycosis treatments [2,4,6]. The genus *Arthrinium* comprises a group of NDFF, most of the species are endophytes of several plants [7]. Only one case of onychomycosis has been identified as caused by *Arthrinium arundinis* species [7]. The aim of this case is to report onychomycosis caused by *Arthrinium arundinis* in a lepromatous leprosy patient in Porto Alegre, Rio Grande do Sul, Brazil.

2. Case presentation

A 56 years-old female patient with relapsing lepromatous leprosy in

polychemotherapy, bilateral cataract, visual deficit, hypertension, lupus, diabetes mellitus, osteoporosis, scleroderma, and renal failure in first readministration of multidrug therapy (day 0). The patient was attended in the Ambulatório de Dermatologia Sanitária (ADS) in Porto Alegre. The leprosy treatment follows the multidrug therapy (MDT) protocol recommended by the World Health Organization (WHO) [8]. Rifampicin, dapsone and clofazimine are standard MDT drugs. As this patient developed dapsone-induced anemia, our medical team decided to use rifampicin, ofloxacin and clofazimine, an alternative MDT recommended by WHO. Peripheral neuropathy and immunological reactions are common in leprosy patients. In this case, the patient presented leprosy nodular erythema and chronic neuropathic pain. Thalidomide and amitriptyline were associated with MDT to treat these clinical conditions. A mycological exam was performed after clinical observation of total toenails dystrophy in the left foot, suggesting onychomycosis (Fig. 1A). Direct examination of the nail scrapings showed hyaline septate hyphae, and branching at acute angles of <90° (Fig. 1D). The treatment was started immediately with chemical abrasion with a 40% urea solution on the nail plate. On day 14, white and flat colonies were observed on Mycosel® agar (Fig. 1B) after incubation in 25 °C and

* Corresponding author. Microbiology Department, ICBS, Universidade Federal do Rio Grande do Sul, Rua Sarmento Leite, 500, Room, 325, Porto Alegre, CEP: 90050-170, Brazil.

E-mail address: scrofern@ufrgs.br (M.L. Scroferneker).

<https://doi.org/10.1016/j.mmcr.2020.09.001>

Received 24 June 2020; Received in revised form 31 August 2020; Accepted 7 September 2020

Available online 25 September 2020

2211-7539/© 2020 Published by Elsevier B.V. on behalf of International Society for Human and Animal Mycology. This is an open access article under the CC

BY-NC-ND license (<http://creativecommons.org/licenses/by-nc-nd/4.0/>).

no growth was observed at 37 °C. A subculture on potato dextrose agar was performed from the initial colony and incubated at 25 °C. On day 21, pale-brown single-celled conidia with a clear brightly opalescent equatorial ring were observed under the microscope. Conidia were sympodially generated and large cluster-aggregated conidiogenous cells suggesting *Arthrinium* sp. (Fig. 1C). A second and a third collection of nail material was performed on day 30 and day 60, cultured on Sabouraud dextrose agar for seven days at 25 °C. The results confirmed the genus as the cause of the onychomycosis. For species identification of the first culture, the sequencing of Internal Transcribed Spacer (ITS) of rDNA using primers ITS 5 and 4 and part of the Translation Elongation Factor 1-alpha (TEF1- α) gene using primers EF1-728F and EF-2 were performed and compared against the GenBank database using the BLAST algorithm (www.ncbi.nlm.nih.gov/blast). These sequences showed 99.47% identity and 100% of coverage with strain *Arthrinium arundinis* CBS 106.12 (access number being MK539828 and MT622850). Eleven clinical antifungals (Sigma-Aldrich, USA) were evaluating according to the protocol M38-A2 of the Clinical and Laboratory Standards Institute (CLSI), using the microdilution technique and the inoculum was standardized to 2×10^4 CFU/mL in test [9].

The caspofungin minimal effective concentration (MEC) was evaluated, and for the other antifungals, the minimal inhibitory concentrations (MICs) was considered when no growth was visually observed. Excepting terbinafine, amphotericin B and posaconazole, the isolate had higher MICs and MEC for all other antifungals tested (Table 1). We decided for a conservative treatment with chemical abrasion, instructing the patient to gently sand the altered areas of the nails, and apply a 40% urea solution on the nail plate, once a week, associated with the daily use of terbinafine 1% cream. The patient is still in follow-up and reviewed monthly showing slight improvements in 3 months of treatment.

Table 1

Antifungal susceptibility testing results of *Arthrinium arundinis* isolated from the nail scrapings in a leprosy patient.

Antifungal	Minimal Inhibitory Concentrations (MICs) and Minimal Effective Concentration (MEC) ^a (µg/mL)
Terbinafine	0.0312
Amphotericin B	0.5
Posaconazole	1
Ketoconazole	8
Cyclopirox	8
Olamine	
Tioconazole	16
Voriconazole	16
Itraconazole	>16
Caspofungin ^a	>16
Fluconazole	>64
Griseofulvin	>64

^a MEC evaluation.

3. Discussion

Onychomycosis is the most common nail disease and has a prevalence of 5.5% in the world population [1]. Around 60%–70% of these infections can be caused by dermatophyte fungi. Yeasts are responsible for 10%–20% of cases, and the NDFF represent 10%–20% of fungal nail infections [1,4]. Some NDFF can cause nail infections directly, others can secondarily infect nails with minor trauma, but often these fungi are only local contaminants [2].

The genus *Arthrinium* (family Apiosporaceae) comprises a group of NDFF, geographically widely distributed, commonly saprobes, but also parasites of a large number of plant species [10,11]. Until now, 70 species of *Arthrinium* fungi have been reported and they are, generally,

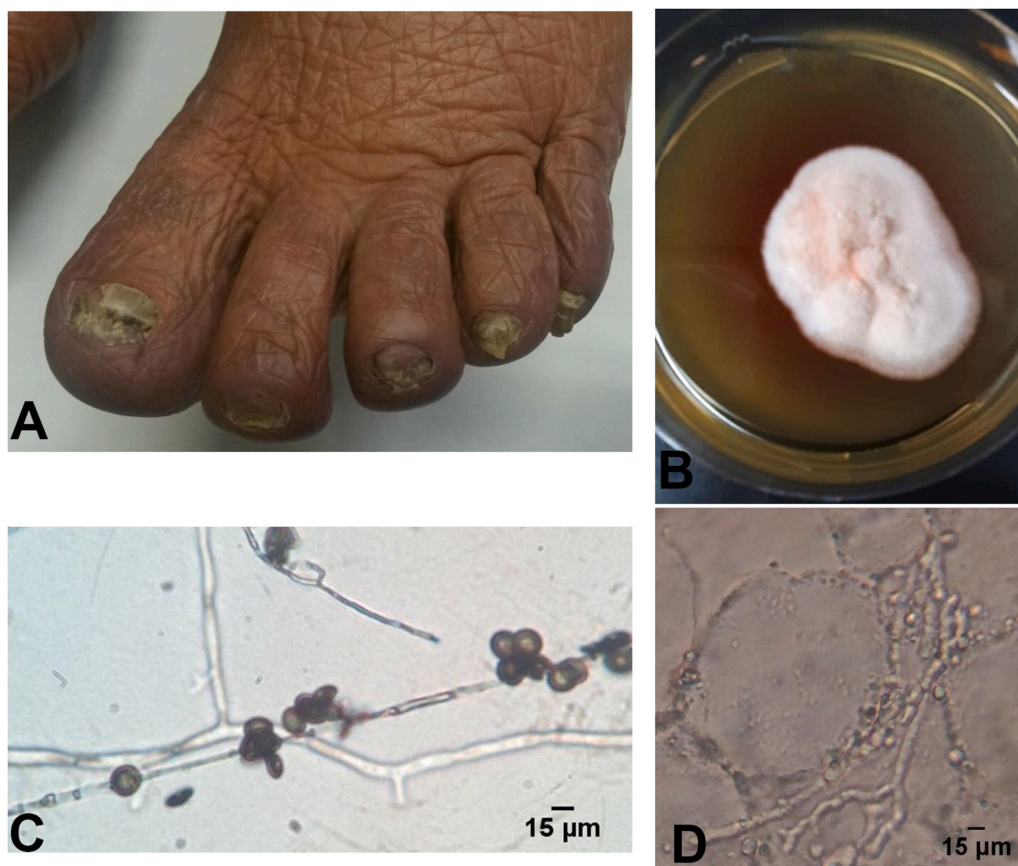


Fig. 1. Onychomycosis caused by *Arthrinium aurundinis* in leprosy patient (A); *Arthrinium arundinis* colony in Sabouraud agar plate after 7 days (B); Microculture in potato dextrose agar at 25 °C after 7 days, 400x (C); Direct mycological examination, 400x(D).

not implicated in human or animal disease [11]. However, two skin infection cases in humans caused by *Arthrimum phaeospermum* [12,13] and one case of onychomycosis caused by *A. arundinis* have already been described [7].

Pardo-Castello and Pardo [14] observed the presence of onychomycosis in 20%–30% of leprosy patients. Leprosy patients tend to have nail changes and onychomycosis more frequently than the general population, mainly due to the frequent trauma resulting from peripheral neural impairment caused by *Mycobacterium leprae* during its infectious process [15], which may favor the infection of NDFF.

The laboratory diagnosis of NDFF onychomycosis is not simple, and there is no standard criterion for the diagnosis. In the present case, to reduce the chances of NDFF being a contaminant, the following criteria were used: the identification of irregular hyphae in the direct mycological examination of the nail scraping of three consecutive collections with intervals of one month between each one; obtaining three positive cultures on Sabouraud dextrose agar in the three different collections; and the failure to obtain dermatophyte fungi isolation in cultures of the same nail material on Mycosel® agar [2,4]. For species identification, it was performed the sequencing of ITS and TEF1- α fungus genes [7,16].

There is no standard treatment protocol described for NDFF onychomycosis. Gupta et al. [4] described efficient treatments using oral terbinafine or itraconazole for *Scopulariopsis brevicaulis* and *Aspergillus* species. The efficacy in the topical use of terbinafine, after chemical avulsion, is described in 2 cases of onychomycosis caused by *Acremonium* species [4]. Pulsed terbinafine promoted complete cure in 30 of 34 cases of *Aspergillus* onychomycosis according to Gupta et al. [4]. Regarding *Scopulariopsis* species, 24 out of 32 cases were successfully treated with pulsed itraconazole, where 12 out of 14 cases improved with daily use of terbinafine 250 mg.

Tosti et al. [17], reported 59 cases of NDFF onychomycosis. The authors obtained better results when using topical treatments compared to systemic treatments. Sixteen patients with onychomycosis caused by *S. brevicaulis* were treated with ciclopirox 8% nail lacquer or topical terbinafine (for 8–12 months) after nail avulsion, and 11 patients were successful healed.

The first reported case of *A. arundinis* as causing onychomycosis was resistant to fluconazole and caspofungin, and susceptible to itraconazole, voriconazole and posaconazole [7]. However, in the present case, the isolate was susceptible to amphotericin B and was not susceptible to itraconazole, results contrary to those obtained by the first published case report. Thus, evaluations of superficial mycoses, identification and antifungal susceptibility testing are important to guide management [1–5].

The first reported case of onychomycosis caused by *A. arundinis* was successfully carried out in the treatment with pulsed itraconazole [7]. However, in our case, the isolated fungus from the leprosy patient showed a MIC higher than 16 $\mu\text{g/mL}$, which classifies our isolate as resistant to this drug. The low terbinafine MIC obtained in vitro suggested the use of this drug for the onychomycosis treatment. The oral terbinafine administration in this patient was not adequate due the presented comorbidities. The use of this drug systemically could worsen anemia and visual impairment, in addition to the possible drug interaction with the medication administered to the patient for the treatment of her comorbidities. Due to the reported factors, we chose a

conservative topical terbinafine treatment twice a day, and monthly clinical follow-up. We plan to maintain exclusively topical treatment until the end of leprosy treatment in approximately 6 months, if no improvement is obtained, we will start a monitored oral terbinafine treatment.

Declaration of competing interest

There are none.

Acknowledgements

The authors thank CAPES (Coordenação de Aperfeiçoamento de Pessoal de Nível Superior) Danielle Machado Pagani - CAPES1693871) for the scholarships.

References

- [1] S.R. Lipner, R.K. Scher Onychomycosis, Clinical overview and diagnosis, *J. Am. Acad. Dermatol.* 80 (2019) 835–851, <https://doi.org/10.1016/j.jaad.2018.03.062>.
- [2] M.R. Straten, M.M. Balkis, M.A. Ghannoum, The role of nondermatophyte molds in onychomycosis: diagnosis and treatment, *Dermatol. Ther.* 15 (2002) 89–98, <https://doi.org/10.1046/j.1529-8019.2002.01522.x>.
- [3] E.O. Martínez-Herrera, S. Arroyo-Camarena, D.L. Tejeda-García, C.F. Porras-Lopez, R. Arenas, Onychomycosis due to opportunistic molds, *An. Bras. Dermatol.* 90 (2015) 334–337, <https://doi.org/10.1590/abd1806-4841.20153521>.
- [4] A.K. Gupta, C. Drummond-Main, E.A. Cooper, W. Brintnell, B.M. Piraccini, A. Tosti, Systematic review of nondermatophyte mold onychomycosis: diagnosis, clinical types, epidemiology, and treatment, *J. Am. Acad. Dermatol.* 66 (2011) 494–502, <https://doi.org/10.1016/j.jaad.2011.02.038>.
- [5] A. Shemer, B. Davidovici, M.H. Grunwald, H. Trau, B. Amichai, New criteria for the laboratory diagnosis of nondermatophyte moulds in onychomycosis, *Br. J. Dermatol.* 160 (2009) 37–39, <https://doi.org/10.1111/j.1365-2133.2008.08805.x>.
- [6] S.R. Lipner, R.K. Scher, Onychomycosis Treatment and prevention of recurrence, *J. Am. Acad. Dermatol.* 80 (2019) 853–867, <https://doi.org/10.1016/j.jaad.2018.05.1260>.
- [7] M. Dylag, A. Hryniewicz-Gwózdź, T. Jagielski, Onychomycosis due to *Arthrimum arundinis*: a case report, *Acta Derm. Venereol.* 97 (2017) 860–861, <https://doi.org/10.2340/00015555-2673>.
- [8] Guidelines for the diagnosis, Treatment and Prevention of Leprosy, World Health Organization, Regional Office for South-East Asia, New Delhi, 2017. Licence: CC BY-NC-SA 3.0 IGO.
- [9] Clinical and Laboratory Standards Institute (CLSI), Reference Method for Broth Dilution Antifungal Susceptibility Testing of Filamentous Fungi, second ed., Clinical and Laboratory Standards Institute (CLSI), Wayne, PA, 2008. Approved Standard M38-A2.
- [10] P.W. Crous, J.Z. Groenewald, A phylogenetic re-evaluation of *Arthrimum*, *IMA fungus* 4 (2013) 133–154, <https://doi.org/10.5598/ima fungus.2013.04.01.13>.
- [11] M. Wang, X.-M. Tan, F. Liu, L. Cai, Eight new *Arthrimum* species from China, *MycKeys* 34 (2018) 1–24, <https://doi.org/10.3897/mycokeys.34.24221>.
- [12] M.K. Rai, Mycosis in man due to *Arthrimum phaeospermum* var. *indicum*. First case report, *Mycoses* 32 (1989) 472–475, <https://doi.org/10.1111/j.1439-0507.1989.tb02285.x>.
- [13] Y.M. Zhao, C.R. Deng, X. Chen, *Arthrimum phaeospermum* causing dermatomycosis, a new record of China, *Acta Mycol. Sin.* 9 (1990) 232–235, <https://doi.org/10.3897/mycokeys.34.24221>.
- [14] V. Pardo-Castell, O.A. Pardo, *Disease of the Nails*, third ed., Charles C Thomas Publishers, Springfield, 1960.
- [15] I.B. Romero, J.M.R. Rincón, F.R. Rabell, Nail involvement in leprosy, *Acta Dermosifiliogr* 103 (2012) 276–284, <https://doi.org/10.1016/j.ad.2011.07.011>.
- [16] S. Greven, F. Egberts, M. Buchner, V. Beck-Jendroschek, K. Voss, J. Brasch. Cutaneous chromomycosis caused by *Arthrimum arundinis*, *J. Dtsch Dermatol. Ges.* 16 (2018) 621–623, <https://doi.org/10.1111/ddg.13507>.
- [17] A. Tosti, B.M. Piraccini, S. Lorenzi, Onychomycosis caused by nondermatophytic molds: clinical features and response to treatment of 59 cases, *J. Am. Acad. Dermatol.* 42 (2000) 217–224, [https://doi.org/10.1016/S0190-9622\(00\)90129-4](https://doi.org/10.1016/S0190-9622(00)90129-4).