

## X-RADIATION DOES NOT AFFECT THE DENTAL PULP: A MORPHOLOGICAL STUDY IN RATS

A radiação X não afeta a polpa dentária: um estudo morfológico em ratos

 Rafaela Argento<sup>a</sup>,  Isadora Luana Flores<sup>b</sup>,  Grazielle Oliveira Stelter<sup>c</sup>,  Thiago Oliveira Gamba<sup>d</sup>,  
 Solange Maria de Almeida Boscolo<sup>e</sup>,  Gláucia Maria Bovi Ambrosano<sup>e</sup>

### ABSTRACT

**Introduction:** Radiotherapy is one of the methods used as a treatment for malignant tumors in the head and neck region and it can cause tissue damage in the irradiated areas. In head and neck radiotherapy, teeth are often included within the irradiation area and, consequently, the dental pulp; which receives high doses of radiation.

**Objective:** To evaluate the effects of ionizing radiation on the pulp tissue of rat teeth. **Methodology:** A double-blind experimental assay with 35 *Albinus Wistar* rats divided into seven groups was performed; one control group, three groups irradiated with 15 Gy, and three groups irradiated with 25 Gy. The irradiated groups were submitted to a single dose of radiation and sacrificed 24 hours, 7 days, and 22 days after irradiation, respectively. The samples were evaluated for the morphological presence of inflammatory infiltrate, edema, necrosis, fibrosis, and degeneration of blood vessels. Statistical analysis was performed using the Kruskal-Wallis and Dunn tests with  $p < 0.05$ . **Results:** Hyaline degeneration of the pulp blood vessels in the irradiated teeth was statistically significant in all irradiated groups. Inflammatory infiltrate, edema, necrosis or fibrosis was not observed. **Conclusion:** A single X-radiation dose is not able to affect the dental pulp connective tissue in the long term with no clinical damage.

**Keywords:** Dental pulp. Pulpitis. Dental pulp necrosis. X-Ray therapy. Squamous cell carcinoma of head and neck.

### RESUMO

**Introdução:** A radioterapia é um dos métodos utilizados como tratamento para tumores malignos em região de cabeça e pescoço e que pode causar danos aos tecidos nas áreas irradiadas. Na radioterapia de cabeça e pescoço, os dentes são comumente incluídos dentro da área de radiação e, conseqüentemente, a polpa dentária, recebe altas doses de radiação. **Objetivo:** Avaliar os efeitos da radiação ionizante no tecido pulpar de dentes de ratos.

**Metodologia:** Foi realizado um ensaio experimental duplo-cego com 35 ratos *Albinus Wistar* divididos em sete grupos: um grupo controle, três grupos irradiados com 15 Gy e três grupos irradiados com 25 Gy. Os grupos irradiados foram submetidos a uma dose única de radiação e sacrificados 24 horas, 7 dias e 22 dias após a irradiação, respectivamente. As amostras foram avaliadas quanto à presença morfológica de infiltrado inflamatório, edema, necrose, fibrose e degeneração nos vasos sanguíneos. A análise estatística foi realizada por meio dos testes de Kruskal-Wallis e Dunn com  $p < 0.05$ . **Resultados:** Degeneração hialina nos vasos sanguíneos pulpares dos dentes irradiados foi estatisticamente significativa em todos os grupos irradiados. Não foi observado infiltrado inflamatório, edema, necrose ou fibrose. **Conclusão:** Uma dose única de radiação X não é capaz de afetar o tecido conjuntivo da polpa dentária a longo prazo sem danos clínicos.

**Palavras-chave:** Polpa dentária. Pulpite. Necrose da polpa dentária. Terapia por raios X. Carcinoma de células escamosas de cabeça e pescoço.

<sup>a</sup>DDS, MSc - Department of Oral Diagnosis – Oral Radiology, Piracicaba Dental School, State University of Campinas, Piracicaba, SP, Brazil.

<sup>b</sup>DDS, MSc, PhD - Adjunct Professor in Oral Pathology, School of Dentistry, Federal University of Rio Grande do Sul, Porto Alegre, RS, Brazil.

<sup>c</sup>Undergraduate Student, School of Dentistry, Federal University of Rio Grande do Sul, Porto Alegre, RS, Brazil.

<sup>d</sup>DDS, MSc, PhD, Professor in Oral Radiology, School of Dentistry, Caxias do Sul University, Caxias do Sul, RS, Brazil.

<sup>e</sup>DDS, MSc, PhD - Department of Oral Diagnosis – Oral Radiology, Piracicaba Dental School, State University of Campinas, Piracicaba, SP, Brazil.

**Corresponding author:** Dr. Isadora Luana Flores - Email: isadoraluanaflores@gmail.com

**Received:** 03/06/2020 | **Accepted:** 20/08/2020

## INTRODUCTION

Head and neck squamous cell carcinoma (SCC) is one of the most common types of cancer in many parts of the world and it is associated with significant morbidity due to late diagnosis and, consequently, the established modality treatment<sup>1</sup>. Currently, the combination of surgery, radiotherapy, and chemotherapy is recommended for better local and regional control of tumor growth<sup>2</sup>. However, head and neck radiotherapy is associated with a series of acute and chronic toxicities on the tissues of the oral cavity due to the involvement of both the tumor component and the normal anatomical structures of the maxillofacial region in the primary radiation field<sup>3-5</sup>. In this context, teeth are also commonly present in the irradiated area during the treatment of head and neck tumors, and consequently; the tooth pulp, a loose connective tissue rich in vessels and nerves, receives high doses of radiation<sup>2-6</sup>.

The effects of ionizing radiation, such as transient or permanent changes in micro-circulation and pulp innervation related to changes in pulp sensitivity have been previously reported<sup>6</sup>. In addition, some recent studies have also suggested the possible radiogenic destruction of the pulp as an important event for the etiology of caries related to radiation<sup>6</sup>. However, the absence of morphological changes in the pulp tissue as a direct result of radiotherapy has also been pointed out<sup>7</sup>.

Therefore, due to the lack of a consensus in the literature and contradictory results<sup>2,7-14</sup>, we aim to evaluate the effects of ionizing radiation on the pulp tissue of rat teeth using an animal model to verify the direct effects of radiation therapy on the dental pulp morphology exclusively.

## MATERIAL AND METHODS

The research project was approved by the Ethics Committee on the Use of Animals of the State University of Campinas, Brazil with protocol no. 2998-1. All procedures performed in the present study involving animals were in accordance with the ethical standards of the institution or practice at which the study was conducted. A sample of 35 male 12-week-old *Albinus Wistar* rats were kept in polycarbonate cages in groups of five animals in controlled temperature and humidity environments with periods of 12 hours clarity and 12 hours darkness with the appropriate feed and water *ad libitum*. The animals were divided into seven groups (n = 5). Group A was not irradiated and constituted the control group. Groups B, C, and D received a single dose of 15 Gy of X-radiation and groups E, F, and G received a single dose of 25 Gy of X-radiation<sup>15</sup>. Prior to irradiation, we intramuscularly administered anesthesia with 80 mg/kg of Ketamine Hydrochloride (Dopalen®, Agribands do Brasil Ltda., Paulínia, SP, Brazil) and 8 mg/kg of Xylazine Hydrochloride (Rompum®, Bayer SA, São Paulo, SP, Brazil).

Animals in the irradiated groups B, C, and D received a single dose of 15 Gy of X-radiation from a linear patient accelerator (Clinac 6/100®, Varian Medical Systems, Palo Alto, CA, USA) with 6 MeVat a distance focal length of 100 cm. Animals in groups E, F, and G underwent the same procedure, but received a single dose of 25 Gy. The beam was collimated to restrict irradiation to the head and neck region (area of 15 X 30 cm). No secondary collimation was used. The animal irradiation protocol was adapted as from Ramos-Perez et al.<sup>15</sup>. Animals in the control group and in the irradiated groups were sacrificed by anesthetic deepening at 24 hours, 7 days, and 22 days after irradiation. Animals in the control group were sacrificed together with the first irradiated group.

The mandibles were dissected and stored in 10% buffered formalin solution for at least one month in identified containers. The right hemi-mandibles were processed and embedded in Paraplast Plus: Tissue Embedding Medium (McCormick™ Scientific, Leica Biosystems, St.

Louis, MO, USA), and subsequently sectioned in cross sections of 7  $\mu\text{m}$  thickness using a Leica RM 2155 microtome (Leica, Wetzlar, Germany). Six slides were prepared with three slices of 5  $\mu\text{m}$  each, totaling 42 slides, which were stained with hematoxylin and eosin, and assembled in Canada balsam. The most representative cut showing the three lower molar teeth with the coronal and root portion and without processing artifacts was chosen for analysis.

The slides were morphologically analyzed in an optical microscope (Carl Zeiss Microscopy GmbH, Axio Lab, Jena, Germany) by two oral pathologists (MRV and ILF) who evaluated the presence of the following pathological changes: inflammatory infiltrate, edema, necrosis, fibrosis, and degeneration of blood vessels<sup>2,16</sup>. The investigators were blinded to the origin of the slides, either belonging to the control or irradiated groups. Qualitative and quantitative descriptive statistical analyses of the morphological changes and nonparametric tests of Kruskal-Wallis and Dunn were performed. The Kappa (k) test was used to assess inter-observer and intra-observer agreement using SPSS for Windows (SPSS IncVersion 21.0, Chicago, IL, USA)<sup>17</sup>.

## RESULTS

Both intra-observer and inter-observer reproducibility to repeated measures showed a perfect concordance of  $k = 1$ . No degeneration was observed in pulp blood vessels of the control group (Figure 1).

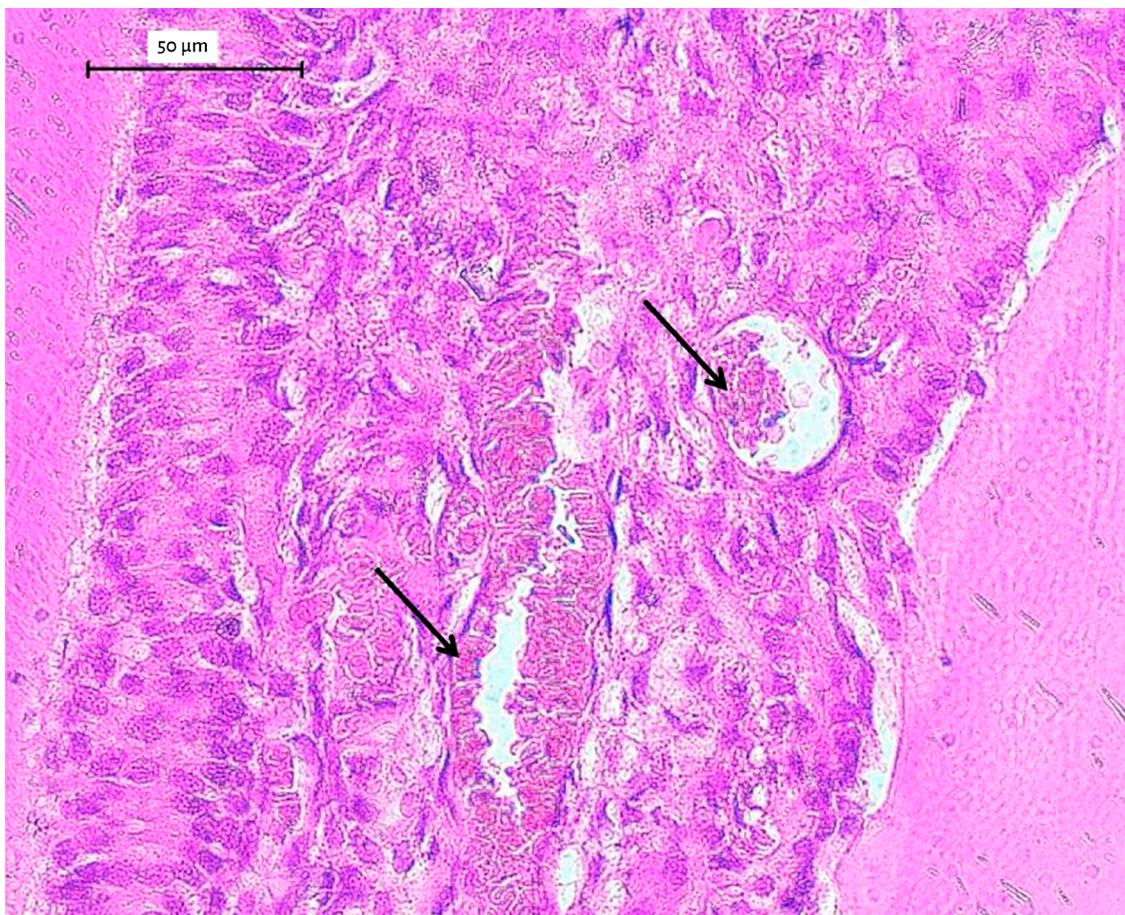

Figure 1: Control group. Normal tissue pulp with no degeneration and inflammatory signs. Note the hyperemic aspect in the coronal pulp of right inferior first molar of *Albinus Wistar* rat (black arrows). H&E, 40X magnification.

Similar hyaline degeneration of pulp blood vessels was observed in 100% of the irradiated animals (Groups B, C, D, E, F, and G) at both doses of 15 Gy and 25 Gy at sacrifice (24 hours, 7 days, and 22 days post irradiation, except G group; Figures 2 and 3, Table 1). Animals in Group G did not survive more than 10 days and findings were considered inside this period. Hyperemic blood vessels were found less frequently in the control animals ( $p < 0.05$ ; Figure 1, Table 2).

No significant inflammatory infiltrate, edema, necrosis or fibrosis were observed, irrespective of dose and sacrifice time, with no difference between the control and irradiated groups (Table 1).

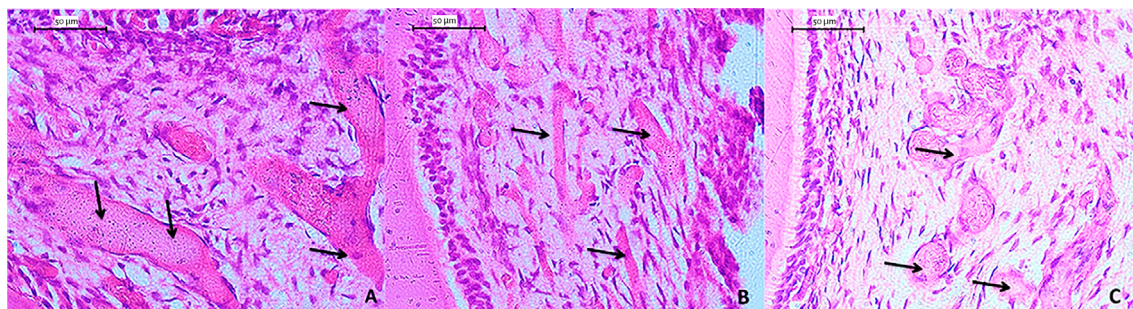


Figure 2: 15 Gy irradiation group. Hyaline degeneration of pulp blood vessels (black arrows), 24 hours (A), 7 days (B) and 22 days (C), respectively, in the coronal pulp (A) and (C) and in the radicular pulp (B) of right inferior first molar of *Albinus Wistar* rats. H&E, 40X magnification.

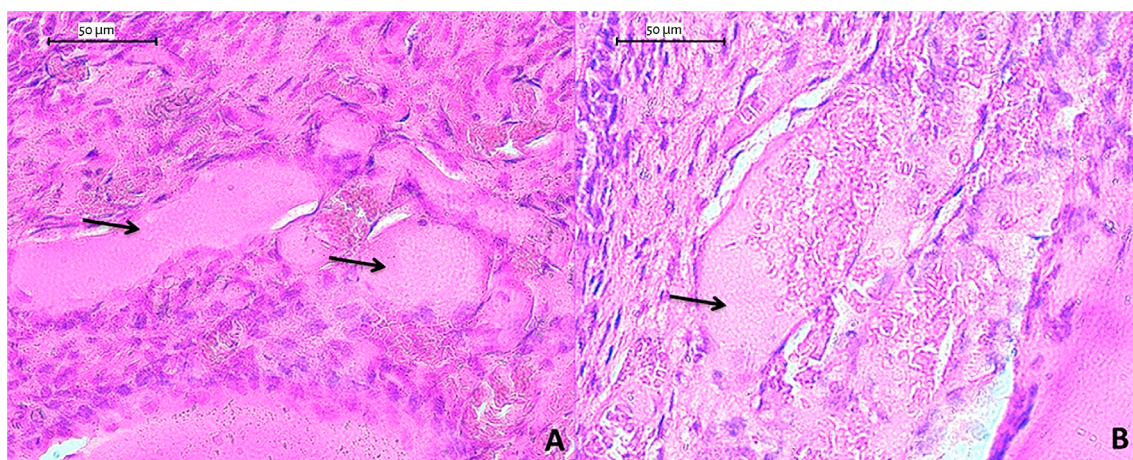


Figure 3: 25 Gy irradiation group. Hyaline degeneration of pulp blood vessels (black arrows), 24 hours (A) and 7 days (B), in the coronal and radicular pulp, respectively, of right inferior first molar of *Albinus Wistar* rats. H&E, 100X magnification.

Table 1: *Albinus Wistar* percentage with pulp pathological findings after head and neck irradiation observed under optical microscopy.

	† Groups					
	A	B	C	D	E	F
<b>Hyaline degeneration</b>	0%	100%	100%	100%	100%	100%
<b>Inflammatory infiltrate</b>	0%	0%	0%	0%	0%	0%
<b>Edema</b>	0%	0%	0%	0%	0%	0%
<b>Necrosis</b>	0%	0%	0%	0%	0%	0%
<b>Fibrosis</b>	0%	0%	0%	0%	0%	0%

† Group A – Control; groups B, C, D (15 Gy, 24 hours, 7 days and 22 days after irradiation, respectively); Groups E and F (25 Gy, 24 hours and 7 days after irradiation, respectively).

Table 2: Slides percentage (median, minimum and maximum value) of hyperemic blood vessels per group of irradiated *Albinus Wistar*.

Group	† Evaluation time	Median	Minimum	Maximum
<b>Control</b>	-	33.3% b	0%	33.3%
<b>15 Gy</b>	24 hours	100% a	100%	100%
	7 days	100% a	100%	100%
	22 days	100% a	100%	100%
<b>25 Gy</b>	24 days	100% a	100%	100%
	7 days	100% a	100%	100%
	22 days	-	-	-

† Sacrifice time after irradiation. Median followed by different letters differs from each other ( $p \leq 0.05$ ).

## DISCUSSION

The negative response to the pulp sensitivity test may be indicative of necrosis or decreased pulp blood flow with ionizing radiation as an inductive agent<sup>6,11,12,16,18,19</sup>. However, studies demonstrating direct effects of ionizing radiation on the dental pulp are still scarce in the English literature<sup>2</sup>.

It is known radiation can induce changes in the dental pulp, a delicate connective tissue with moderate sensitivity to radiation<sup>16</sup>. In the present study, hyaline degeneration of the pulp blood vessels was observed. This event is a consequence of endothelial injury originating from a leakage of plasma proteins through damaged endothelial cells in the vascular wall<sup>16</sup>. This alteration, when extensive, contributes to the obliteration of capillary lumens, and causes an impaired blood supply which results in localized malnutrition, decreased oxygenation, and, loss of pulp sensitivity<sup>16</sup>. However, the clinical significance of hyaline degeneration is not stated in the literature.

These vascular changes were observed in the coronal and root pulp teeth of irradiated rats but not in animals of the control group. Previous studies have already seen pulp changes such as thickening of blood vessel walls, occasional degeneration of connective tissue and odontoblasts, and subtle changes in the walls of the pulp blood vessels<sup>8,12</sup>. Nevertheless, in another similar study with rats, inflammation and pulp hyalinization were not observed with the presence of vascular congestion<sup>2</sup>. It should be noted the radiation dose in this study was lower with 12 Gy and 18 Gy, and that different experimental designs may generate contradictory results.

In view of our findings, we believe hyalinization of blood vessels can cause decreasing blood flow and, consequently, transient loss of pulp sensitivity as an immediate event after radiotherapy<sup>12</sup>. Thus, patients submitted to head and neck radiotherapy might present a higher number of teeth with a negative response to the pulp sensitivity test<sup>6,11,18,19</sup>. However, around 75% of the blood flow can be reestablished in the irradiated field within one year after radiotherapy. Therefore, the decrease in pulp sensitivity can be considered as a speculated transient event due to changes in the microcirculation with no late clinical effects<sup>6,12,15,20-22</sup>.

In the present study, vascular alteration was found at 24 hours, 7 days, and 22 days after irradiation, and long-term studies to investigate the progressive events may further illuminate radiation effects on pulp patterns. Meanwhile, it should be noted that animal models have presented the limitation of experimental design due to the need for prior anesthesia of the animals for irradiation and follow-up. This condition renders the animals more susceptible to death. Moreover, the teeth of research animals were healthy, and this may be one reason why no inflammatory changes were observed in the pulp in this and in other studies<sup>9,10,16,17</sup>. Also, the hyperemic vessels were clearly seen in the control group; a frequent and completely reversible event at initial pulp aggression with no quite relevant clinical findings. Interestingly, inflammatory changes, edema, necrosis or fibrosis were not triggered by radiation in the dental pulp. Histological sections were meticulously investigated under optical microscopy.

## CONCLUSION

Despite the interest of the clinical context to the field; the pathological and clinical significance of hyaline degeneration is still obscured. Nonetheless, the absence of necrosis areas or inflammatory infiltrate could be considered the major data brought by the study because this morphological maintenance suggests a single X-radiation dose is not able to affect the dental pulp connective tissue in the long term.

## ACKNOWLEDGMENTS

We thank full professor Mário Roberto Vizioli of University of Campinas for the contribution in the microscopical analysis and his work in the field of oral pathology during his academic life before retirement.

## CONFLICT OF INTEREST

The authors declare that they have no conflict of interest.

## REFERENCES

- Awasthi N. Role of salivary biomarkers in early detection of oral squamous cell carcinoma. *Indian J Pathol Microbiol.* 2017 Oct-Dec;60(4):464-8.
- Madani ZS, Azarakhsh S, Shakib PA, Karimi M. Histopathological changes in dental pulp of rats following radiotherapy. *Dent Res J (Isfahan).* 2017 Jan-Feb;14(1):19-24.
- Ahmed M, Hansen VN, Harrington KJ, Nutting CM. Reducing the risk of xerostomia and mandibular osteoradionecrosis: the potential benefits of intensity modulated radiotherapy in advanced oral cavity carcinoma. *Med Dosim.* 2009;34(3):217-24.
- Lee IJ, Koom WS, Lee CG, Kim YB, Yoo SW, Keum KC, et al. Risk factors and dose-effect relationship for mandibular osteoradionecrosis in oral and oropharyngeal cancer patients. *Int J Radiat Oncol Biol Phys.* 2009 Nov 15;75(4):1084-91.
- Hong CH, Napeñas JJ, Hodgson BD, Stokman MA, Mathers-Stauffner V, Elting LS, et al. A systematic review of dental disease in patients undergoing cancer therapy. *Support Care Cancer.* 2010 Aug;18(8):1007-21.
- Kataoka SH, Setzer FC, Fregnani ER, Pessoa OF, Gondim E Jr, Caldeira CL. Effects of 3-dimensional conformal or intensity-modulated radiotherapy on dental pulp sensitivity during and after the treatment of oral or oropharyngeal malignancies. *J Endod.* 2012 Feb;38(2):148-52.
- Faria KM, Brandão TB, Ribeiro AC, Vasconcellos AF, de Carvalho IT, de Arruda FF, et al. Micromorphology of the dental pulp is highly preserved in cancer patients who underwent head and neck radiotherapy. *J Endod.* 2014 Oct;40(10):1553-9.
- Meyer I, Shklar G, Turner J. A comparison of the effects of 200 kv. Radiation and cobalt-60 radiation on the jaws and dental structure of the white rat. A preliminary report. *Oral Surg Oral Med Oral Pathol.* 1962 Sep;15:1098-108.
- Hutton MF, Patterson SS, Mitchell DF, Chalian VA, Hornback NB. The effect of cobalt-60 radiation on the dental pulps of monkeys. *Oral Surg Oral Med Oral Pathol.* 1974 Aug;38(2):279-86.
- Fawzi MI, Shklar G, Krakow AA. The effect of radiation on the response of dental pulp to operative and endodontic procedures: an experimental study. *Oral Surg Oral Med Oral Pathol.* 1985 Apr;59(4):405-13.
- Anneroth G, Holm LE, Karlsson G. The effect of radiation on teeth: a clinical, histologic and microradiographic study. *Int J Oral Surg.* 1985 Jun;14(3):269-74.
- Knowles JC, Chalian VA, Shidnia H. Pulp innervation after radiation therapy. *J Prosthet Dent.* 1986 Dec;56(6):708-11.
- Springer IN, Niehoff P, Warnke PH, Böcek G, Kovács G, Suhr M, et al. Radiation caries--radiogenic destruction of dental collagen. *Oral Oncol.* 2005 Aug;41(7):723-28.
- Gomes-Silva W, Prado-Ribeiro AC, Brandão TB, Morais-Faria K, de Castro Junior G, Mak MP, et al. Postradiation matrix metalloproteinase-20 expression and its impact on dental micromorphology and radiation related caries. *Caries Res.* 2017;51(3):216-24.
- De Moraes Ramos-Perez FM, do Espírito Santo AR, da Cruz Perez DE, Novaes PD, Bóscolo FN, Line SR, et al. Ionizing radiation effects on the secretory-stage ameloblasts and enamel organic extracellular matrix. *Radiat Environ Biophys.* 2014 Aug;53(3):589-98.
- Vier-Pelisser FV, Figueiredo MA, Cherubini K, Braga Filho A, Figueiredo JA. The effect of head-fractionated teletherapy on pulp tissue. *Int Endod J.* 2007 Nov;40(11):859-65.
- Fleiss JL, Levin B, Paik MC. *Statistical methods proportions.* 3th ed. Hoboken: Wiley; 2003.
- Kataoka SH, Setzer FC, Gondim-Junior E, Pessoa OF, Gavini G, Caldeira CL. Pulp vitality in patients with intraoral and oropharyngeal malignant tumors undergoing radiation therapy assessed by pulse oximetry. *J Endod.* 2011 Sep;37(9):1197-200.
- Garg H, Grewal MS, Rawat S, Suhag A, Sood PB, Grewal S, et al. Dental pulp status of posterior teeth in patients with oral and oropharyngeal cancer treated with concurrent chemoradiotherapy. *J Endod.* 2015 Nov;41(11):1830-33.
- Kataoka SH, Setzer FC, Gondim-Junior E, Fregnani ER, Moraes CJ, Pessoa OF, et al. Late effects of head and neck radiotherapy on pulp vitality assessed by pulse oximetry. *J Endod.* 2016 Jun;42(6):886-89.
- Cooper JS, Fu K, Marks J, Silverman S. Late effects of radiation therapy in the head and neck region. *Int J Radiat Oncol Biol Phys.* 1995 Mar 30;31(5):1141-64.
- Niehoff P, Springer IN, Açil Y, Lange A, Marget M, Roldán JC, et al. HDR brachytherapy irradiation of the jaw - as a new experimental model of radiogenic bone damage. *J Craniomaxillofac Surg.* 2008 Jun;36(4):203-9.