

## EFFECTS OF A MUCOADHESIVE FORMULATION CONTAINING *CURCUMA LONGA* L. ON ORAL WOUND HEALING

Chris Krebs Danilevicz<sup>1,2</sup>, Vivian Petersen Wagner<sup>1,3</sup>,  
Liana Preto Webber<sup>1</sup>, Tuany Rafaeli Schmidt<sup>1</sup>,  
Ellen Cristine Pineze Alonso<sup>4</sup>, Elismauro Francisco de Mendonça<sup>3,5</sup>,  
Marize Campos Valadares<sup>6</sup>, Ricardo Neves Marreto<sup>4</sup>,  
Manoela Domingues Martins<sup>1,3,7</sup>

### ABSTRACT

**Introduction:** The aim of this study was to investigate the effects of a topical mucoadhesive formulation with *Curcuma longa* L. extract (MFC) on oral wound healing.

**Methods:** Seventy-two Wistar rats were randomly assigned to 3 groups: Control, Vehicle, and MFC. Traumatic ulcers were made on the dorsum of the tongue with a 3-mm diameter punch. Vehicle and MFC groups received application of the products twice a day, while animals in the control group were cared for in identical conditions but received no product application. Six rats in each group were euthanized at days 3, 5, 10, and 14. Percentage of repair was calculated based on wound area. HE-stained histological sections were obtained for semi-quantitative analysis of re-epithelization and inflammation.

**Results:** Clinical findings revealed that at days 3 and 5, animals from the MFC group exhibited a significantly higher percentage of wound repair. At day 5, animals from this group also demonstrated a significant increase in the degree of re-epithelization and inflammation.

**Conclusions:** MFC is capable of accelerating oral wound repair in an *in vivo* model by modulating the inflammatory process and stimulating epithelial proliferation.

**Keywords:** *Curcumin; turmeric extract; curcuminoid; phytotherapy; phytomedicine.*

### INTRODUCTION

Oral ulcers are frequently seen in dental clinic and they may indicate the clinical manifestation of several local and systemic conditions. Among the most common types, traumatic ulcers and recurrent aphthous stomatitis are associated with symptoms such as pain and discomfort<sup>1</sup>. These lesions usually repair over a period of 7 to 10 days through the normal healing process, restoring the integrity of the tissue. Treatment protocols for oral ulcers aim at accelerating repair and relieving symptomatology, and the use of topical corticosteroids, such as dexamethasone and clobetasol, are the most prevalent. However, even the topical application of corticosteroids can lead to systemic adverse reactions if the drug is absorbed into the bloodstream<sup>2</sup>. Although in most cases the adverse effects are mild, there are reports of patients who developed Cushing's syndrome through the topical use of corticosteroids<sup>2,3</sup>. Thus, equally effective and safer treatment alternatives should be developed.

Natural products (phytotherapeutics) have been shown to be effective alternatives in the treatment of inflammatory diseases and induce the repair of lesions in different tissues<sup>2,4-6</sup>. The beneficial effects of herbal medicines

*Clin Biomed Res.* 2020;40(2):117-124

1 Department of Oral Pathology, School of Dentistry, Federal University of Rio Grande do Sul. Porto Alegre, RS, Brasil.

2 Department of Pharmacology, Institute of Basic Health Sciences, Federal University of Rio Grande do Sul. Porto Alegre, RS, Brasil.

3 Department of Oral Diagnosis, Piracicaba Dental School, University of Campinas. Piracicaba, SP, Brasil.

4 Laboratory of Nanosystems and Drug Delivery Devices (NanoSYS), School of Pharmacy, Federal University of Goiás. Goiânia, GO, Brasil.

5 Laboratory of Oral Pathology, School of Dentistry, Federal University of Goiás. Goiânia, GO, Brasil.

6 Laboratory of Pharmacology and Cellular Toxicology, Pharmacy Faculty, Federal University of Goiás. Goiânia, GO, Brasil.

7 Experimental Pathology Unit, Clinics Hospital of Porto Alegre, Federal University of Rio Grande do Sul. Porto Alegre, RS, Brasil.

#### Corresponding author:

Manoela Domingues Martins  
manomartins@gmail.com  
Department of Oral Pathology –  
School of Dentistry, Federal University  
of Rio Grande do Sul  
Rua Ramiro Barcelos, 2492/503.  
90035-003, Porto Alegre, RS, Brasil.

have been associated to the biological functions of substances such as alkaloids, triterpenes, and biomolecules that influence one or more stages of wound healing. Among medicinal plants, the root of *Curcuma longa* L, a species widely used in folk medicine, contains pharmacological properties that can be applicable in wound healing. This plant, also known as curcuma, earth saffron, Indian saffron, turmeric, or yellow ginger, has three main curcuminoids in its composition: curcumin, desmethoxycurcumin, and bisdesmethoxycurcumin<sup>7,8</sup>. Curcumin is the most active compound, and studies have shown that phenols and methoxy groups are responsible for its biological properties<sup>9,10</sup>. The medicinal use of curcuma, both topical and systemic, is based on its anti-inflammatory, anti-microbial, antimutagenic, anticancer, and antioxidant properties<sup>11,12</sup>.

Despite the important biological effects, curcumin has low bioavailability due to its high metabolism rate and poor absorption<sup>13</sup>. One of the methods used to overcome this limitation and ensure the effectiveness of its biological properties is to associate curcuma extracts with mucoadhesive drug delivery systems. These systems have the ability to adhere to the surface of epithelial cells or mucus layer, thereby prolonging the contact of the drug with the absorption/action site, increasing the local or systemic bioavailability of the drug<sup>14</sup>. Different studies have shown that the association of drugs to mucoadhesive compounds increases its bioavailability<sup>15,16</sup>. The beneficial effect of a mucoadhesive formulation with *Curcuma longa* L. (MFC) has been demonstrated in intestinal and oral mucositis<sup>17,18</sup>. Yet, the effect of MFC on the healing of conventional oral ulcers, which are extremely recurrent in clinical practice, remains completely unexplored. Experimental research carried out with Wistar rats is an efficient method to determine the efficacy of new extracts in accelerating wound healing. Therefore, the aim of this study was to evaluate the clinical and histopathological effect of a MFC in oral ulcers on Wistar rats.

## METHODS

The present study was approved by the Ethics Committee on the Use of Animals of the Porto Alegre Clinics Hospital, Brazil, under process number 14-0572. The experimental protocol followed the ethics principles in animal experiments, based on Law 11.794 of October 8, 2008 and the Brazilian Guideline for the Care and Use of Animals for Scientific and Educational Purposes of the National Council for Animal Experimentation Control.

### Design

This was a controlled and blind experiment.

### MFC preparation

The extract was prepared at the Laboratory of Nanosystems and Drug Delivery Devices (NanoSYS), School of Pharmacy, Federal University of Goiás (Goiânia, GO, Brazil). A commercial *Curcuma longa* L. extract was acquired from Gamma Comércio Importação & Exportação LTDA (São Paulo, Brazil), comprising of 96.4% (m/m) curcuminoids (curcumin, desmethoxycurcumin, and bisdesmethoxycurcumin). Transcutol HP® (diethylene glycol monoethyl ether) was generously donated by Gattefossé (Lyon, France). Propylene glycol and polyethylene glycol were obtained from Labsynt (Sao Paulo, Brazil). Poloxamer 407 and Soluplus® were obtained from Basf (Ludwigshafen, Germany).

The mucoadhesive component (poloxamer 407, 15%, w/v) was dispersed in an organic phase including a mixture of polyethylene glycol 400 (PEG 400) and propylene glycol, and kept under continuous magnetic stirring at 65°C. Next, the curcuminoids were added to the mixture and a final concentration of 20 mg/mL was obtained. Besides, an aqueous fraction was prepared by adding Transcutol HP®, Soluplus®, and two antioxidants (sodium metabisulfite and sodium bisulfite) to purified water under constant stirring. Then, the aqueous fraction was heated to 65°C and poured into the organic phase. The resulting mixture was maintained under continuous stirring for an additional 30 min. The pH was adjusted to 6.5 using citric acid solution (0.1 M). The curcuminoid content in the mucoadhesive formulation was determined spectrophotometrically ( $\lambda=425$  nm). The curcuminoids content was 102% of the expected theoretical value. A blank formulation (placebo) was prepared as described above by substituting the curcumin for an equal mass of PEG 400. The placebo formulation was also evaluated by spectrophotometric analysis, and its constituents showed no interference. The formulations were stored in amber flasks at room temperature until use.

### Animals

The sample size calculation, considering wound closure as primary outcome, was based on studies using a similar methodology<sup>19,20</sup> with a number of 6 animals per group per day of euthanasia. Seventy-two male rats (*Rattus norvegicus albinus*, Rodentia, Mammalia, Wistar strain) weighing between 270 and 370 g were used. The animals were housed individually in plastic boxes (40×30×16 cm), with standard chow and water ad libitum, at 22±2°C and a light/dark cycle of 12 hours. The animals were divided into 3 experimental groups (n = 24 per group): Control Group (CG) – untreated animals; Placebo Group (PG) – topical use of neutral mucoadhesive formulation (no active substance); *Curcuma longa* L. Group (CLG) – topical use of MFC.

### Experimental model

The animals were weighed and anesthetized with general anesthetics injected intraperitoneally using a mixture of 50 mg/kg of ketamine and 5 mg/kg of xylazine, and 1-2% isoflurane was used to achieve general anesthesia. Subsequently, ulcers were created in the center of the dorsal surface of the tongue of each animal using a punch instrument with a diameter of 0.3 mm and a height of 0.2 m. The base of the ulcer was incised with a scalpel blade #15, creating a 0.3-mm diameter surgical wound with well delimited and regular edges. For pain control, Tramadol 5 mg/kg was injected intraperitoneally once every 12 hours for 2 days. PG and CLG animals received two daily applications of neutral mucoadhesive formula and MFC, respectively. The amount was determined using a 0.5-g measuring spoon and the products were applied with a flexible rod completely covering the wound, under anesthesia with inhaled isoflurane. The animals of the CG group were handled daily similarly to the other groups, without receiving treatment. Six animals of each group were euthanized at 3, 5, 10, and 14 days under isoflurane anesthesia. The measurement of ulcers was then performed, and the wound areas were surgically removed and fixed in 10% buffered formalin solution and paraffin-embedded using routine histopathological procedures.

### Clinical Study

The animals were weighed at the beginning of the study and before being euthanized. At the end of the study, the wounds were photographed and the wound area was calculated in pixels using the ImageJ 1.48v software (National Institutes of Health, USA) and then converted to mm<sup>2</sup> using a reference scale. The percentage of wound healing was calculated using the formula:  $[(\text{initial area} - \text{final area}) / (\text{initial area})] \times 100^{21}$ .

### Histopathological Study

Serial histological sections were obtained at a thickness of 4  $\mu\text{m}$ , stained with hematoxylin-eosin, and observed under an optical microscope. Initially, a descriptive analysis of each experimental time was performed comparing the groups. Next, a semi-quantitative analysis was performed using scores. The criteria described by Sinha and Gallaher<sup>22</sup> (2003) were used, which scores the level of re-epithelization: grade 0 - at the edge of the wound; grade 1 - covering less than half of the wound; grade 2 - covering more than half of the wound; grade 3 - covering completely the wound with irregular thickness; grade 4 - covering completely the wound with a normal thickness.

The degree of inflammation was evaluated as described by Kumar, Cotran and Robbins<sup>23</sup> (2003): grade 1 - acute inflammation (pyogenic membrane); grade 2 - predominance of acute diffuse inflammation; grade 3 - predominance of chronic inflammatory process (proliferating fibroblasts); grade 4 - resolution and healing (reduction or disappearance of chronic inflammation despite the persistence of some inflammatory cells). Two pathologists blind to the experimental groups analyzed the sections and reached a consensus.

### Statistical analysis

The data are reported as means and standard deviations. SPSS software version 19.0 was used for statistical analysis. The unit of analysis was a single animal. Groups, evaluation times, and the interaction between group and evaluation time were compared by Kruskal-Wallis test or one-way ANOVA. The level of significance was set at 5% ( $p < 0.05$ ).

## RESULTS

For all analyses, a total number of 6 animals were included per group per day of evaluation. No adverse effect was observed during the experimental procedures.

### Body weight results

All groups showed a slight weight loss at day 3 followed by gradual weight gain up to day 14. No significant weight difference was observed between groups over the experimental period (Figure 1).

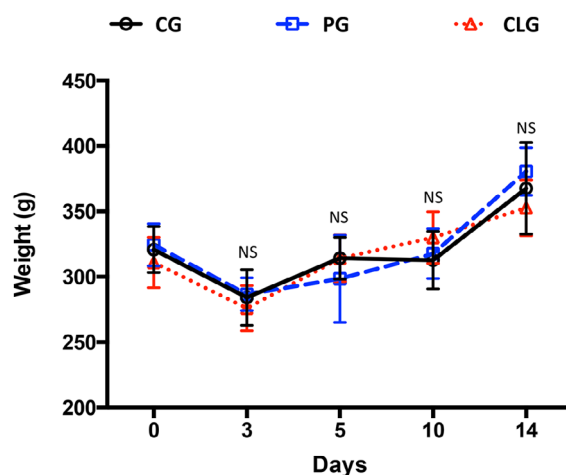
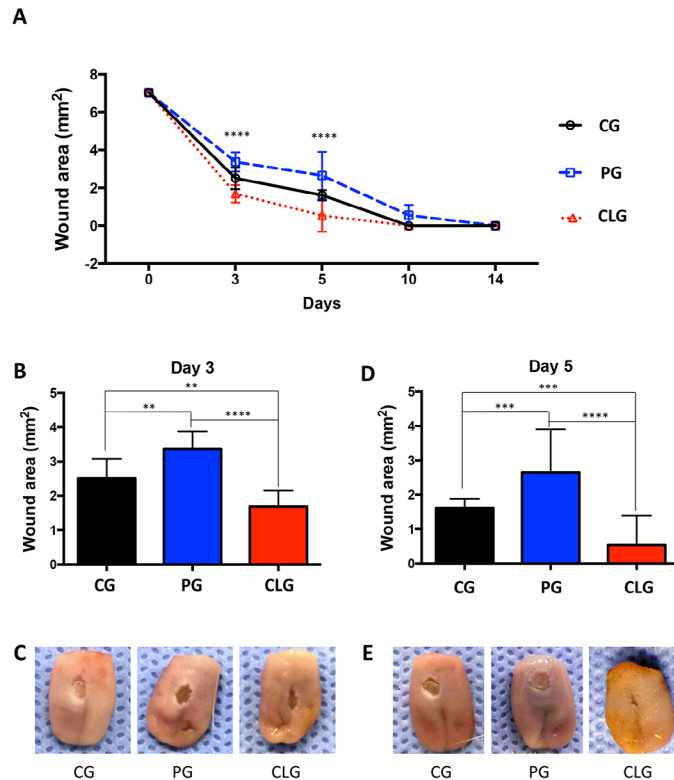


Figure 1: Body weight of animals during the study according to treatment groups.

### Clinical Analysis

A significant difference between groups was found for ulcer areas in the three experimental groups on days 3 and 5 (Figure 2A). On day 3, CLG presented a smaller ulcer area when compared to CG ( $p < 0.01$ ) and PG ( $p < 0.001$ ) (Figure 2B and C). Moreover, the PG animals presented a larger area when compared

to the CG ( $p < 0.01$ ). On day 5, there was a reduction of the wound in all experimental groups, however, CLG presented a smaller wound when compared to PG ( $p < 0.0001$ ) and CG ( $p < 0.001$ ). The PG animals showed a larger wound than the CG ( $p < 0.001$ ) (Figure 2D and E). On days 10 and 14 there was no difference between the groups and all showed wound closure.

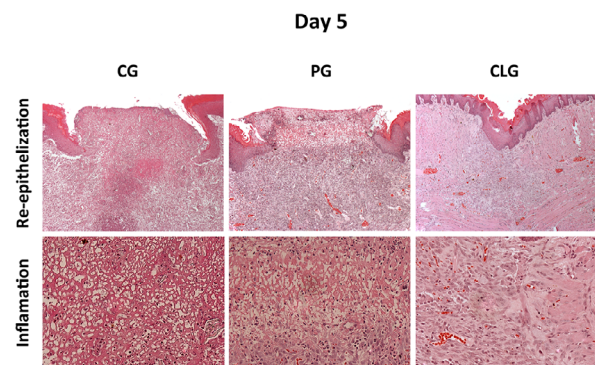


**Figure 2:** A: Healing pattern of oral mucosa wounds according to experimental groups over time; B: On day 3, there was a reduction of the wound area in the CLG compared to CG and PG (\*\* $p < 0.01$ , \*\*\* $p < 0.001$ ); C: Representative images of ulcers in the three groups on day 3; D: On day 5, there was a reduction of the CLG wound area compared to CG and PG (\*\* $p < 0.001$ , \*\*\*\* $p < 0.0001$ ); E: Representative images of ulcers in the three groups on day 5.

### Descriptive histopathological analysis

On day 3, all groups presented initial healing process exhibiting few areas covered by epithelium and predominance of exposed connective tissue. Acute inflammatory infiltrate (polymorphonuclear cells) was observed and at the bottom of the wound there was some evidence of collagen fiber deposition and angiogenesis.

On day 5, a better repair pattern was observed in CLG group with re-epithelialization covering completely the wound in most samples associated with a chronic inflammatory process. Fibroplasia, angiogenesis, and replacement of acute inflammatory cells by mononuclear inflammatory cells, mostly lymphocytes, were observed in the CLG group. In PG and CG, the new epithelial lining was not complete and the connective tissue exhibited a more acute inflammatory infiltrate compared to CLG (Figure 3).

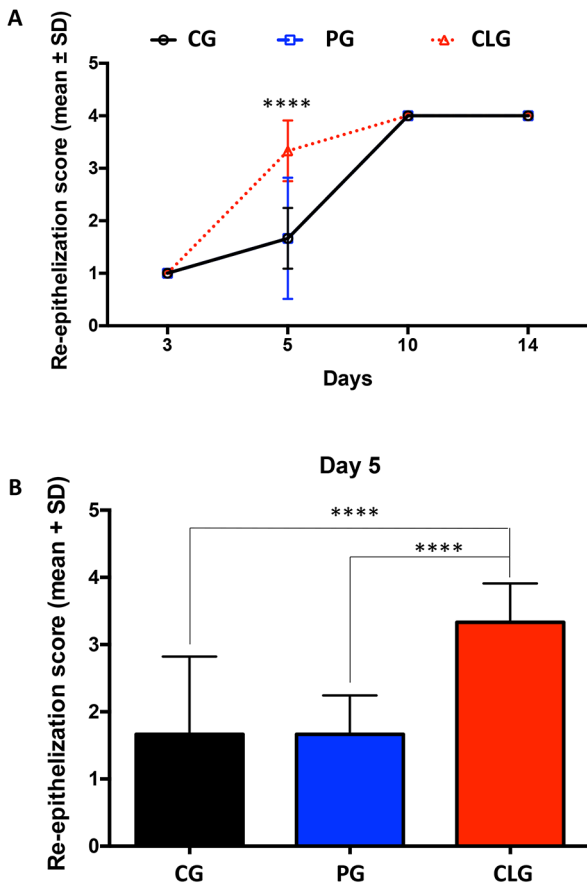


**Figure 3:** Microscopic appearance of oral mucosa ulcer repair in the three experimental groups on day 5, showing the new epithelial pattern (HE, 100x) and inflammatory infiltrate (HE, 400x). In CLG, the wound is completely covered by epithelial lining and the connective tissue has a higher deposition of fibers and a lower level of chronic inflammation compared to the other groups.

On days 10 and 14, all groups showed a similar pattern, microscopically. Full coverage of the wound with stratified squamous epithelium, reduction of the chronic inflammatory process, and organization of collagen fibers in the underlying connective tissue were observed.

**Re-epithelialization degree**

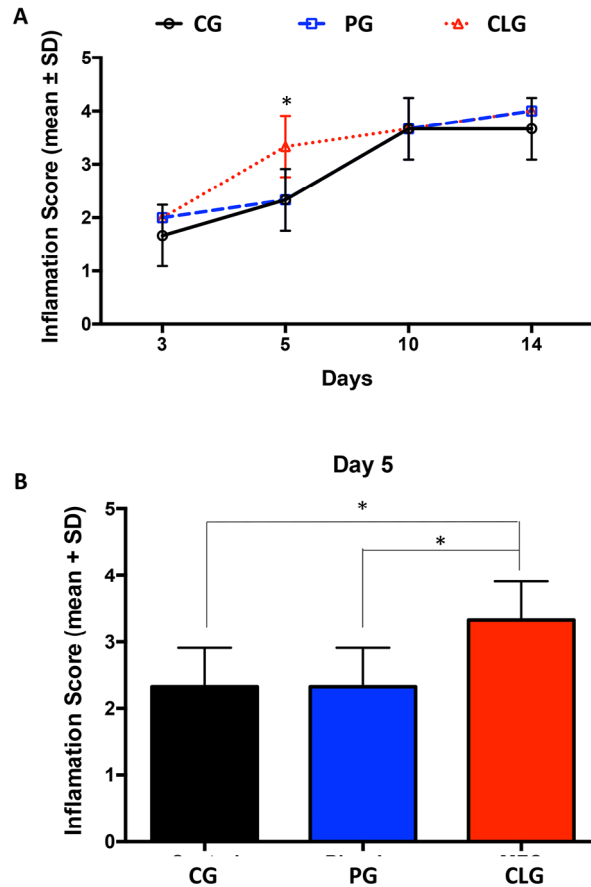
CLG animals presented a higher level of re-epithelialization when compared to CG ( $p < 0.001$ ) and PG ( $p < 0.001$ ) on day 5. On days 10 and 14 all groups showed complete wound closure (Figure 4A and B).



**Figure 4:** A: Degree of ulcer re-epithelialization in the different time-points; B: Re-epithelialization score analysis on day 5 showing that CLG presented significantly higher scores than CG and PG (\*\*\*\* $p < 0.0001$ ).

**Inflammatory degree**

On day 5, CLG presented a better resolution of the inflammatory process compared to CG ( $p < 0.05$ ) and PG ( $p < 0.05$ ) (Figure 5A and B), evidenced by a chronic inflammatory process and increased angiogenesis and collagen fiber deposition. On days 10 and 14 there was no difference between groups.



**Figure 5:** A: Degree of inflammation in the different time-points; B: Analysis of inflammation on day 5 showing that CLG presented a better resolution of the inflammatory process (\* $p < 0.05$ ).

**DISCUSSION**

Oral ulcers are commonly symptomatic and may interfere with the patient’s well-being. In the last decades, numerous studies have been developed to search for effective therapies for the management of these lesions, mainly involving the use of analgesics, anesthetics, antiseptics, and steroidal and nonsteroidal anti-inflammatory drugs<sup>2,24</sup>. The use of phytotherapeutics is a very promising treatment strategy, since these compounds have few or no adverse effect and drug interactions<sup>25,26</sup>. Our group has been studying the role of different natural compounds in oral lesions repair<sup>2,20,24,27</sup>, and herein we evaluated the topical action of MFC in the repair of oral ulcers. Our main results demonstrated that MFC accelerated the tissue repair process, with a faster re-epithelialization and modulation of the inflammatory process.

*Curcuma longa* L. is a well-known species in folk medicine due to its numerous biological activities, such as antioxidant, antimicrobial, curative, and anti-inflammatory<sup>8,17,28</sup>. An important aspect of curcumin

is its safety. The curcuminoids of *Curcuma longa* L. have a good safety profile in humans (12 g/day) and in animals (100 mg/kg per day), and are non-toxic even at high doses<sup>29,30</sup>. Our study did not directly assess the safety of this compound, but the analysis of body weight of the animals indirectly showed that MFC was not toxic to the animals. In addition, the animals of the 3 groups showed similar behavior throughout the study. After some weight loss in the first few days of the experiment, probably associated with the surgically created wound, the animals resumed normal feeding and weight gain.

Our results showed that CLG presented a smaller wound on days 3 and 5 compared to the other groups, demonstrating its capacity to accelerate oral wound healing. Curcumin also exhibited healing properties in other conditions, such as intestinal mucositis<sup>17</sup>. We recently demonstrated that MFC accelerated oral mucositis healing in an animal model<sup>18</sup>. Likewise, Patil and collaborators<sup>31</sup> (2015) demonstrated that a solution containing 0.004% curcumin was effective in healing oral mucositis in patients submitted to radio- or chemotherapy. Herein, we evaluated for the first time the healing effect of MFC in conventional oral ulcers, which have a different pathophysiology compared to oral mucositis. Moreover, oral ulcers, such as traumatic ulcers and recurrent aphthous stomatitis, are extremely common in our population. Therefore, we consider that the findings of the present study are relevant and indicate that this herbal medicine has potential as treatment of such oral lesions. Moreover, the association of *Curcuma longa* L. extract with a mucoadhesive formulation enhances the adhesion of the drug to the mucosa, probably increasing the drug's bioavailability and consequently its beneficial effects. The healing capacity of MFC has been previously demonstrated by our group in intestinal and oral mucositis<sup>17,18</sup>. Therefore, we believe that this strategy is highly efficient for a greater adhesion of the active compound. In addition, the increased retention decreases the risk of the patient swallowing the compound, preventing possible systemic adverse effects.

The histopathological findings observed in the present study corroborate our clinical findings. The improved repair pattern of the CLG group occurred due to the acceleration of the re-epithelialization process associated with the modulation of the inflammatory process in the connective tissue. Wound healing is a complex physiological process divided into three main overlapping stages: inflammation, cell proliferation, and remodeling phases<sup>32</sup>. First, the injury triggers

inflammation leading to hemostasis and clot formation followed by an acute tissue response. After, chronic inflammatory events replace the acute scenario, with fibroplasia and neovascularization along with re-epithelialization. In the final stage, formation of new extracellular matrix and tissue remodeling occur. The analysis of the inflammatory cells allows determining the stage of tissue repair. In the present study, the treatment of oral ulcers with MFC led to a faster resolution of the inflammatory process compared to the other groups. On day 5, the wounds treated with MFC had less acute inflammation, increased chronic inflammatory process evidenced by the presence of newly formed blood vessels, deposition of collagen fibers, and a higher level of re-epithelialization, indicating better tissue repair. In other words, the curcuminoids present in MFC controlled the inflammatory response, preventing its exacerbation and stimulating an earlier resolution. As demonstrated by other studies, curcuminoids act by modulating several transcription factors, especially the nuclear factor kappa B (NF- $\kappa$ B) and cyclooxygenase-2 (COX-2)<sup>7</sup>. In addition, the anti-inflammatory effect of curcumin is explained by its ability to reduce myeloperoxidase activity, which is related to neutrophil infiltration<sup>17</sup>.

The re-epithelialization process occurs most clearly in the proliferative phase of repair and is important for the formation of the epithelial barrier that allows tissue homeostasis to be restored<sup>33,34</sup>. Thus, our results indicate that the use of MFC promotes re-epithelialization at an earlier stage, accelerating wound repair. Likewise, the study by dos Santos Filho et al.<sup>17</sup>. (2015) demonstrated that a curcumin-containing compound stimulated intestinal epithelial proliferation, evidenced by the increased expression of the Ki67 proliferation marker. The compound was also able to decrease the expression of the Bax-2 apoptosis marker. Molecular analysis indicates that curcumin acts by activating transcription factors, growth factors and their receptors, modulating the synthesis of cytokines, and thus regulating genes involved in cell proliferation and apoptosis<sup>8</sup>.

Despite our promising results, extrapolating the present findings to wound treatment in humans is not advised, as animal models may not always adequately mimic human pathophysiology<sup>35</sup>. However, our previous experience with wound healing suggests that the Wistar rat model provides translational evidence that can be successfully reproduced in humans<sup>36,37</sup>. Therefore, we believe MFC is a promising treatment strategy for oral wounds in humans.

## CONCLUSION

We demonstrated that the mucoadhesive formulation containing Curcuma L. extract accelerated the repair of oral ulcers by modulating the inflammatory response and stimulating re-epithelialization in an animal model. Further studies, especially randomized clinical trials with humans, are needed to confirm these preliminary findings.

## Acknowledgments

This work was supported by the Postgraduate Research Group, Porto Alegre Clinics Hospital (GPPG/FIPE: 14-0572).

## Conflicts of Interest

The authors declare no potential conflicts of interest.

## REFERENCES

- Leão JC, Gomes VB, Porter S. Ulcerative lesions of the mouth: an update for the general medical practitioner. *Clinics (Sao Paulo)*. 2007; 62(6):769-80. doi:10.1590/s1807-59322007000600018.
- Martins MD, Marques MM, Bussadori SK, Martins MAT, Pavesi VCS, Mesquita-Ferrari RA, et al. Comparative analysis between Chamomilla recutita and corticosteroids on wound healing: An in vitro and in vivo study. *Phytother Res*. 2009;23(2):274-8. doi:10.1002/ptr.2612.
- Tiwari A, Goel M, Pal P, Gohiya P. Topical-steroid-induced iatrogenic Cushing syndrome in the pediatric age group: A rare case report. *Indian J Endocrinol Metab*. 2013;17(7 Suppl 1):257-8. doi:10.4103/2230-8210.119593.
- Speroni E, Cervellati R, Costa S, Guerra MC, Utan A, Govoni P, et al. Effects of differential extraction of Verbena officinalis on rat models of inflammation, cicatrization and gastric damage. *Planta Med*. 2007;73(3):227-35. doi: 10.1055/s-2007-967116.
- Baharvand M, Jafari S, Mortazavi H. Herbs in Oral Mucositis. *J Clin Diagn Res*. 2017;11(3):ZE05-11. doi: 10.7860/JCDR/2017/21703.9467.
- Cinausero M, Aprile G, Ermacora P, Basile D, Vitale MG, Fanotto V, et al. New Frontiers in the Pathobiology and Treatment of Cancer Regimen-Related Mucosal Injury. *Front Pharmacol*. 2017;8:1-16. doi:10.3389/fphar.2017.00354.
- Goel A, Kunnumakkara AB, Aggarwal BB. Curcumin as "Curecumin": from kitchen to clinic. *Biochem Pharmacol* 2008;75(4):787-809. doi:10.1016/j.bcp.2007.08.016.
- Gupta SC, Sung B, Kim JH, Prasad S, Li S, Aggarwal BB. Multitargeting by turmeric, the golden spice: From kitchen to clinic. *Mol Nutr Food Res*. 2013;57(9):1510-28. doi:10.1002/mnfr.201100741.
- Ahsan H, Parveen N, Khan NU, Hadi SM. Pro-oxidant, anti-oxidant and cleavage activities on DNA of curcumin and its derivatives demethoxycurcumin and bisdemethoxycurcumin. *Chem Biol Interact*. 1999;121(2):161-75. doi:10.1016/s0009-2797(99)00096-4.
- Maheshwari RK, Singh AK, Gaddipati J, Srimal RC. Multiple biological activities of curcumin: a short review. *Life Sci*. 2006;78(18):2081-7. doi:10.1016/j.lfs.2005.12.007.
- Lüer S, Troller R, Jetter M, Spaniol V, Aebi C. Topical curcumin can inhibit deleterious effects of upper respiratory tract bacteria on human oropharyngeal cells in vitro: potential role for patients with cancer therapy induced mucositis? *Support Care Cancer*. 2011;19(6):799-806. doi:0.1007/s00520-010-0894-x.
- Reddy CA, Somepalli V, Golakoti T, Kanugula AK, Karnewar S, Rajendiran K, et al. Mitochondrial-targeted curcuminoids: a strategy to enhance bioavailability and anticancer efficacy of curcumin. *PLoS One*. 2014;9(3):e89351. doi:10.1371/journal.pone.0089351.
- Nagpal M, Sood S. Role of curcumin in systemic and oral health: An overview. *J Nat Sci Biol Med*. 2013;4(1):3-7. doi:10.4103/0976-9668.107253.
- Mohammadi-Samani S, Bahri-Najafi R, Yousefi G. Formulation and in vitro evaluation of prednisolone bucco-adhesive tablets. *Farmaco*. 2005;60(4):339-44. doi:10.1016/j.farmac.2005.01.009.
- Park CG, Kim YK, Kim MJ, Park M, Kim MH, Lee SH, et al. Mucoadhesive microparticles with a nanostructured surface for enhanced bioavailability of glaucoma drug. *J Control Release*. 2015;220(Pt A):180-8. doi:10.1016/j.jconrel.2015.10.027.
- Kharia AA, Singhai AK. Development and optimisation of mucoadhesive nanoparticles of acyclovir using design of experiments approach. *J Microencapsul*. 2015;32(6):521-32. doi:10.3109/02652048.2015.1010457.
- Santos Filho EX, Ávila PHM, Bastos CCC, Batista AC, Naves LN, Marreto RN, et al. Curcuminoids from Curcuma longa L. reduced intestinal mucositis induced by 5-fluorouracil in mice: Bioadhesive, proliferative, anti-inflammatory and antioxidant effects. *Toxicol Rep*. 2016;3:55-62. doi:10.1016/j.toxrep.2015.10.010.
- Schmidt TR, Curra M, Wagner VP, Martins MAT, de Oliveira AC, Batista AC et al. Mucoadhesive formulation containing Curcuma longa L. reduces oral mucositis induced by 5-fluorouracil in hamsters. *Phytother Res*. 2019;33(4):881-90. doi:10.1002/ptr.6279.
- Wagner VP, Meurer L, Martins MAT, Danilevicz CK, Magnusson AS, Marques MM, et al. Influence of different energy densities of laser phototherapy on oral wound healing. *J Biomed Opt*. 2013;18(12). doi:10.1117/1.JBO.18.12.128002.
- Wagner VP, Webber LP, Ortiz L, Rados PV, Meurer L, Lameira OA, et al. Effects of Copaiba Oil Topical Administration on Oral Wound Healing. *Phytother Res*. 2017;31(8):1283-8. doi:10.1002/ptr.5845.
- Yen YH, Pu CM, Liu CW, Chen YC, Chen YC, Liang CJ, et al. Curcumin accelerates cutaneous wound healing via multiple biological actions: The involvement of TNF- $\alpha$ , MMP-9,  $\alpha$ -SMA, and collagen. *Int Wound J*. 2018;15(4):605-17. doi:10.1111/iwj.12904.

22. Sinha UK, Gallagher LA. Effects of steel scalpel, ultrasonic scalpel, CO2 laser, and monopolar and bipolar electrosurgery on wound healing in guinea pig oral mucosa. *Laryngoscope*. 2003;113(2):228-36. doi:10.1097/00005537-200302000-00007.
23. Kumar V, Cotran RS, Robbins SL. *Robbins Basic Pathology*. 7th ed. Amsterdam: Elsevier; 2002.
24. Curra M, Martins MA, Lauxen IS, Pellicoli AC, Sant'Ana Filho M, Pavesi VC et al. Effect of topical chamomile on immunohistochemical levels of IL-1 $\beta$  and TNF- $\alpha$  in 5-fluorouracil-induced oral mucositis in hamsters. *Cancer Chemother Pharmacol*. 2013;71(2):293-9. doi:10.1007/s00280-012-2013-9.
25. Mlcek J, Jurikova T, Skrovankova S, Sochor J. Quercetin and Its Anti-Allergic Immune Response. *Molecules*. 2016;21(5). doi:10.3390/molecules21050623.
26. Guan LP, Liu BY. Antidepressant-like effects and mechanisms of flavonoids and related analogues. *Eur J Med Chem*. 2016;121(4):47-57. doi:10.1016/j.ejmech.2016.05.026.
27. Pavesi VCS, Lopez TCC, Martins MAT, Sant'Ana Filho M, Bussadori SK, Fernandes KPS, et al. Healing action of topical chamomile on 5-fluoracil induced oral mucositis in hamster. *Support Care Cancer*. 2011;19(5):639-46. doi:10.1007/s00520-010-0875-0.
28. Akbik D, Ghadiri M, Chrzanowski W, Rohanizadeh R. Curcumin as a wound healing agent. *Life Sci*. 2014;116(1):1-7. doi:10.1016/j.lfs.2014.08.016.
29. Lao CD, Ruffin MT, Normolle D, Heath DD, Murray SI, Bailey JM, et al. Dose escalation of a curcuminoid formulation. *BMC Complement Altern Med*. 2006;6(10):1-10. doi:10.1186/1472-6882-6-10.
30. Teiten MH, Eifes S, Dicato M, Diederich M. Curcumin: the paradigm of a multi-target natural compound with applications in cancer prevention and treatment. *Toxins (Basel)*. 2010;2(1):128-62. doi:10.3390/toxins2010128.
31. Patil K, Guledgud MV, Kulkarni PK, Keshari D, Tayal S. Use of Curcumin Mouthrinse in Radio-Chemotherapy Induced Oral Mucositis Patients: A Pilot Study. *J Clin Diagn Res*. 2015;9(8): ZC59-62. doi:10.7860/JCDR/2015/13034.6345.
32. Gonzalez ACO, Costa TF, Andrade ZA, Medrado AR. Wound healing: A literature review. *An Bras Dermatol*. 2016;91(5):614-20. doi:10.1590/abd1806-4841.20164741.
33. Ben Amar M, Wu M. Re-epithelialization: advancing epithelium frontier during wound healing. *J R Soc Interface*. 2014;11(93): 1-7. doi:10.1098/rsif.2013.1038.
34. Pellicoli ACA, Martins MD, Dillenburg CS, Marques MM, Squarize CH, Castilho RM. Laser phototherapy accelerates oral keratinocyte migration through the modulation of the mammalian target of rapamycin signaling pathway. *J Biomed Opt*. 2014;19(2). doi:10.1117/1.JBO.19.2.028002.
35. Hackam DG. Translating animal research into clinical benefit. *BMJ* 2007;334(7586):163-4. doi:10.1136/bmj.39104.362951.80.
36. Ávila PHM, Ávila RI, Santos Filho EX, Cunha Bastos CC, Batista AC, Mendonça EF, et al. Mucoadhesive formulation of *Bidens pilosa* L. (Asteraceae) reduces intestinal injury from 5-fluorouracil-induced mucositis in mice. *Toxicol Rep*. 2015; 2: 563-73. doi:10.1016/j.toxrep.2015.03.003.
37. Santos Filho EXD, Arantes DAC, Oton Leite AF, Batista AC, Mendonça EF, Marreto RN, et al. Randomized clinical trial of a mucoadhesive formulation containing curcuminoids (Zingiberaceae) and *Bidens pilosa* Linn (Asteraceae) extract (FITOPROT) for prevention and treatment of oral mucositis – phase I study. *Chem Biol Interact*. 2018;291: 228-36. doi:10.1016/j.cbi.2018.06.010.

Received: Mar 2, 2020

Accepted: Aug 4, 2020