

Clinical and ultrasonographic correlation of changes in the equine axial skeleton with thoracic and pelvic lameness detected by objective evaluation

Correlação clínica e ultrassonográfica de alterações do esqueleto axial equino e as claudicações torácicas e pélvicas detectadas por avaliação objetiva

Correlación clínica y ultrasonográfica de las alteraciones en el esqueleto axial equino y las cojeras torácicas y pélvicas detectadas mediante evaluación objetiva

Received: 10/18/2023 | Revised: 10/30/2023 | Accepted: 10/31/2023 | Published: 11/03/2023

Grasiela De Bastiani

ORCID: <https://orcid.org/0000-0002-4748-7560>
Universidade Federal do Rio Grande do Sul, Brasil
E-mail: grasiela.bastiani@ufrgs.br

Marcos da Silva Azevedo

ORCID: <https://orcid.org/0000-0002-9760-8594>
Universidade Federal do Pampa, Brasil
E-mail: marcosazevedo@unipampa.edu.br

Tainã Kuwer Jacobsen

ORCID: <https://orcid.org/0000-0002-3497-4175>
Universidade Federal do Rio Grande do Sul, Brasil
E-mail: tainajacobsen@gmail.com*

Ana Paula Rodrigues

ORCID: <https://orcid.org/0000-0002-8790-930X>
Universidade Federal do Pampa, Brasil
E-mail: anapauladacostar@gmail.com

Flávio Desessards De La Côte

ORCID: <https://orcid.org/0000-0003-4958-5428>
Universidade Federal de Santa Maria, Brasil
E-mail: delacorte2005@yahoo.com.br

Abstract

Cervical and thoracolumbar changes are commonly found in sports animals and may be related to biomechanical alterations, driving movement, and the type of saddle used. The objective of this study was to characterize the correlation between clinical and ultrasonographic findings of the equine axial skeleton with objective evaluation lameness in the thoracic or pelvic limbs. A total of 76 horses of the mounted cavalry with an average of ten years of age, divided between castrated males and females of indeterminate breeds, were submitted to clinical, ultrasonographic and objective evaluations. The evaluated variables were classified in scores from 0 to 4, for later statistical analysis spearman correlation through the RStudio® software. The animals were classified into six groups according to the objective, clinical and ultrasonographic changes. A weak positive correlation was observed between the objective evaluation variable in relation to the clinical ($r = 0.1$, $p > 0,05$) and ultrasonographic ($r = 0.1$, $p > 0,05$) evaluation variables. In the present study, it was impossible to consider the correlations statistically significant since the p-value was higher than the significance level of 5%. Therefore, the associated evaluation of the axial and appendicular skeleton is of fundamental importance in the clinical routine to investigate musculoskeletal changes. This was demonstrated in the present study, where 68.42% (n=52) presented both clinical and ultrasonographic changes of the axial skeleton concomitantly with thoracic and/or pelvic lameness.

Keywords: Cervical; Thoracolumbar; Lameness; Ultrasonographic; Objective.

Resumo

As alterações cervicais e toracolombares são comumente encontradas em animais de esporte e podem estar relacionadas a alterações biomecânicas, movimento de condução e ao tipo de sela utilizada. O objetivo deste estudo foi caracterizar a correlação entre os achados clínicos e ultrassonográficos do esqueleto axial equino com a avaliação objetiva de claudicação nos membros torácicos ou pélvicos. Um total de 76 cavalos da cavalaria montada, com uma média de dez anos de idade, divididos entre machos castrados e fêmeas de raças indeterminadas, foram submetidos a avaliações clínicas, ultrassonográficas e objetivas. As variáveis avaliadas foram classificadas em escores de 0 a 4, para posterior análise estatística de correlação de Spearman por meio do software RStudio®. Os animais foram classificados em seis grupos de acordo com as alterações na avaliações objetiva, clínica e ultrassonográfica. Foi observada uma correlação positiva fraca entre a variável de avaliação objetiva em relação às variáveis de avaliação

clínica ($r = 0,1$, $p > 0,05$) e ultrasonográfica ($r = 0,1$, $p > 0,05$). No presente estudo, não foi possível considerar as correlações estatisticamente significativas, uma vez que o valor de p foi superior ao nível de significância de 5%. Portanto, a avaliação associada do esqueleto axial e apendicular é de fundamental importância na rotina clínica para investigar alterações musculoesqueléticas. Isso foi demonstrado no presente estudo, onde 68,42% ($n=52$) apresentaram tanto alterações clínicas quanto ultrasonográficas no esqueleto axial concomitantemente com claudicação torácica e/ou pélvica.

Palavras-chave: Cervical; Toracolombar; Claudicação; Ultrasonografia; Objetiva.

Resumen

Las alteraciones cervicales y toracolumbares son comunes en animales deportivos y pueden estar relacionadas con cambios biomecánicos, el movimiento de conducción y el tipo de silla utilizada. El objetivo de este estudio fue caracterizar la correlación entre los hallazgos clínicos y ultrasonográficos del esqueleto axial equino con la evaluación objetiva de la cojera en las extremidades torácicas o pélvicas. Un total de 76 caballos de la caballería montada, con una media de diez años de edad, divididos entre machos castrados y hembras de razas indeterminadas, se sometieron a evaluaciones clínicas, ultrasonográficas y objetivas. Las variables evaluadas se clasificaron en puntuaciones del 0 al 4, para un posterior análisis estadístico de correlación de Spearman mediante el software RStudio®. Los animales se clasificaron en seis grupos de acuerdo con las alteraciones en las evaluaciones objetivas, clínicas y ultrasonográficas. Se observó una correlación positiva débil entre la variable de evaluación objetiva en relación con las variables de evaluación clínica ($r = 0,1$, $p > 0,05$) y ultrasonográfica ($r = 0,1$, $p > 0,05$). En el presente estudio, no fue posible considerar las correlaciones estadísticamente significativas, ya que el valor de p fue superior al nivel de significancia del 5%. Por lo tanto, la evaluación conjunta del esqueleto axial y apendicular es de fundamental importancia en la rutina clínica para investigar las alteraciones musculoesqueléticas. Esto se demostró en el presente estudio, donde el 68,42% ($n=52$) presentó tanto alteraciones clínicas como ultrasonográficas en el esqueleto axial de manera concomitante con la cojera torácica y/o pélvica.

Palabras clave: Cervicale; Toracolumbar; Cojera; Ultrasonografia; Objetiva.

1. Introduction

Neck pain may cause reluctance to work possibly associated with the type of training, trainer, rider, mouth changes, thoracic and pelvic limb lameness and thoracolumbar spine pain. Neck stiffness can be considered a protective mechanism by the horse to avoid the pain that may be associated with lameness especially from thoracic limbs. For example, a horse with thoracic limb lameness may develop a reluctance to turn correctly to the left when the rider triggers the rein (Dyson, 2011). The painful condition and stiffness of the neck can limit athletic potential and predisposing the secondary development of different diseases (García-López, 2018). The spinal pain (primary or secondary) can be associated with poor sports performance, however locating the specific site of pain is extremely difficult (Klide, 1984; Martin & Klide, 1997; Mayaki et al. 2019).

Osteoarthritis of the articular facets can lead to difficulty in lateralizing neck movements, rejection of obstacles in jumping events, or even primary neurological signs, such as motor incoordination of pelvic limbs (Carr & Mather, 2014). Like in humans, equine spine problems are also recurrent (Denoix, 1998). In addition, a strong association between lameness and spinal problems in horses has been proven (Gómez-Álvarez et al., 2007a; Gómez-Álvarez et al., 2007b).

Clinical evaluation should be performed with the horse at rest by first observing the horse's attitude, muscle symmetry, conformation, and general conditions. Horses may have abnormal curvature of the spine (lordosis, kyphosis, or scoliosis) conditions that may predispose them to painful processes (Findley & Singer, 2015; Martin et al., 2017; Mayaki et al., 2019). The motion examination should focus on the presence of lameness or asymmetry between the thoracic and pelvic limbs and abnormalities caused by the position of the head and neck, as well as the mobility of the trunk (Dyson, 2011). This study aims to characterize the correlation between clinical and ultrasonographic findings of the axial skeleton with objective evaluation lameness in the thoracic or pelvic limbs.

2. Methodology

2.1 Animals

The study included seventy-six horses of mixed breeds, composed of sixty-six castrated males and ten females, stabled at the Cavalry of the Military Police of the south Brazil, used for patrol activities, equestrian events, and equine therapy, with an average ten years of age (ranging from 4 to 15 years) and 550 kg of average weight. Clinical history, feeding management, and previous musculoskeletal injuries were obtained. Inclusion criteria were based only on animals that did not present wounds of the appendicular skeleton, abscesses, and/or hoof hematomas.

The present study was approved by the National Council for Control of Animal Experimentation (CONCEA) and was by the Ethic Committee on Animal Use of the Federal University of Santa Catarina (CEUA/UFSC) in the meeting of 17/05/2022, protocol number 4224210720

2.2 Clinical evaluation of the axial skeleton

Visualization and palpation of the cervical and thoracolumbar spine were performed to diagnose possible myopenia (muscle wasting) and sensitivity to palpation of the skeleton. Articular mobility of the cervical segment was observed by flexion movements, an extension of the atlanto-occipital joint, and lateralization movements of the cervical spine. In addition, palpation of the thoracolumbar spine was applied through the motions of extension, flexion, and lumbosacral rotation, with its articular amplitude assessed as present, decreased, and/or absent. The assessments were documented using a GoPro Hero9 camera. The animals were classified according to the following scores: 0 = no changes; 1 = muscle myopenia with a slight reduction in axial mobility; 2 = muscle myopenia with a moderate decrease in axial mobility; 3 = muscle myopenia with a severe reduction in axial mobility; 4 = muscle myopenia with the absence of axial mobility. The clinical evaluation of the axial skeleton and definition of scores was performed by a blinded expert evaluator.

2.3 Ultrasound evaluation of the axial skeleton

When necessary, the horses were trichotomized for the US evaluation in the cervical region from cervical 1 (C1) to cervical (C7), thoracolumbar 7 (T7) to lumbar 6 (L6), and lumbar 6 to sacral 1 (S1). The US images were produced using a Sonosite SW device with a 3 – 5 MHz convex probe. Warm water and gel were used to facilitate the coaptation of the transducer and the structures to be evaluated. The characteristics of the cervical, thoracic, and lumbar spine were related by the regularity of the hyperechogenic bone surface of the articular facets, articular capsule thickness, articular space reduction, presence of synovial fluid cellularity, osteophyte formation, echogenicity of the multifidus dorsi muscle, and dorsal extensor muscle of the spine. The animals were classified according to the following scores: 0 = no change; 1 = slight irregularity of articular facets, a slight decrease of articular space and slight capsulitis. 2 = moderate irregularity of articular facets, a moderate decrease of articular space and moderate capsulitis. 3 = significant irregularity of articular facets, a significant decrease of articular space and significant capsulitis. 4 = severe irregularity of articular facets, a severe reduction of articular space and severe capsulitis. The ultrasound evaluation of the axial skeleton and definition of scores was performed by a blinded expert evaluator.

2.4 Objective evaluation of the appendicular skeleton

The objective evaluation was performed using a commercial wireless inertial sensors system (Lameness Locator™, Equinosis LLC, Saint Louis, MO, USA), initially by trotting in a straight line and on hard ground, with the animals pulled by the halter for a distance of 30 meters, back and forth, so that a minimum of 25 steps were obtained. Subsequently, the animals

were examined in a circle on a soft floor, initially counterclockwise and then clockwise, to perform the same number of turns in both directions. The instrumentation of the animals, as well as the data collection and analysis, were performed as recommended (Keegan et al., 2012).

The Vector Sum value (Lameness Intensity), which should be greater than 8.5 mm, the HDmax values (mean and standard deviation) – the difference between the highest point of the head after the support of the right thoracic limb and the highest point of the head after the support of the left thoracic limb, and HDmin values (mean and standard deviation) – the difference between the lowest point of the head during the support of the right thoracic limb and the lowest point of the head during the support of the left thoracic limb, were used to identify lameness on the thoracic limbs. The HDmin values help identify the lame limb, and the HDmax values demonstrate a pushoff or impact type of lameness. At least one of these values must be greater than 6 mm, with its respective standard deviation lower than the mean. The PDmax values (mean and standard deviation) – the difference between the highest point of the pelvis after the support of the right pelvic limb and the highest point of the pelvis after the support of the left pelvic limb, and PDmin values (mean and standard deviation) – the difference between the lowest point of the pelvis during the support of the right pelvic limb and the lowest point of the pelvis during the support of the left pelvic limb, were used to identify lameness in the pelvic limbs. At least one of these values should be greater than 3 mm, with its respective deviation standard lower than the mean.

They were evaluation according to by the Lameness Locator® software and following scale: left thoracic limb lameness (LTL) = 1; right thoracic limb lameness (RTL) = 2; left pelvic limb lameness (LPL) = 3; right pelvic limb lameness (RPL) = 4; LTL and RTL lameness = 5; LTL and LPL lameness = 6; LTL and RPL lameness = 7; RTL and LPL lameness = 8; RTL and RPL lameness = 9; LPL and RPL lameness = 10; LTL, RTL, and LPL lameness = 11; LTL, RTL, and RPL lameness = 12; LTL, LPL, and RPL lameness = 13; RTL, LPL, and RPL lameness = 14; LTL, RTL, LPL, and RPL lameness = 15; and without lameness = 16.

2.5 Statistical analysis

After the evaluations and data compilation, the variables and their respective scores were submitted to Spearman correlation (nonlinear design) statistical analysis using the RStudio® software at a significance level of 5%. Each variable was correlated with the other variables of the study since they were defined as the response variable to demonstrate a possible association between the evaluations and clinical changes found. Thus, it was determined that the strong positive correlations had a result of $p < 0.05$ and correlation (r) = 1 to 0,5, moderate positive correlations $p < 0.05$ and $r = 0.4$ to 0,3, and weak positive correlations $p < 0.05$ and $r = 0.2$ to 0,1 (Cohen, 1988).

The objective evaluation was defined as the response variable (“Does the horse show lameness?” yes or no) of the statistical study, correlating it with other variables classified in scores. The clinical evaluation of the axial skeleton (no changes – 0; myopenia and slight reduction mobility – 1; myopenia and moderate reduction mobility – 2; myopenia and severe reduction mobility – 3 and myopenia and absence mobility – 4) and ultrasonographic evaluation of the axial skeleton (no changes – 0; slight irregularities – 1; moderate irregularities – 2; significant irregularities – 3 and severe irregularities – 4). Then, the results were interpreted according to the previously described correlation score and the p value was determined.

This article is based on a case study with subsequent qualitative and quantitative evaluation for statistical analysis of correlation between variables.

3. Results

The animals were classified into six groups according to the clinical and US findings: control group animals $n=6$

(7.89%); thoracic lameness associated with cervical changes group n=28 (36.84%); thoracic and pelvic lameness without axial skeletal changes group n=18 (23.68%); pelvic lameness and thoracolumbar changes group n=7 (9.21%); pelvic lameness and cervical and thoracolumbar changes group n=17 (22.37%).

3.1 Thoracic limb lameness associated with clinical and ultrasonographic changes of the cervical spine group

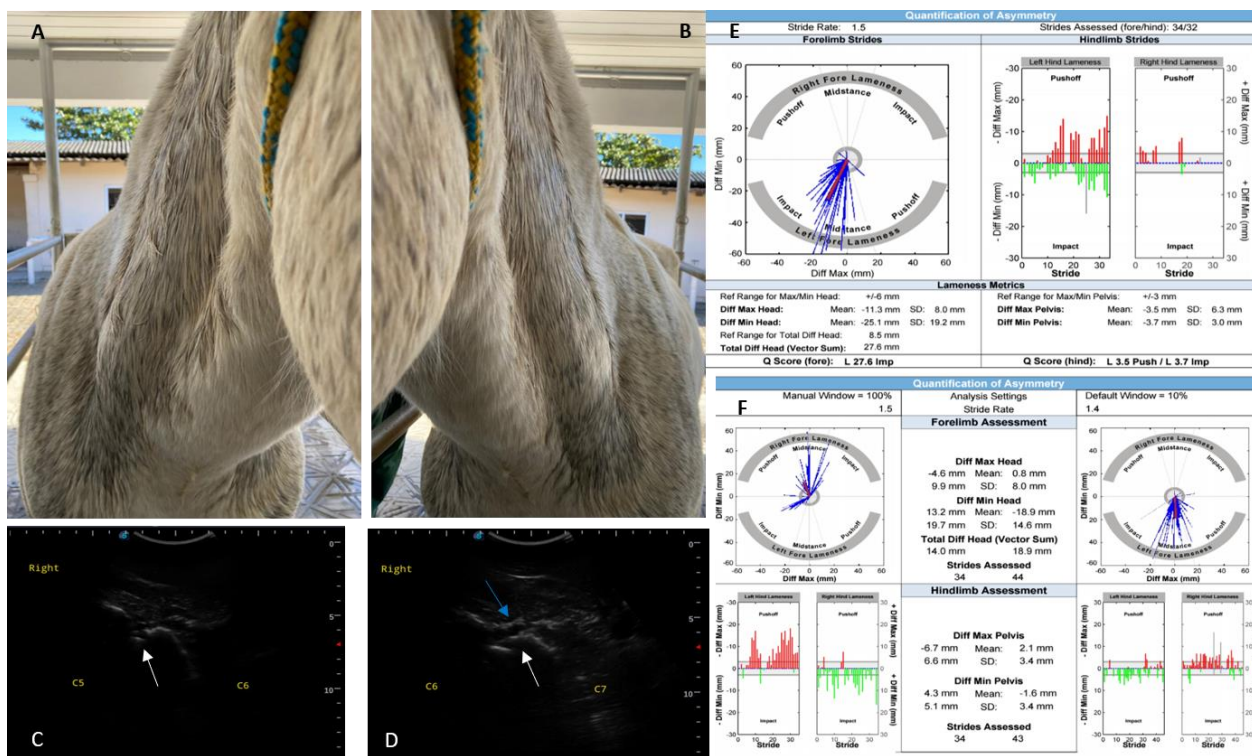
The animals that received this classification presented lameness in the thoracic limbs observed both in the subjective and objective evaluation, associated with changes in the cervical spine segment characterized as myopenia and decreased articular mobility through right and left lateralization movements and atlanto-occipital articular ventral flexion. The US images that corresponded to reduced articular space, osteophytes, articular surface irregularities, and capsulitis, observed mainly between C4 to C7 (64.28% n=18). Of the twenty-eight animals in this group, 32.14% (n=9) presented concomitantly asymmetric hooves, pain on pressure of the sole, and distension of the dorsal recess of the distal interphalangeal articulation.

In the clinical evaluation of the cervical skeleton, 64.28% (n=18) presented grade 1, 28.57% (n=8) grade 2, 7.14% (n=2) grade 3, and 0% (n=0) grade 4 changes (Figure 1/A-B). In the ultrasound evaluation of the cervical spine, 32.14% (n=9) presented grade 1, 53.57% (n=15) grade 2, 7.14% (n=2) grade 3, and 7.14% (n=2) grade 4 changes (Figure 1/C-D).

The objective evaluation showed that 39.28% (n=11) of the animals evaluated presented mild support lameness; 10.71% (n=3) demonstrated moderate support lameness; 21.42% (n=6) presented mild impact lameness; 14.28% (n=4) presented moderate impact lameness; 7.14% (n=2) presented severe impact lameness, and only 7.14% (n=2) of the animals presented mild elevation lameness (Figure 1/E-F). None of the animals evaluated in this group presented bilateral lameness of thoracic limbs. Animals with decreased caudal phase of the stride corresponded to 14.28% (n=4).

Regarding the lame limb and US changes, 35.71% (n=10) of the horses presented RTL lameness related to US changes of the right cervical spine. However, LTL lameness was associated with US changes in the left cervical spine in 14.21% (n=4) in these cases. In contrast, RTL lameness and US changes of the left cervical spine were observed in 14.28% (n=4), and LTL lameness and US changes of the right cervical spine in 25% (n=7) of the animals evaluated. In addition, the LTL and RTL lameness alone were related to concomitant left and right US changes in 3.57% (n=1) and 7.14% (n=2), respectively.

Figure 1 - Thoracic limb lameness associated with cervical clinical and ultrasonographic changes group. (A e B) Moderate myopenia in the cervical region is pronounced on the right side (A) when compared to the left side (B). (C) Cross-sectional ultrasonography. Medial to the left and lateral to the right. The joint space of the articular facets of C5 and C6 is observed on the right side, demonstrating an articular osteophyte (white arrow). (D) Cross-sectional ultrasonography. Medial to the left and lateral to the right. An irregularity of the joint facets of C6 (blue arrow) and C7 (white arrow) is observed on the right side. (E) The straight-line assessment demonstrates moderate left thoracic limb impact lameness and mild left pelvic limb impact lameness. (F) The circle evaluation did not demonstrate lameness or may be indicative of bilateral elevation lameness.



Source: Authors (2023).

3.2 Pelvic limb lameness associated with thoracolumbar physical and ultrasonographic changes group

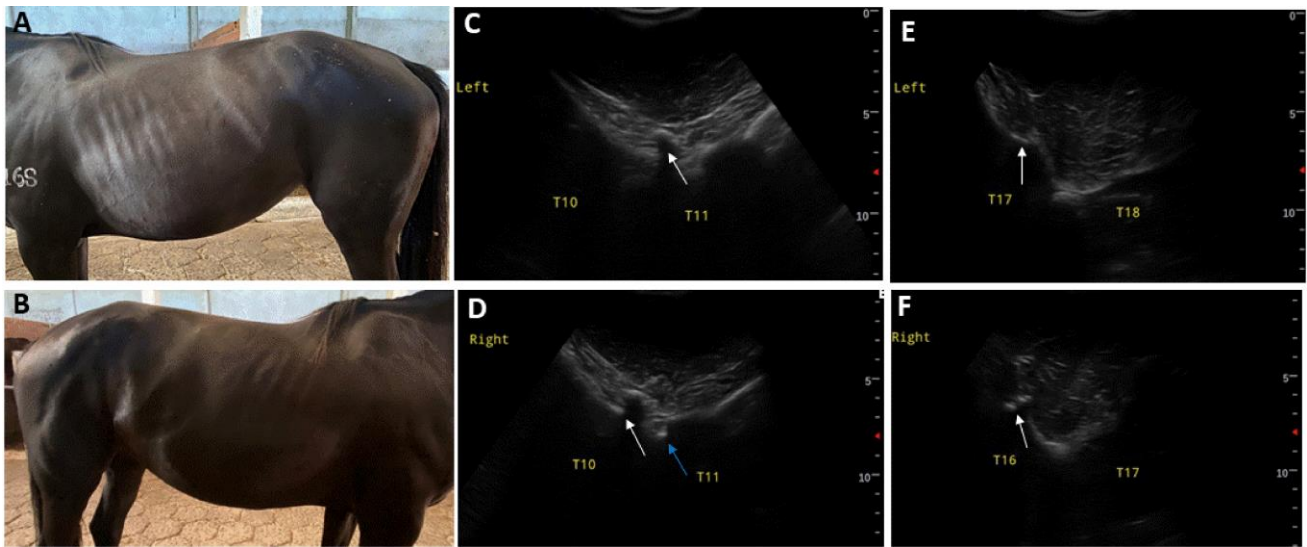
The horses of this group presented pelvic limb lameness detected both in the subjective and objective evaluations associated with changes in the thoracolumbar spine characterized as myopenia of the thoracolumbar extensor muscles and decreased joint mobility such as reduction to the thoracolumbar extension and flexion stimulus caused by manual pressure. Some horses presented discomfort on manual pressure of the thoracolumbar segment, characterized by behavioral manifestations such as kicking, change of limb support, and reluctance to the touch. Ultrasonographic images of thoracolumbar spine corresponded to decreased articular space, osteophytes, articular surface irregularities, and hyperechogenic areas of the dorsal multifidus muscle. Ultrasonographic changes in the thoracic segment corresponded to 28.57% (n=2), the lumbar segment to 28.57% (n=2), and the thoracolumbar segment to 42.85% (n=3).

In the clinical evaluation of the thoracolumbar spine, 57.14% (n=4) presented grade 1 and 42.85% (n=3) grade 2 changes (Figure 2/A-B). No animals showed grade 3 and 4 changes. In the ultrasound evaluation of the thoracolumbar spine, 28.57% (n=2) presented grade 1, 42.85% (n=3) grade 2, 28.57% (n=2) grade 3, and 0% (n=0) grade 4 changes (Figure 2/C-D-E-F).

The objective evaluation showed that 57.14% (n=4) of the evaluated horses presented mild elevation lameness, 28.57% (n=2) presented moderate push off type lameness, and only 14.28% (n=1) presented mild impact lameness (Figure

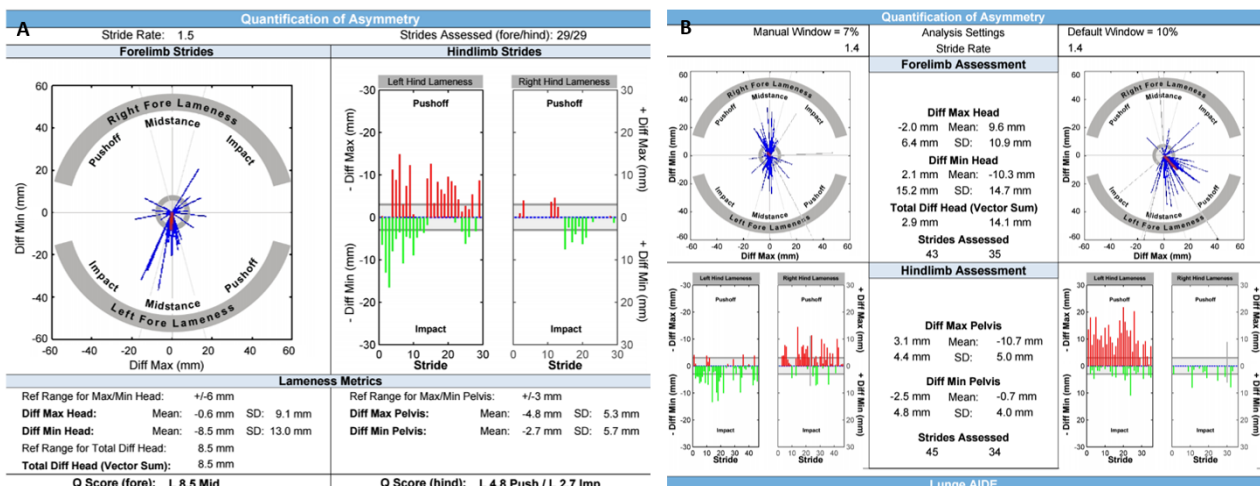
3/A-B). All animals showed US changes on the right and left thoracolumbar side, along with RPL lameness in 57.14% (n=4) and LPL lameness in 42.85% (n=3) of the evaluated cases.

Figure 2 - Pelvic limb lameness associated with thoracolumbar clinical and ultrasonographic changes group. (A e B) Mild myopenia is observed on the left thoracolumbar region (A) and more evident on the right (B). (C) Cross-sectional ultrasonography. Medial to the left and lateral to the right. Joint space between T10 and T11 is observed with a small osteophyte (white arrow) on the left side. (D) Cross-sectional ultrasonography. Medial to the left and lateral to the right. Joint space between T10 and T11 is observed on the right side, demonstrating a small osteophyte (white arrow) and a small fragment (blue arrow) near the cross-sectional process. (E) Cross-sectional ultrasonography. Medial to the left and lateral to the right. The joint space between T17 and T18 is observed on the left side associated with the presence of osteophyte (white arrow). (F) Cross-sectional ultrasonography. Medial to the left and lateral to the right. Fragmentation of the articular facets (white arrow) is observed in the articular space of T16 and T17 on the right side.



Source: Authors (2023).

Figure 3 - Pelvic limb lameness associated with thoracolumbar clinical and ultrasonographic changes group. (A) The straight-line evaluation showed no lameness. (B) The evaluation in the left circle showed no lameness while showing a left pelvic limb elevation lameness in the right circle.



Source: Authors (2023).

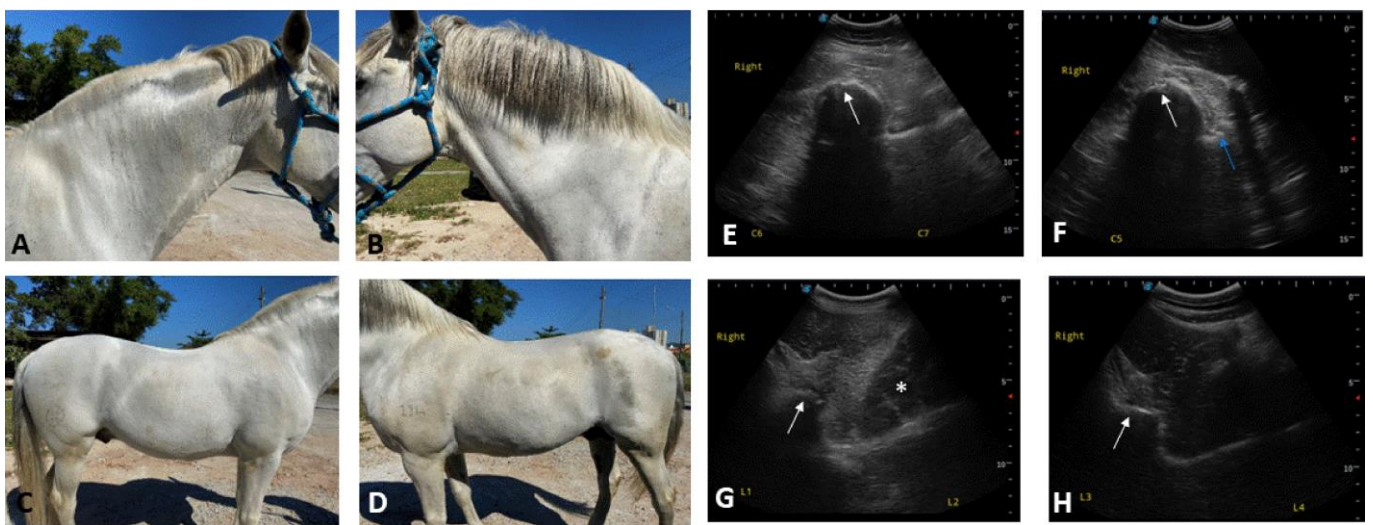
3.3 Pelvic limb lameness associated with cervical and thoracolumbar clinical and ultrasonographic changes group

In this group, the same clinical and US changes were observed in the cervical and thoracolumbar segments concomitantly with pelvic limb lameness. Cervical and thoracolumbar segment atrophy, decreased articular mobility and discomfort on thoracolumbar palpation, concerning ultrasound characteristics, were the same as mentioned above.

In the clinical evaluation of the cervical and thoracolumbar spine, 70.58% (n=12) presented grade 1, 11.76% (n=2) grade 2, 17.64% (n=3), grade 3, and 0% (n=0) grade 4 changes (Figure 4/A-B-C-D). Regarding the US changes of the cervical and thoracolumbar spine, 70.58% (n=12) presented grade 1, and 29.51% (n=5) presented grade 2 changes (Figure 4/E-F-G-H).

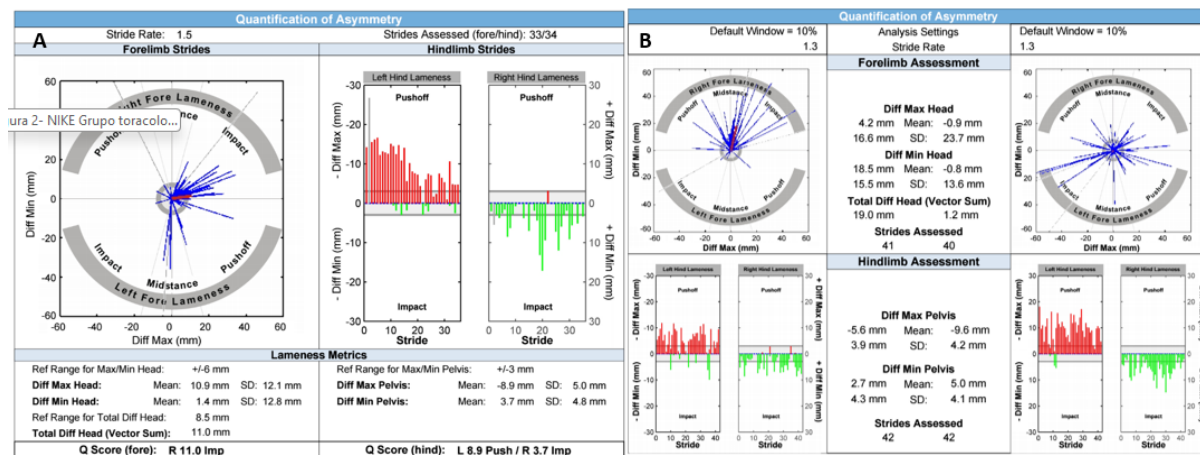
It was observed that 35.29% (n=6) of the animals evaluated in this group presented a mild pelvic elevation lameness, and 47.05% (n=8) presented a moderate pelvic push off type of lameness in the objective evaluation. In contrast, only 11.76% (n=2) had a mild pelvic impact lameness, and 5.88% (n=1) had a moderate pelvic impact lameness (Figure 5/A-B). All animals evaluated in this group, 100% (n=17), presented clinical findings and ultrasound changes in both right and left thoracolumbar segments, associated with clinical and ultrasound changes in the left cervical spine in 47.05% (n=8), right cervical spine changes in 35.29% (n=6), and right and left cervical spine changes in 17.64% (n=3). These animals presented LPL lameness in 52.94% (n=9) and RPL lameness in 47.05% (n=8).

Figure 4 - Pelvic limb lameness associated with cervical and thoracolumbar clinical and ultrasonographic changes group. (A e B) Mild myopenia is observed in the right cervical region (A) and left cervical region (B). (C e D) Mild myopenia is observed in the right thoracolumbar region (C) and left thoracolumbar region (D). (E) Cross-sectional ultrasonography. Medial to the left and lateral to the right. The joint space between C6 and C7 (white arrow) is observed, with slight irregularity of the articular facet of C6 and C7 on the right side. (F) Cross-sectional ultrasonography. Medial to the left and lateral to the right. The joint space between C5 and C6 is observed with the presence of articular facet irregularity of C5 (white arrow) associated with bone irregularity of the transverse process of C6 (blue arrow) on the right side. (G) Cross-sectional ultrasonography. Medial to the left and lateral to the right. Joint space of L1 and L2 showing marginal osteophytes (white arrow) on the right side. (H) Cross-sectional ultrasonography. Medial to the left and lateral to the right. The joint space between L3 and L4 on the right side shows small osteophytes (white arrow).



Source: Authors (2023).

Figure 5 - Pelvic limb lameness associated with cervical and thoracolumbar clinical and ultrasonographic changes group. (A) The straight-line evaluation demonstrated mild to moderate left pelvic limb elevation lameness. (B) The left circle evaluation showed impact lameness of the right thoracic limb and a left pelvic limb elevation lameness, while the right circle showed no lameness.



Source: Authors (2023).

3.4 Thoracic and pelvic lameness without ultrasound changes of the axial skeleton group

In this group of eighteen animals evaluated, 5.88% (n=1) had a history of injury to the proximal insertion of the interosseous III muscle in the LPL, 5.88 (n=1) presented superficial digital flexor tendon tendinopathy in both thoracic limbs, 5.88 (n=1) underwent a palmar digital neurectomy due to podotrochlear syndrome, and 5.88% (n=1) presented laceration of the dorsal aspect of the hoof wall. All animals in this group showed clinical changes in the axial skeleton as previously mentioned, with thoracic and pelvic lameness. However, none of the animals presented US changes in the cervical and thoracolumbar spine.

In the clinical evaluation of the cervical and thoracolumbar spine, 72.22% (n=13) presented grade 1 changes, 11.11% (n=2) presented grade 2 changes, and 16.66% (n=3) showed grade 3 changes. Of these animals, 72.22 (n=13) of the physical changes comprised the right and left cervical and thoracolumbar spine, 22.22% (n=4) presented changes of the left cervical and right and left thoracolumbar spine segments, and 5.55% (n=1) demonstrated changes of the right cervical and right and left thoracolumbar spine segments.

In the objective lameness evaluation, 27.77% (n=5) of the animals presented contralateral RTL and LPL lameness, characterized by 5.55% (n=1) RTL moderate impact and LPL severe push off type of lameness; 5.55% (n=1) RTL moderate support and LPL moderate push off type of lameness; 5.55% (n=1) RTL moderate impact and LPL mild impact lameness; 5.55% (n=1) RTL mild impact and LPL moderate push off type of lameness, and 5.55% (n=1) RTL severe support and LPL severe elevation lameness. In addition, ipsilateral lameness characterized by mild impact RTL and mild elevation RPL lameness was observed in 5.55 (=1) and bilateral pelvic limb lameness demonstrated by moderate impact RPL and moderate push off type of LPL was observed in 5.55 (n=1) animals. Thoracic lameness of mild impact in 22.22% (n=4), moderate impact in 5.55% (n=1), and mild push off type of lameness in 5.55% (n=1) were also identified in this group. Regarding pelvic limb lameness, 5.55% (n=1) of mild impact, 11.11% (n=2) of moderate impact, 5.55% (n=1) of mild push off type of lameness, and 5.55% (n=1) of moderate push of lameness were observed in this group.

3.5 Spearman correlation

After performing the statistical Spearman correlation test, it was possible to identify a weak positive correlation between the objective evaluation of the appendicular skeleton and clinical evaluation of the axial skeleton ($r = 0.1$, $p > 0.05$). It was also observed weak positive correlation between the objective evaluation of the appendicular and ultrasound evaluation of the axial skeleton ($r = 0.1$, $p > 0.05$). There was also a positive but weak correlation ($r = 0.2$, $p > 0.05$) between the clinical evaluation and ultrasound evaluation of the axial skeleton (Table 1). However, it was impossible to consider the correlations statistically significant since the p-value was higher than the significance level of 5%.

Table 1 - Representation of the correlation between the objective assessment of the appendicular skeleton (response variable) in relation to the selected variables using Spearman's Correlation.

Evaluation	Objective	Clinical	Ultrasound
Objective	1	0.1 ^{ns}	0.1 ^{ns}
Clinical		1	0.2 ^{ns}
Ultrasound			1

Note: ^{ns} Not significant. Source: Authors (2023).

4. Discussion

This study showed that appendicular skeletal lameness is associated with clinical abnormalities as well as US changes of the axial skeleton in 92.1% of the evaluated population. As in humans, spinal problems in horses are also recurrent (Denoix, 1998). In addition, the strong association between lameness in horses and spinal problems is evident (Gómez-Álvarez et al., 2007a; Gómez-Álvarez et al., 2007b, Henson, 2018). Equine spinal pain and the association of neuromuscular dysfunction are manifested by various clinical and behavioral changes, mostly involving reduced performance (Dyson, 2011). Lameness and thoracolumbar pain may be related (Mayaki et al., 2019; Greve & Dyson, 2013) however, it can be challenging to establish whether the movement of the thoracolumbar spine is primarily altered by thoracolumbar spine pain or whether it is secondary response to lameness of the appendicular skeleton (Greve et al., 2017; Mayaki et al., 2019; Findley & Singer, 2015; Zimmerman, Dyson & Murray, 2011; Melo & Ferreira 2021).

Osteoarthritis of the articular facets can lead to difficulty in lateralizing neck movements, rejection of obstacles in jumping events, or even primary neurological signs, such as motor incoordination of pelvic limbs (Carr & Maher, 2014). Neck stiffness can be considered a protective mechanism by the horse to avoid the pain that, may be associated with lameness especially those of thoracic limbs (Dyson, 2011). According to Derouen et al. (2016), osteoarthritis was observed by US evaluation in the articular space of the C5-C6 articular facets in 6/24 (25%) of the horses that presented C6 abnormality and 32/76 (42.1%) in horses without C6 changes. In the present research work osteoarthritis was diagnosed between C6 and C7 in 11/24 (45.8%) with an abnormality of C6 and 39/76 (51.3%) in horses with normal C6. The painful condition and stiffness of the neck can limit athletic potential, predisposing the secondary development of different changes (2). Abnormal findings of articular facets include irregular bone surface, bone rarefactions, osteophytes, synovial fluid accumulation, synovial membrane thickening, and increased articular margins. However, the significance of small osteophytes should be evaluated carefully (Berg et al., 2003). The correlation of clinical and US evaluations showed a weak correlation ($r = 0.2$, $p = 0.0741$), although they do not show a substantial degree of significance it is extremely important that assessment is preceded together. Another factor to be considered in this group is that 32.14% (n=9) concomitantly demonstrated asymmetries of the thoracic hooves,

pain on palpation of the sole, and distension of the dorsal articular recesses of the distal interphalangeal joint.

Spinal problems in horses can be of primary and/or secondary origin or combined with appendicular skeletal lameness. In this sense, Ricardi & Dyson (1993) recommend the examination of the cervical spine in horses with thoracic limb lameness that do not respond positively to diagnostic blocks, especially if there is pain or stiffness in the neck. The evaluation of the spine includes a thorough clinical examination with inspection, palpation, immobilization, and observation during movement (Denoix, 1999; Findley & Singer, 2015; Mayaki et al., 2019; Mayaki et al., 2020), and radiographic, ultrasound, thermography and nuclear scintigraphy (Findley & Singer, 2015; García-López, 2018; Mello & Ferreira, 2020; Masko et al., 2021).

It was observed that in all horses in the population evaluated that are regularly mounted, only 9.21% (n=9) showed an association between pelvic lameness and clinical and ultrasound changes of the thoracic axial segment, 28.57% (n=2) in the lumbar axial segment, and 42.85% (n=3) in the thoracolumbar spine segment. These data highlight the importance of the complete evaluation of the axial skeleton, including the cervical region for horses in saddle work. This result can also be observed in the pelvic lameness and cervical and thoracolumbar changes group that were observed in 22.37% (n=17) of the animals evaluated. Neck pain can cause reluctance to work, possibly caused by the type of training, trainer, rider, mouth changes, thoracic and pelvic limb lameness, and thoracolumbar spine pain (Dyson, 2011). Lameness and thoracolumbar pain may be related (Greve & Dyson, 2013) however, it can be challenging to establish whether the movement of the thoracolumbar spine is primarily altered by thoracolumbar spine pain or whether it is secondary to lameness (Greve et al., 2017). The experimental induction of pelvic limb lameness showed a load redistribution between thoracic and pelvic limbs (Weishaupt et al., 2004). Pelvic limb lameness indicated changes in thoracolumbar spine movement in approximately 50% of mounted horses (Greve & Dyson, 2013; Greve & Dyson, 2014a). Comparing the dimensions of the thoracolumbar spine between lameness and non-lameness horses, which were in regular work for one year, demonstrated small changes in the lameness horses, suggesting that situation results in decreased ability to use the axial muscles correctly (Greve & Dyson, 2015). The horses showed a deficient articular mobility in the clinical evaluation of the thoracolumbar spine, evidenced by the decrease in thoracolumbar extension and flexion movements. In addition, some horses presented discomfort on palpation of the thoracolumbar segment, characterized by behavioral manifestations such as kicking, change of limb support, and reluctance to the touch. According to Valberg (1999), signs of spinal stiffness, shortened trot, lameness of pelvic limbs, and inability to perform circles or work together are also indicative signs of changes in the thoracolumbar spine.

Greve et al. (2017) study demonstrate the asymmetric movement of the thoracolumbar spine was dependent on the presence of lameness. Asymmetries in the movement of the thoracolumbar region may explain why some horses have pelvic limb lameness (Greve & Dyson, 2013; Greve & Dyson, 2014a; Melo & Ferreira, 2021). Primary thoracolumbar pains may exist but, in some cases, may have been triggered by pelvic limb lameness (Dyson, 2010; Henson, 2018). Other previous studies have reported the association between thoracolumbar pain and lameness (Greve & Dyson, 2014b). First, there are horses with injuries of the thoracolumbar spine, which later trigger lameness of thoracic or pelvic limbs. Finally, there are horses with supposed or apparent spinal pain, with anatomopathological evidence that explains the occurrence of pain as anomaly formations of the thoracolumbar spine, characterized by scoliosis and lordosis, which may predispose to changes and, consequently, to painful processes (Jeffcott, 1999).

Objective evaluation has been widely used in the examination of equine lameness (Malive et al., 2013; Rhodin et al., 2015; Azevedo et al., 2019), showing to be more efficient and quicker in identifying subtle lameness when compared to subjective evaluation (McCracken et al., 2012) and force plates (Donnell et al., 2015). The Lameness Locator, a system used in this work, uses two unidirectional accelerometers responsible for identifying and quantifying asymmetry in the vertical

movement of the trunk between the left and right sides, thus identifying and quantifying lameness of appendicular origin (Keegan et al., 2003). Greve et al. (2017) used an objective evaluation system with multidirectional accelerometers, gyroscopes, and magnetometers, demonstrating a change in the range of thoracic lumbosacral flexion-extension motion, axial rotation, and lateral flexion in horses with appendicular lameness.

5. Conclusion

The associated evaluation of the axial and appendicular skeleton is of fundamental importance in the clinical routine to investigate musculoskeletal changes. This was demonstrated in the present study, where 68.42% (n=52) presented both clinical and US changes of the axial skeleton concomitantly with thoracic and/or pelvic lameness. The authors suggest that further studies be conducted, involving the combination of radiographic and ultrasonographic images of the appendicular and axial skeleton, as well as perineural blocks.

Conflict of interest

The authors declare that the research was conducted in the absence of any commercial or financial relationships that could be construed as a potential conflict of interest.

References

- Azevedo, M. S. A., De La Côte, F. D., Pozzobon, R., Dau, S. T. D., & Gallio, M. (2019). Objective evaluation versus subjective evaluation of flexion tests in the pelvic limb of horses. *Brazil Journal of Veterinary Research and Animal Science*.
- Berg, L. C., Nielsen, J. V., & Thoenner, M. B. (2003). Ultrasonography of the equine cervical region: a descriptive study in eight horses. *Equine Veterinary Journal*. 35:647–55.
- Carr, E. A., & Maher, O. (2014). Neurologic causes of gait abnormalities in the athletic horse. In: Hinchcliff KW, Kaneps A. J, Geor R. J. editors. *Equine Sports Medicine and Surgery*. (2th ed.), Saunders Elsevier. 503–526.
- Cohen, J. (1988). Statistical power analysis for the behavioural sciences. *Lawrence Erlbaum Association*, (2th ed.), Hillsdale.
- Denoix, J. M. (1998). Diagnosis of the cause of back pain in horses. In: *Proceedings of the Conference on Equine Sports Medicine and Science*. Cordoba. 97.
- Denoix, J. M. (1998). Diagnosis of the cause of back pain in horses. *Conference on Equine Sports Medicine and Science*, Wageningen, The Netherlands. 97:110.
- Denoix, J. M. (1999). Ultrasonographic evaluation of back lesions. *Veterinary Clinics of North America Equine Practice*. 15:131–159.
- Deroue, A., Spriet, M., & Aleman, M. (2016). Prevalence of anatomical variation of the sixth cervical vertebra and association with vertebral canal stenosis and articular process osteoarthritis in the horse. *Veterinary Radiology Ultrasound*. 57:253-258.
- Donnell, J. R., Frisbie, D. D., King, M. R., Goodrich, L. R., & Haussler, K. K. (2015). Comparison of subjective lameness evaluation, force platforms and na inertial-sensor system to identify mild lameness in an equine osteoarthritis model. *The Veterinary Journal*.
- Dyson, S. J. (2011). The Axial Skeleton In: Dyson, S. J., Ross, M. W., editors. *Diagnosis and Management of Lameness in the Horse*. (2th ed.), Saunders. 606-616.
- Dyson, S. (2010). Poor performance and lameness. In: Ross, M., Dyson, S., editors. *Diagnosis and management of lameness in the horse*. (2th ed.), Elsevier Saunders, St Louis: MO: Elsevier Saunders. 920-924.
- Findley, J., & Singer, E. (2015). Equine back disorders 1. *Clinical presentation, investigation and diagnosis*. In *Practice*. 37(9):456-467.
- García-López, M. J. (2018). Neck, back, and pelvic pain in sport horses. *Veterinary Clinics: Equine Practice*. 34(2):235–251. <https://doi.org/10.1016/j.cveq.2018.04.002>
- Gómez-Álvarez, C. B., Rhodin, M., Bobbert, M. F., Johnston, C., Roepstorff, L., Back, W., & Van Weeren, P. R. (2007a). Limb kinematics in horses with induced back pain. In: *The Biomechanical Interaction between Vertebral Column and Limbs in the Horse*. 71-85.
- Gómez-Álvarez, C. B., Wennerstrand, J., Bobbert, M. F., Lamers, L., Johnston, L., Back, W., & Van-Weeren, P. R. (2007b). The effect of induced forelimb lameness on thoracolumbar kinematics during treadmill locomotion. *Equine Veterinary Journal*. 39:197-201.
- Greve, L., & Dyson, S. (2013). An investigation of the relationship between hind limb lameness and saddle-slip. *Equine Veterinary Journal*. 45:570–577.

- Greve, L., Dyson, S., & Pfau, T. (2017). Alterations in thoracolumbosacral movement when pain causing lameness has been improved by diagnostic analgesia. *The Veterinary Journal*. 224:55-63.
- Greve, L., & Dyson, S. (2014). The interrelationship of lameness, saddle-slip and back shape in the general sports horse population. *Equine Veterinary Journal*. 46:687-694.
- Greve L., & Dyson S. (2015). A longitudinal study of back dimension changes over 1 year in sports horses. *Equine Veterinary Journal*. 203:65-73.
- Greve, L., & Dyson, S. (2014b). Saddle fit and management: an investigation of the association with equine thoracolumbar asymmetries horse and rider health. *Equine Veterinary Journal*. 47:415-421.
- Henson, F. M. D. (2018). *Equine Neck and Back Pathology: Diagnosis and Treatment*. (2a ed.), John Wiley & Sons Ltd.
- Jeffcott, L. B. (1999). Historical perspective and clinical indications. *Veterinary Clinics of North America Equine Practice*.
- Keegan, K. G., Macallister, C. G., Wilson, D. A., Gedon, C. A., Kramer, J., Yonezawa, Y., & Maki, H. (2012). Comparison of an inertial sensor system with a stationary force plate for evaluation of horses with bilateral forelimb lameness. *American Journal of Veterinary Research*. 73:368-374.
- Keegan, K. G., Arafat, S., Skubic, M., Wilson, D. A., & Kramer, J. (2003). Determination and differentiation (right vs left) of equine forelimb lameness using continuous wavelet transformation and neural network classification of kinematic data. *American Journal of Veterinary Research*. 64:1376-1381.
- Klide, A. M. (1984). Acupuncture for treatment of chronic back pain in the horse. *Acupuncture & Electrother Research*. 9(1):57-70. 10.3727/036012984816714848.
- Malive, S., Voute, L., Lund, D., & Marshall, J. F. (2013). An inertial sensor-based system can objectively assess diagnostic anaesthesia of the equine foot. *Equine Veterinary Journal*. 45:26-30.
- Martin, B. B., & Klide, A. M. (1997). Diagnosis and treatment of chronic back pain in horses. In: *Proceedings of the 43rd Annual Convention of the American Association of Equine Practitioners*, Denver. 310.
- Martin, P., Cheze, L., Pourcelot, P., Desquilbet, L., Duray, L., & Chateau, H. (2017). Effects of the rider on the kinematics of the equine spine under the saddle during the trot using inertial measurement units: Methodological study and preliminary results. *The Veterinary Journal*. 221:6-10.
- Masko, M., Borowska, M., Domino, M., Jasinski, T., Zdrojkowski, L., & Gajewski, Z. (2021). A novel approach to thermographic images analysis of equine thoracolumbar region: the effect of effort and rider's body weight on structural image complexity. *BMC Veterinary Research*. 17:2-12.
- Mayaki, A. M., Intan-Shameha, A. R., Noraniza, M. A., Mazlina, M., Adamu, L., & Abdullah, R. (2019). Clinical investigation of back disorders in horses: A retrospective study (2002-2017). *Veterinary World*. 12(3):377-381.
- Mayaki, A. M., Intan-Shameha, A. R., Noraniza, M. A., Mazlina, M., Adamu, L., & Abdullah, R. (2020). Clinical assessment and grading of back pain in horses. *Journal of Veterinary Science*. 21(6):1-10.
- Mccracken, M. J., Kramer, J., Keegan, K. G., Lopes, M., Wilson, D. A., Reed, S. K., Lacarrubba, A., & Rasch, M. (2012). Comparison of an inertial sensor system of lameness quantification with subjective lameness evaluation. *Equine Veterinary Journal*. 44: 652-656.
- Melo, U. P. & Ferreira, C. (2020). Lombalgia em equinos de vaquejada: achados clínicos, ultrassonográficos e resultados terapêuticos de 25 casos. *Revista Brasileira de Ciência Veterinária*. 27(4):193-199, dez.
- Ricardi, G., & Dyson, S. J. (1993). Forelimb lameness associated with radiographic abnormalities of the cervical vertebrae. *Equine Veterinary Journal*. 25:422-426.
- Rhodin, M., Roepstorff, L., French, A., Keegan, K. G., Pfau, T., & Egenvall, A. (2015). Head and pelvic movement asymmetry during lungeing in horses with symmetrical movement on the straight. *Equine Veterinary Journal*. 1-6.
- Valberg, J. S. (1999). Spinal muscle pathology. *Veterinary Clinics of North America Equine Practice*. 15:87-96.
- Weishaupt, M. A., Wiestner, T., Hogg, H. P., Jordan, P., & Auer, J. A. (2004). Compensatory load redistribution of horses with induced weight bearing hind limb lameness trotting on a treadmill. *Equine Veterinary Journal*. 36:727-733.
- Zimmerman, M., Dyson, S., & Murray, R. (2011). Close, impinging and overriding spinous processes in the thoracolumbar spine: The relationship between radiological and scintigraphic findings and clinical signs. *Equine Veterinary Journal*. 44(2):178-184.