

## **Extraction by the repulsion method of the fourth maxillary premolar (Triadan 108) in a standing Crioulo breed horse: Case report**

**Exodontia pelo método de repulsão do quarto pré molar maxilar (Triadan 108) em estação de um equino da raça Crioula: Relato de caso**

**Extracción por el método de repulsión del cuarto premolar maxilar (Triadan 108) en estación de un caballo Criollo: Reporte de caso**

Received: 08/27/2024 | Revised: 09/03/2024 | Accepted: 09/04/2024 | Published: 09/08/2024

### **Tainã Kuwer Jacobsen**

ORCID: <https://orcid.org/0000-0002-3497-4175>  
Federal University of Rio Grande do Sul, Brazil  
E-mail: [tainajacobsen@gmail.com](mailto:tainajacobsen@gmail.com)

### **Luana Karolczak Franco**

ORCID: <https://orcid.org/0009-0008-1904-5045>  
Federal University of Rio Grande do Sul, Brazil  
E-mail: [luanakarolczak@gmail.com](mailto:luanakarolczak@gmail.com)

### **Anelise da Costa Silva**

ORCID: <https://orcid.org/0009-0007-1883-2859>  
Federal University of Rio Grande do Sul, Brazil  
E-mail: [costaanelise5@gmail.com](mailto:costaanelise5@gmail.com)

### **Marcelo Meller Alievi**

ORCID: <https://orcid.org/0000-0002-4081-4362>  
Federal University of Rio Grande do Sul, Brazil  
E-mail: [marcelo.alievi@ufrgs.br](mailto:marcelo.alievi@ufrgs.br)

### **Eduardo Raposo Monteiro**

ORCID: <https://orcid.org/0000-0001-8672-7830>  
Federal University of Rio Grande do Sul, Brazil  
E-mail: [eduardo.monteiro@ufrgs.br](mailto:eduardo.monteiro@ufrgs.br)

### **Grasiela De Bastiani**

ORCID: <https://orcid.org/0000-0002-4748-7560>  
Federal University of Rio Grande do Sul, Brazil  
E-mail: [grasiela.bastiani@ufrgs.br](mailto:grasiela.bastiani@ufrgs.br)

### **Abstract**

The objective of this article is to describe the case of a 4-year-old castrated male Crioulo breed horse diagnosed with fractures in the right and left fourth maxillary premolars (Triadan 108 and 208), along with the dental repulsion technique used and its clinical progress. Clinical and radiographic examination of the oral cavity revealed lesions on the buccal aspect of the maxillary teeth and the lingual aspect of the mandibular teeth, due to excessively sharp enamel points (ESEP) on the premolars and molars, radiolucent areas in the tooth root, loss of anatomical conformation (dorsal displacement of the crown), and fracture with lateral displacement of the fragment in the Triadan 108 and 208 dental elements. The patient underwent extraction using the dental repulsion method of the Triadan 108 dental element, curettage of the alveolar bone, and partial protection of the space with gauze and an acrylic resin plug. Systemic therapy included broad-spectrum antibiotic therapy, anti-inflammatories, analgesics, topical wound dressings, and periodic plug changes. The patient was discharged after 44 days of hospitalization, with complete intraoral and surgical wound healing. The dental repulsion method may be an effective and safe option for extracting fractured maxillary premolars in horses. Some complications were observed during treatment, but a satisfactory result was achieved regarding healing and return to a normal diet.

**Keywords:** Extraction; Tooth repulsion; Premolar; Triadan.

### **Resumo**

O objetivo deste artigo é descrever o caso de um equino, macho castrado, da raça Crioula, de 4 anos de idade, diagnosticado com fraturas no quarto pré-molar maxilar direito e esquerdo (Triadan 108 e 208), juntamente com a técnica de repulsão dentária utilizada e seu progresso clínico. No exame clínico e radiográfico da cavidade oral, foram evidenciadas lesões no aspecto bucal dos dentes maxilares e no aspecto lingual dos dentes mandibulares, devido a pontas excessivamente afiadas de esmalte (ESEP) nos pré-molares e molares, áreas radioluscentes na raiz dentária, perda da

conformação anatômica (deslocamento dorsal da coroa) e fratura com deslocamento lateral do fragmento nos elementos dentários Triadan 108 e Triadan 208. O paciente foi submetido à extração pelo método de repulsão dentária do elemento dentário Triadan 108, curetagem do osso alveolar e proteção parcial do espaço com gaze e um plug de resina acrílica autopolimerizável. A terapia sistêmica incluiu antibioticoterapia de amplo espectro, anti-inflamatórios, analgésicos, curativos tópicos da ferida e trocas periódicas do plug. O paciente recebeu alta após 44 dias de hospitalização, com cicatrização completa intraoral e da ferida cirúrgica. O método de repulsão dentária pode ser uma opção eficaz e segura para a extração de dentes pré-molares maxilares fraturados em equinos. Foram observadas algumas complicações durante o tratamento, mas foi alcançado um resultado satisfatório em relação à cicatrização e retorno a uma dieta ampla.

**Palavras-chave:** Extração; Repulsão dentária; Pré-molar; Triadan.

### Resumen

El objetivo de este artículo es describir el caso de un equino macho castrado, de la raza Criolla, de 4 años de edad, diagnosticado con fracturas en los cuartos premolares maxilares derecho e izquierdo (Triadan 108 y 208), junto con la técnica de repulsión dental utilizada y su progreso clínico. En el examen clínico y radiográfico de la cavidad oral, se evidenciaron lesiones en el aspecto bucal de los dientes maxilares y en el aspecto lingual de los dientes mandibulares, debido a puntas excesivamente afiladas de esmalte (PEAE) en los premolares y molares, áreas radiolúcidas en la raíz dental, pérdida de la conformación anatómica (desplazamiento dorsal de la corona) y fractura con desplazamiento lateral del fragmento en los elementos dentarios Triadan 108 y 208. El paciente fue sometido a la extracción por el método de repulsión dental del elemento dentario Triadan 108, curetaje del hueso alveolar y protección parcial del espacio con gasas y un tapón de resina acrílica autopolimerizable. La terapia sistémica incluyó antibióticos de amplio espectro, antiinflamatorios, analgésicos, curativos tópicos de la herida y cambios periódicos del tapón. El paciente fue dado de alta después de 44 días de hospitalización, con una cicatrización completa intraoral y de la herida quirúrgica. El método de repulsión dental puede ser una opción eficaz y segura para la extracción de premolares maxilares fraturados en equinos. Se observaron algunas complicaciones durante el tratamiento, pero se logró un resultado satisfactorio en cuanto a la cicatrización y el retorno a una dieta normal.

**Palabras clave:** Extracción; Repulsión dental; Premolar; Triadan.

## 1. Introduction

Horses are classified as hypsodont animals; therefore, they exhibit significant development of the crown of the premolar (PM) and molar (M) teeth, as well as continuous growth of these teeth (2 to 3 mm per year). Over the years, changes in the management of these animals, including a consequent reduction in grazing time throughout the day, combined with the aforementioned characteristics, predispose horses to dental alterations (Straioto et al., 2018). Dental fractures and periapical abscesses can be of idiopathic, infectious, or traumatic origin, requiring surgical intervention for the extraction of the affected tooth (Dacre et al., 2007). Different extraction techniques are described and reported; therefore, the method of choice will depend on the clinical presentation and complications (Dixon et al., 2005; Dixon et al., 2008; Dixon et al., 2012; Dixon et al., 2020; Earley et al., 2020). The dental repulsion technique is associated with several intra- and postoperative complications; however, it is a surgical treatment option for premolar teeth (Tremaine et al., 2011).

The objective of this article is to describe the case of a 4-year-old castrated Criollo male horse diagnosed with fractures of the fourth maxillary premolar on both the right and left sides (Triadan 108 and 208), along with the dental repulsion technique used and its clinical progress.

## 2. Methodology

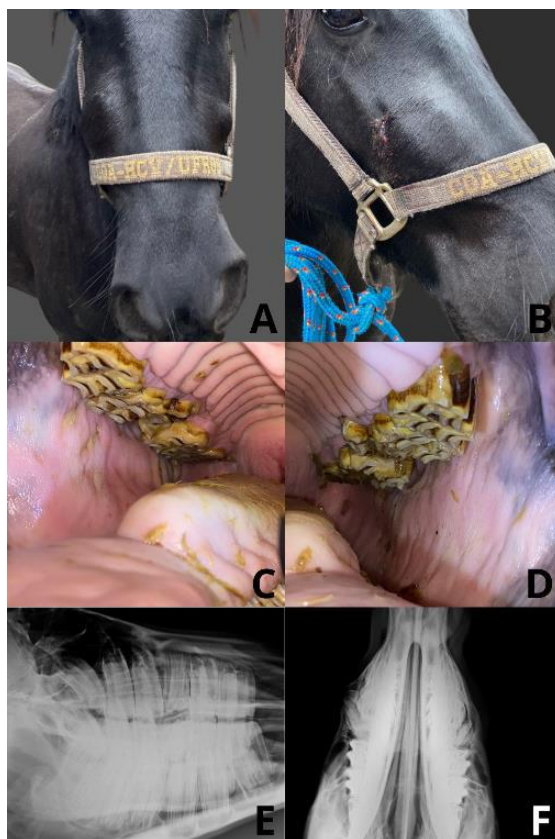
This article presents a clinical case report, which is a detailed description of a single clinical case, highlighting the patient's history, nutritional management, clinical and radiographic findings, surgical treatment, and evolution (Pereira et al., 2018). The Free and Informed Consent Form (FICF) was obtained before the commencement of data collection and the preparation of the report.

### 3. Case Report

A 4-year-old, 400 kg, castrated male Criollo horse, raised under an extensive feeding regime, was referred to the Large Animal Clinic of the Veterinary Teaching Hospital, located in southern Brazil (latitude -30.0759715298907, longitude -51.12703974879086), with a clinical complaint of bilateral enlargement in the rostral maxillary region, progressively evolving over 6 months. Upon physical examination, the horse exhibited a heart rate (HR) of 32 beats per minute (bpm), a respiratory rate (RR) of 16 breaths per minute (bpm), normochromic oral mucosa with a capillary refill time (CRT) of 2 seconds, and normal, progressive motility in all four abdominal quadrants, with no notable abnormalities.

Upon facial evaluation, bilateral enlargement was observed in the region of the right and left rostral maxillary bones. The right side was more pronounced, with a drainage point characterized by a fistula, discharging purulent content (Figures 1A and 1B). The horse was then subjected to intravenous sedation with detomidine 1% (Detomidin®, Syntec do Brasil Ltda, São Paulo, Brazil) at a dose of 20 µg/kg for a dental evaluation. Prior to the evaluation, the oral cavity was rinsed with a solution of water and chlorhexidine, and a mouth gag was applied. Upon examination, the horse was found to have lesions on the buccal surfaces of the maxillary teeth and the lingual surfaces of the mandibular teeth, caused by excessive sharp enamel points (ESEP) on the premolars and molars. Additionally, fractures with medial displacement of fragments were observed in the right fourth maxillary premolar (Triadan 108) and left fourth maxillary premolar (Triadan 208). Due to wear failure of the contralateral teeth, a step was observed in the right fourth mandibular premolar (Triadan 408) and left fourth mandibular premolar (Triadan 308) (Figures 1C and 1D).

**Figure 1** - Clinical evaluation of a horse's face showing bilateral enlargement in the region of the rostral maxillary bone (A) and a drainage point characterized by a fistula on the right side of the rostral maxillary bone (B). Evaluation of the horse's oral cavity revealed lesions on the buccal surface of the maxillary teeth and the lingual surface of the mandibular teeth, with excessive sharp enamel points (ESEP) on the premolar and molar teeth. Fractures with medial displacement of fragments were observed in the Triadan 108 and 208 teeth (C and D). A radiographic study of the maxilla in a lateral-lateral projection showed a radiolucent area at the root of the Triadan 108 tooth, associated with loss of anatomical conformation and dorsal displacement of the crown (E). Another radiographic study in a dorsoventral projection of the maxillary bone revealed fractures with lateral displacement of the Triadan 108 and 208 dental elements (F).



Source: Authors (2023).

To test the communication between the fistula and the fracture of the Triadan 108 dental element, an extender was connected to the wound entrance, and by applying a physiological solution, the communication between them was confirmed.

The left/right lateral-lateral and left/right oblique lateral-lateral radiographic study of the maxillary bone revealed the presence of a radiolucent area at the root of the right and left fourth maxillary premolars (Triadan 108 and 208), associated with loss of their anatomical conformation and dorsal displacement of the clinical crown (Figure 1E). A diastema was observed between the right fourth maxillary premolar (Triadan 108) and the first maxillary molar (Triadan 109), as well as between the left fourth maxillary premolar (Triadan 208) and the first left maxillary molar (Triadan 209). In the dorsoventral projection of the maxillary bone, a fracture with lateral displacement of the Triadan 108 and 208 dental elements was observed (Figure 1F).

Initially, the patient underwent odontoplasty to address the ESEP, steps, and alignment of the dental arcade. Subsequently, it was decided to clean the fractured teeth and fistula with a 1% iodized physiological solution, and the right fourth maxillary premolar was protected with a Cysne-type gypsum bandage (Cremer S.A, Santa Catarina, Brazil) soaked in water and a penicillin-based antibiotic (Agrosil PPU®, Vansil Indústria Comércio e Representações Ltda, São Paulo, Brazil) until the time of the surgical procedure.

Due to the complexity of the alterations and the presence of two dental fractures, a more conservative treatment approach was chosen. Therefore, only the extraction of the right fourth maxillary premolar (Triadan 108) was performed. The dorsal displacement of the tooth, combined with the lack of a clinical crown for extractor placement, determined that the best technique for extraction was by dental repulsion in the station.

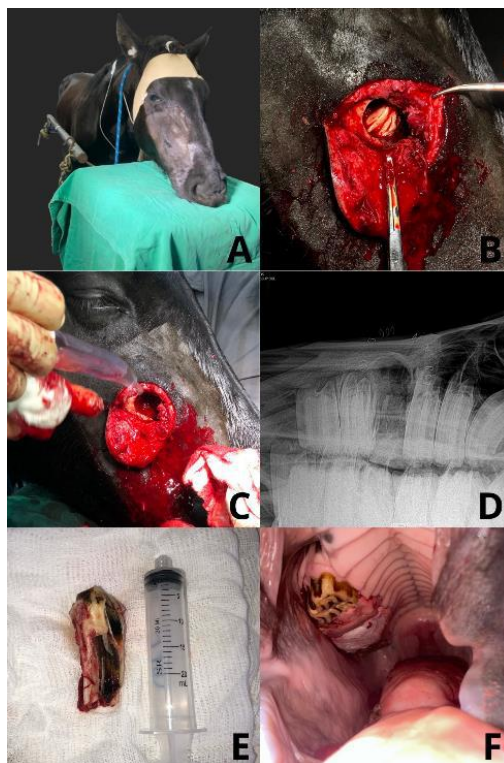
Before the surgical procedure, the horse was administered pre-anesthetic medication consisting of acepromazine 1% (Apromazin®, Syntec do Brasil Ltda, São Paulo, Brazil) at a dose of 0.03 mg/kg, combined with detomidine 1% (Detomidin®, Syntec do Brasil Ltda, São Paulo, Brazil) at a dose of 10 µg/kg. Intraoperative maintenance was performed through continuous infusion of morphine sulfate at a dose of 0.05 mg/kg/hour, along with 1% detomidine (Detomidin®, Syntec do Brasil Ltda, São Paulo, Brazil) at a dose of 8 to 12 µg/kg/hour, varying according to the clinical evaluation of the patient (Figure 2A). A maxillary nerve block was performed using a caudolateral approach to the zygomatic process with an 18g x 90mm spinal needle, and a total volume of 20 ml of 7.5 mg/ml ropivacaine hydrochloride (ROPi®, Cristália Produtos Químicos e Farmacêuticos Ltda, Porto Alegre, Brazil) was administered.

Subsequently, the patient underwent oral cavity lavage with a chlorhexidine-based solution, followed by wide trichotomy of the right rostral maxillary region and surgical antisepsis of the area with a 10% iodine degerming solution and 70% alcohol.

The dental root of the right upper fourth premolar (Triadan 108) is located caudal to the facial crest and ventral to the infraorbital foramen. Therefore, the surgical site was determined based on anatomical descriptions and guided by radiographic images. Subsequently, an elliptical incision was made, and the skin and subcutaneous tissue were reflected. An osteotomy of the right rostral maxillary bone was performed using a trephine, guided by radiographic images until the tooth root was exposed (Figure 2B). With the assistance of a dental hammer and retrograde pins, the periodontal ligament was ruptured, and alveolectomy was performed around the dental root, followed by the complete extraction of the Triadan 108 dental element into the oral cavity (Figures 2C and 2E) without fragmentation. At the end of the surgical procedure, a lateral-lateral radiographic study of the maxillary bone was repeated to confirm complete extraction without retention of fragments (Figure 2D).

Regarding the intraoral orifice resulting from the extraction, curettage of the alveolar bone was performed, and partial protection of the space was achieved with gauze and a self-polymerizing acrylic resin plug (Blue Dent®, Blue Dent Dental, São Paulo, Brazil). This packing aimed to prevent food accumulation and assist in granulation tissue formation (Figure 2F).

**Figure 2** - Positioning of the horse in the station before the surgical procedure and after maxillary nerve block and intravenous sedation (A). Exposure of the Triadan 108 dental root after osteotomy of the right rostral maxillary bone (B). A moment after the repulsion of the Triadan 108 dental element (C). Radiographic study of the maxilla in a lateral-lateral projection, showing complete extraction of the Triadan 108 tooth without retention of bone fragments (D). Extracted Triadan 108 dental element (E). The oral cavity of the horse after extraction and application of the acrylic resin plug to protect the orifice (F).



Source: Authors (2023).

Due to the severe contamination from the tooth root, the bone flap was not repositioned, and the skin was sutured using 2-0 nylon in an interrupted simple pattern, along with the application of staples. A drain was placed and kept in position for 5 days (Figure 3A).

Systemic treatment consisted of Metronidazole 400 mg at a dose of 25 mg/kg, PO, twice daily (BID) for 5 days; Gentamicin 10% (Pangram®, Rhobifarma Indústria Farmacêutica Ltda, São Paulo, Brazil) at a dose of 6.6 mg/kg, IV, once daily (SID) for 7 days; Penicillin (Pentabiótico® 6,000,000 IU, Zoetis Indústria de Produtos Veterinários Ltda, São Paulo, Brazil) at a dose of 40,000 IU/kg, IM, single dose; Dipyrone 500 mg/ml (Hypofarma, Minas Gerais, Brazil) at a dose of 25 mg/kg, IV, BID, for 5 days; and Flunixin Meglumine (Flumax®, JA Saúde Animal, São Paulo, Brazil) at a dose of 1.1 mg/kg, IV, SID, for 5 days.

For the topical dressing, daily cleaning of the stitches with saline solution and the application of cryotherapy were performed for 7 days. The drain was removed after 5 days due to the small amount of recovered content. The first change of the acrylic plug occurred 48 hours after the surgical procedure, under intravenous sedation with detomidine 1% (Detomidin®, Syntec do Brasil Ltda, São Paulo, Brazil) at a dose of 20 µg/kg, with a mouth opener positioned. Initial formation of granulation tissue was observed (Figure 3B); however, communication with the fistula was still evident. Therefore, partial protection of the space was maintained with gauze and a self-polymerizing acrylic resin plug (Blue Dent®, Blue Dent Dental, São Paulo, Brazil).

Five days after the second plug replacement, the patient underwent a new sedation for oral cavity evaluation. Due to the complexity of removing the acrylic, a new dressing with a Cysne-type gypsum bandage plug soaked in penicillin and water was

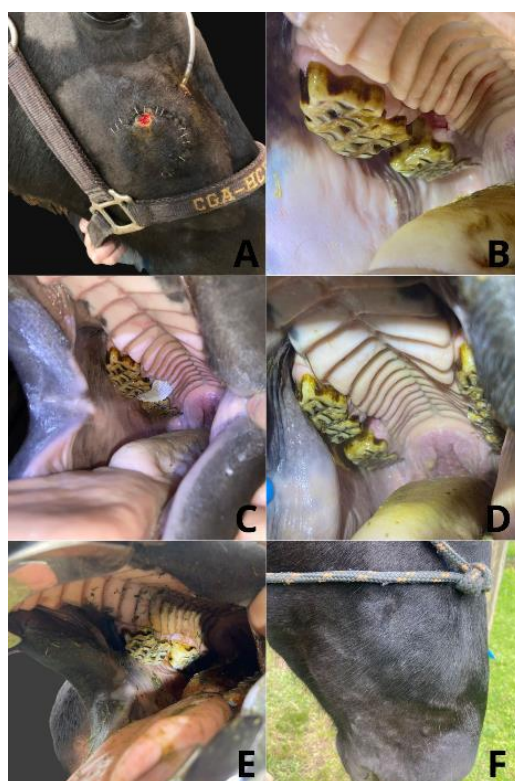


used to protect the orifice (Figure 3C). During each subsequent oral cavity evaluation and plug replacement, the hole and fistula were cleaned using a probe and 5% iodized physiological solution, with intervals typically ranging between 48 to 96 hours (Figure 3D).

Ten days after the surgical procedure, the stitches and staples were removed, and daily wound cleaning continued with a 5% iodized physiological solution and the application of sodium rifamycin spray (Rifotrat®, Natulab Laboratório Farmacêutico, Bahia, Brazil).

The patient was discharged after 44 days of hospitalization, with complete healing of both the intraoral and surgical wounds (Figures 3E and 3F). Due to the complexity of the case and the presence of significant alterations in other teeth, biannual follow-up for odontoplasty was recommended.

**Figure 3** - Surgical wound and drain located in the region of the right rostral maxillary bone after extraction (A). Evaluation of the oral cavity and plug replacement 48 hours after extraction (B). Evaluation of the oral cavity and plug replacement 7 days after extraction, and application of a gypsum bandage plug type Cysne (C). Evaluation of the oral cavity 30 days after extraction (D). Evaluation of the oral cavity 44 days after extraction, showing complete healing and medical discharge (E). Evaluation of the face and region of the right rostral maxillary bone, showing complete healing of the surgical wound and fistula, and medical discharge (F).



Source: Authors (2023).

#### 4. Discussion

Various dental diseases can predispose horses to tooth fractures, such as occlusal fissures, dental arch malocclusion, incorrect dental wear, periapical abscesses, and caries. Other factors, including the type of pasture provided, trauma from accidents, and iatrogenic causes, can also contribute (Tremaine, 2013; Pollaris et al., 2020). The case described had a history of an extensive diet based on Annoni grass and no regular dental check-ups. Therefore, it is believed that these factors may be strongly associated with the observed alterations in the patient. *Eragrostis plana* (Annoni grass) is characterized as a fibrous and

nutritionally poor plant of African origin that has become invasive in the southern region of the country. This plant is directly associated with excessive abrasion and incorrect dental wear in horses (Leite et al., 2019).

The clinical presentation of horses with dental abnormalities depends on the severity, duration of evolution, and temperament. Signs such as behavioral changes, decreased athletic performance, reaction to the bit, decreased body condition score, nasal discharge, foul odor in the oral cavity, swelling in the mandible or maxilla region, and the presence of draining fistulas can be observed (Laukkanen et al., 2023). In the present case report, the aforementioned clinical signs were evident, such as bilateral swelling in the maxillary region and a draining fistula on the right side. The horse was not used in athletic or working activities, and there were no reports of decreased performance or behavioral changes. However, the primary complaint from the owner was related to the significant swelling in the maxillary region and the drainage point.

The continuous growth of premolar (PM) and molar (M) teeth, combined with lateralized chewing movements and changes in feeding management, predisposes horses to dental abnormalities, which should be periodically corrected. Odontoplasty also acts preventively, reducing the incidence of tooth fractures compared to issues such as excessive sharp enamel points (ESEP), hooks, ramps, steps, and malocclusions (Straioto et al., 2018). In this case, the evaluation of the oral cavity and history-taking revealed that dental malocclusion, grazing on fibrous and nutritionally poor grass, and the absence of periodic odontoplasty led to significant dental abnormalities. Consequently, ESEP in PM and M teeth, diastemas, periapical abscesses, steps, and fractures in the Triadan 108 and 208 were observed.

To minimize complications following tooth extraction, the intraoral technique is generally preferred and should be attempted first to loosen the periodontal ligament (Easley et al., 2013; O'Leary et al., 2011). Tremaine (2013) notes that in cases of advanced caries, reduced dental crowns, or pre-fractured teeth, where intraoral extraction is not feasible, alternative methods should be considered. In the present case, radiographic evaluation revealed a lateral sagittal fracture of the Triadan 108 dental element associated with dorsal displacement, which made it impossible to use a dental extractor on the dental crown. Due to the prolonged duration of the condition and severe contamination of the dental root, which predisposed to fragmentation during extraction, the method of dental repulsion in station was chosen.

The technique of dental repulsion in the station was less commonly reported in the past, with most procedures performed in recumbency under general anesthesia (18/19) due to its various complications (Pollaris et al., 2020). Currently, detailed descriptions of this extraction method and nerve block techniques that allow it to be performed in stations are available (Earley et al., 2020; Tremaine, 2007).

The mucosa of the paranasal sinuses and maxillary teeth are innervated by the maxillary nerve, which continues through the infraorbital foramen as the infraorbital nerve. Three approaches for maxillary nerve block are described: lateral, caudolateral, and supraorbital (Tremaine, 2007). The sedation protocol based on continuous infusion of detomidine 1% and morphine, combined with maxillary nerve block via the caudolateral approach, proved effective for performing dental repulsion in the station. During the surgical procedure, two applications of morphine bolus and one application of detomidine bolus were necessary due to the maneuvers performed and the clinical evaluation of the patient's analgesia. No major intraoperative or postoperative complications were observed.

The surgical approach described for fractured maxillary premolar teeth involves several critical steps for successful execution. Dental repulsion requires intraoperative radiographic monitoring with radiopaque markers to plan the exact access site, followed by osteotomy and alveolectomy with trephines (Earley et al., 2020). The dental root and periodontal ligament covering the reserve crown are then visualized. After resection, this allows for the elevation and extraction of the affected tooth, either into the oral cavity or through the osteotomy site (Earley et al., 2020; Tremaine, 2007). The repulsion technique successfully extracted the Triadan 108 tooth without fragmentation or complications. However, due to severe periodontal



contamination, it was not possible to reposition the bone flap.

Dixon (2019) describes that the treatment for oro-maxillary fistulas depends on proper tooth extraction, ensuring no bone fragments are retained and avoiding alveolar infection, which could delay the healing process. To assist in granulation tissue formation and prevent food from lodging in the fistula, which can further delay healing, various treatment methods are detailed in the literature. Hawkes et al. (2008) reported success in treating fistulas secondary to diastemas and dental fractures through alveolar curettage, removal of food and secretions, and closure of the fistula with polymethylmethacrylate (acrylic). Hevesi et al. (2018) described using silicone plugs anchored with gauze for the treatment of oro-maxillary fistulas, with a duration of 6 months until total recovery of the animal. Storms et al. (2019) reported two cases of oro-maxillary and oro-cutaneous fistulas, where the treatment involved using cerclage wire in an "8" shape between the adjacent teeth to the fistula site. This cerclage wire serves as a support for the subsequent temporary insertion of polymethylmethacrylate until granulation tissue formation and closure. Tremaine and Dixon (2001) highlight the use of dental wax or acrylic bone cement, while Schumacher and Brink (2011) suggest covering the oral aspect of the fistula with a mucoperiosteal flap or transposed facial muscle.

Following the tooth extraction procedure in this case, curettage and debridement of the alveolar bone were performed, along with irrigation with saline solution to ensure wound cleanliness. Subsequently, new radiographic images were obtained to confirm that no fragments could impede or delay the granulation process. At the end of the procedure, it was decided to use gauze and acrylic for partial protection of the orifice and to assist in the formation of the alveolar plug.

Caramello et al. (2020) compared dental extraction methods and their complications in horses. The retrospective study showed that the tooth repulsion technique was associated with a 42% complication rate (n=19). These complications included damage to adjacent teeth, postoperative sinusitis, dental fragmentation, regional nerve injury, bleeding, and delayed alveolar granulation. Other studies have also linked dental repulsion with complications such as retained dental root, damage to the alveolar bone of adjacent teeth, fistula formation, palatal deviation, delayed healing, and failure of the alveolar plug (Coomer et al., 2011; Earley et al., 2013).

The reported case presented complications related to the removal and replacement of acrylic resin plugs. During the molding process, it was observed that the material caused mucosal irritation due to heat, and the removal/replacement procedures required rough maneuvers that also led to mucosal injuries. Therefore, starting with the third plug replacement, a plaster bandage was used to protect the orifice. Due to poor adhesion of the plaster to the mucosa and recurrent plug detachment, several dressing changes under sedation were performed during hospitalization, typically every 48 to 96 hours.

The severe contamination of the tooth root, which prevented the repositioning of the bone flap and led to frequent secretion production through the oro-maxillary fistula, delayed the healing of the surgical wound. Complete healing of the skin and fistula was achieved only 16 days after the extraction. Similarly, 44 days of hospitalization and daily care were required for the complete granulation of the orifice resulting from the dental avulsion and for medical discharge. The systemic and topical treatments, as well as the constant replacement of plugs and irrigation of the fistula, were essential for the success of the case.

The severe contamination, chronicity of the case, extraction method, and complications described in this report align with the literature (Caramello et al., 2020). However, the reported complications were managed effectively throughout the treatment, and no additional surgical interventions were necessary. Regarding postoperative comfort, the patient required only five days of analgesic support, including dipyrone and flunixin meglumine, and resumed normal feeding from the offered pasture.

Given the specifics of this case, it is recommended that the patient undergo regular dental check-ups due to the fracture located in Triadan 208 and the conformational alterations observed. Additionally, it is important to ensure that the equine is provided with higher-quality grass.

## 5. Conclusion

The technique of tooth repulsion in standing sedation can be an effective and safe option for extracting fractured maxillary premolar teeth in horses. While some complications were observed during the treatment, a satisfactory outcome was achieved in terms of healing and return to an extensive feeding regime. The authors suggest conducting future studies to explore the surgical technique and materials used for space coverage following tooth extraction.

## References

- Caramello, V., Zarucco, L., Foster, D., Boston, R., Stefanovski, D., & Orsini, J. A. (2020). Equine cheek tooth extraction: comparison of outcomes for five extraction methods. *Equine Veterinary Journal*, 52(2), 181-186. 10.1111/evj.13150
- Coomer, R. P., Fowke, G. S., & McKane, S. (2011). Repulsion of maxillary and mandibular cheek teeth in standing horses. *Veterinary Surgery*, 40(5), 590-595. 10.1111/j.1532-950X.2011.00819.x
- Dacre, I., Kempson, S., & Dixon, P. M. (2007). Equine idiopathic cheek teeth fractures. Part 1: pathological studies on 35 fractured cheek teeth. *Equine Veterinary Journal*, 39(4), 310-318. 10.2746/042516407x182721
- Dixon, P. M., & Dacre, I. (2005). A review of equine dental disorders. *The Veterinary Journal*, 169(2), 165-187. 10.1016/j.tvjl.2004.03.022
- Dixon, P. M., & O'Leary, J. M. (2012). A review of equine paranasal sinusitis: medical and surgical treatments. *Equine Veterinary Education*, 24(3), 143-158. 10.1111/j.2042-3292.2011.00245.x
- Dixon, P. M., Hawkes, C., & Townsend, N. (2008). Complications of equine oral surgery. *Veterinary Clinics of North America: Equine Practice*, 24(3), 499-514. 10.1016/j.cveq.2008.10.001
- Dixon, P. M. (2020). Treatment of equine oro-nasal and oro-maxillary fistulae. *Equine Veterinary Education*, 32(9), 471-478. 10.1111/eve.13127
- Easley, J. T., & Freeman, D. E. (2013). New ways to diagnose and treat equine dental-related sinus disease. *Veterinary Clinics: Equine Practice*, 29(2), 467-485. 10.1016/j.cveq.2013.04.003
- Earley, E. T., & Galloway, S. S. (2020). Equine Standing Surgical Extraction Techniques. *The Veterinary Clinics of North America. Equine Practice*, 36(3), 575-612. 10.1016/j.cveq.2020.08.008
- Earley, E. T., Rawlinson, J. E., & Baratt, R. M. (2013). Complications associated with cheek tooth extraction in the horse. *Journal of veterinary dentistry*, 30(4), 220-235. 10.1177/0898756413030004
- Hawkes, C. S., Easley, J., Barakzai, S. Z., & Dixon, P. M. (2008). Treatment of oromaxillary fistulae in nine standing horses (2002–2006). *Equine Veterinary Journal*, 40(6), 546-551. 10.2746/042516408X322157
- Hevesi, A. T., Uto, D., Takacs, N., Lorincz, V., & Simhofer, H. (2019). Transmaxillary anchored silicon embedded gauze plug in the post-operative treatment of a large oromaxillary fistula caused by a supernumerary cheek tooth. *Equine Veterinary Education*, 31(11), 582-587. 10.1111/eve.12897
- Laukkanen, T., Karma, L., Virtala, A. M., Mykkänen, A., Pehkonen, J., Rossi, H., & Raekallio, M. (2023). Behavioral Signs Associated With Equine Cheek Tooth Findings. *Journal of Equine Veterinary Science*, 121, 104198. 10.1016/j.jevs.2022.104198
- Leite, C. T., Duarte, C. A., Mozzaquatro, F. D., Mistieri, M. L. A., Machado, I. R. L., Porciuncula, M. L., & Pereira, E. P. (2019). Survey of dental diseases in Crioulo breed horses reared in an extensive farming system. *Arquivo Brasileiro de Medicina Veterinária e Zootecnia*, 71(01), 21-27. 10.1590/1678-4162-10331
- O'Leary, J. M., & Dixon, P. M. (2011). A review of equine paranasal sinusitis. Etiopathogenesis, clinical signs and ancillary diagnostic techniques. *Equine Veterinary Education*, 23(3), 148-159. 10.1111/j.2042-3292.2010.00176.x
- Pereira A. S. et al. (2018). Metodologia da pesquisa científica. UFSM
- Pollaris, E., Broeckx, B. J., & Vlamincx, L. (2020). Occlusal fissures in equine cheek teeth: a prospective longitudinal in vivo study. *Frontiers in Veterinary Science*, 7, 604420. 10.3389/fvets.2020.604420
- Schumacher, J., & Brink, P. (2011). Treatment of horses for a facial or oral fistula. *Equine Veterinary Education*, 23(5), 242-248. 10.1111/j.2042-3292.2010.00183.x
- Straioto, KA, Silva, L. & Ribeiro, M. (2018). Odontologia equina-aspectos importantes. *Enciclopédia Da Biosfera*. 15(27), 10.18677/EnciBio\_2018A62
- Storms, N., Salciccia, A., de la Rebière de Pouyade, G., Evrard, L., & Grulke, S. (2020). Dental bridging as a treatment for large oral fistulae in two horses. *Equine Veterinary Education*, 32(9), 165-169. 10.1111/eve.13124
- Tremaine, W. H. (2007). Local analgesic techniques for the equine head. *Equine Veterinary Education*, 19(9), 495-503. 10.2746/095777307X207114
- Tremaine, W. H., & Dixon, P. M. (2001). A long-term study of 277 cases of equine sinonasal disease. Part 1: details of horses, historical, clinical and ancillary diagnostic findings. *Equine Veterinary Journal*, 33(3), 274-282. 10.2746/042516401776249615
- Tremaine, W.H et al. (2011) *Equine dentistry*. 3rd edition. Philadelphia: Saunders Elsevier. 331-341.
- Tremaine, H. (2013). Advances in the treatment of diseased equine cheek teeth. *Veterinary Clinics: Equine Practice*, 29(2), 441-465. 10.1016/j.cveq.2013.04.013