

Ventricular Tachycardia Associated with Non-Hodgkin's Lymphoma

Diego Chemello, Priscila Raupp-da-Rosa, Guilherme Teló, Nadine Clausell

Hospital de Clínicas de Porto Alegre - Universidade Federal do Rio Grande do Sul, Porto Alegre, RS - Brazil

Systemic non-Hodgkin's lymphoma can affect the myocardium, particularly in immunocompromised patients. When present, symptoms and signs are usually nonspecific, making the diagnosis of cardiac involvement very difficult before an autopsy. Ventricular arrhythmias are also unusual in this setting. We describe a case of secondary myocardial non-Hodgkin's lymphoma presenting with sustained monomorphic ventricular tachycardia and thickening of the basal interventricular septum. Complete remission of myocardial lesions was observed after completion of second-line chemotherapy treatment, without further recurrences of arrhythmias in eight months.

Introduction

Clinical heart involvement secondary to metastasis of malignant tumors is relatively unusual. Autopsy studies have shown up to 12% of cardiac involvement in all patients with malignancy, and most of them are asymptomatic. Systemic non-Hodgkin's lymphoma is one disease that can affect the myocardium, particularly in immunocompromised patients. The clinical presentation is usually nonspecific. The diagnosis of cardiac involvement can be difficult and requires high clinical suspicion. Ventricular arrhythmias are extremely unusual and only few cases have been described so far. These arrhythmias usually are symptomatic and associated with significant hemodynamic instability.

Case report

A 27-year-old female patient presented to the emergency department with sudden-onset palpitations and chest discomfort. Blood pressure was 68 x 40 mmHg and heart rate was 184 bpm. Physical examination also revealed an increased volume in the left breast and a diffuse abdominal mass. The 12-lead electrocardiogram (ECG) performed on the admission revealed a wide-complex tachycardia with

left-bundle branch block pattern and negative concordance in precordial leads (Figure 1A).

Based on the initial presentation, the diagnosis of monomorphic ventricular tachycardia was established and patient underwent electrical cardioversion to normal sinus rhythm. The ECG was repeated, showing normal sinus rhythm and no ST changes (Figure 1B). She was started on intravenous amiodarone infusion and then admitted to the intensive care unit. Investigation was negative for myocardial ischemia or pulmonary embolism. A transthoracic echocardiography (TTE) revealed normal left and right ventricular functions, moderate posterior pericardial effusion and thickening of the basal-septal myocardium, which was not present in previous examination performed one year before for investigation of shortness of breath during physical activities (Figure 2A). Clinical investigation revealed a medical history of acquired immunodeficiency syndrome (AIDS) due to HIV infection in the previous 12 months and initial CD4 count of 39 cells/mm³. Immediately after this diagnosis she was started on highly active antiretroviral therapy (HAART), which increased and stabilized CD4 cell counts to 89 cells/mm³ after three months of treatment. She also received the diagnosis of diffuse large B-cell lymphoma (DLCL), a non-Hodgkin's lymphoma which was initially treated with a combination of Cyclophosphamide, Adriamycin, Vincristine and Prednisone (CHOP). Due to severe neutropenia treatment was changed to Etoposide, Vincristine, Doxorubicin, Cyclophosphamide and Prednisone (EPOCH). Despite a complete course of treatment, lymphoma remission failed (breast and retroperitoneal mass tissue biopsy were positive for DLCL). In the week after the emergency admission, she was started on Ifosfamide, Carboplatin and Etoposide (ICE), a second-line chemotherapy protocol.

After an Oncology consultation, chemotherapy with ICE regimen for DLCL was continued. Cardiac biopsy was considered, which the patient refused. A new TTE after 30 days of chemotherapy revealed marked improvement, with a decrease in the pericardial effusion, as well as complete reduction in the myocardial septal thickening (Figure 2B). No further arrhythmias were documented in the subsequent eight months. No chronic antiarrhythmic medications were prescribed.

Keywords

Tachycardia, ventricular; heart neoplasms; Hodgkin disease; linfoma/quimioterapia.

Discussion

Metastatic involvement of the heart is discovered at the autopsy in 10 to 12% of patients with malignancies, most frequently of lung carcinoma. The majority of these cases involve the pericardium and epicardium, suggesting a regional lymphatic invasion. Myocardial involvement is less frequent and usually associated with melanoma or lymphoma, suggesting hematogenous invasion. Diffuse large B-cell lymphoma is a NHL with an incidence in HIV-

Mailing address: Nadine Clausell •

Rua Ramiro Barcelos 2350, Sala 2061 - 90035-003 - Porto Alegre, RS - Brazil
E-mail: clausell@portoweb.com.br

Manuscript received August 01, 2010; revised manuscript received October 11, 2010; accepted November 11, 2010.

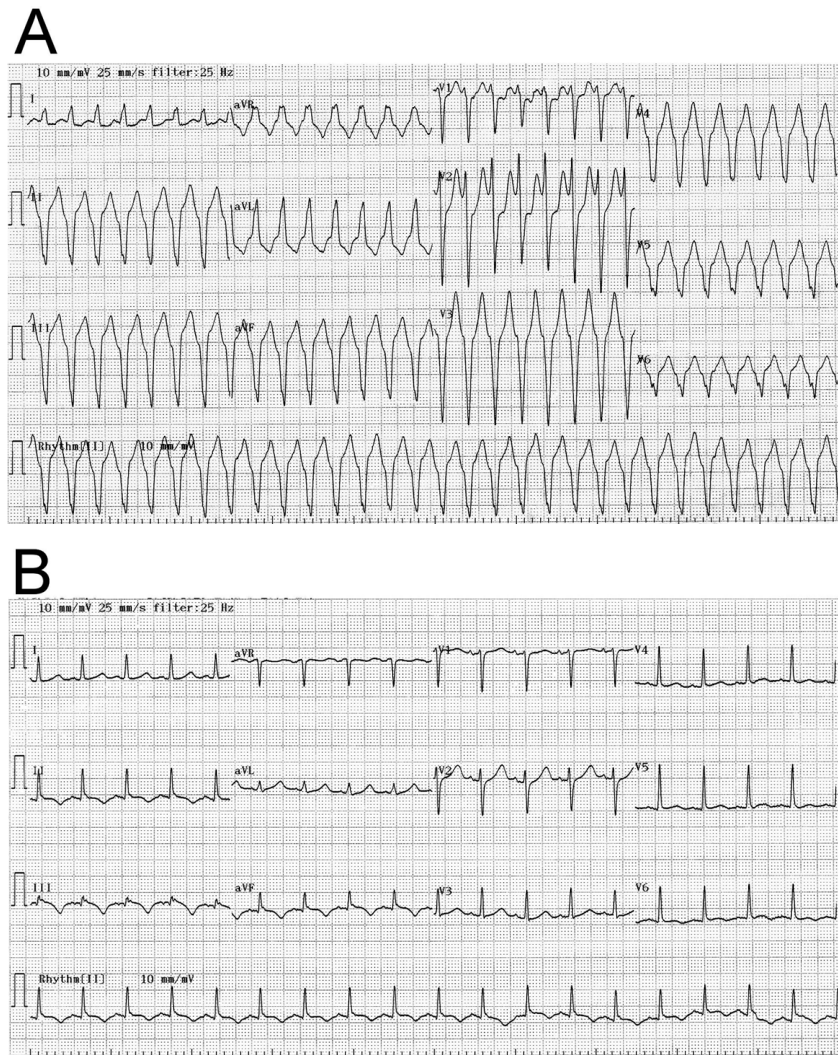


Figure 1 - The 12-lead electrocardiogram during wide-complex tachycardia (1A) and immediately after electrical cardioversion to sinus rhythm (1B).

infected individuals over 100 times the incidence in the general population¹.

In patients with NHL, clinical signs of cardiac involvement are nonspecific and frequently undetected before death. Chest pain, congestive heart failure and pericardial effusion were previously reported, the latter being the most common presentation². Although several cases of arrhythmias have been documented, most include atrioventricular block, probably related to secondary lesion to the conduction system³. Ventricular arrhythmias are rarely diagnosed in this population. For unknown reasons, most cases were reported in patients with primary cardiac lymphoma^{4,5}.

We describe a case of heart involvement in NHL presenting with monomorphic ventricular tachycardia, which is a rare manifestation. The diagnosis was performed based on images obtained from the transthoracic echocardiogram, which is an inexpensive and easily available method. It is important

to emphasize that in such cases cardiac involvement can be better determined with more sensitive imaging modalities, such as magnetic resonance or computed tomography. However, these techniques are expensive and not always available in cardiac centers.

The mechanism associated with ventricular tachycardia could be secondary to ventricular conduction delay caused by localized myocardial invasion of lymphoma cells, although triggered activity cannot be excluded. In this setting, the electrophysiological study can be a valuable tool in selected cases to understand the arrhythmia mechanisms and response to pharmacological treatment. However, no prospective studies testing the role of this modality are available in such population.

One could hypothesize that the recent chemotherapy treatment caused myocardial toxicity and triggered VT, since two cases of ventricular arrhythmias were previously

Case Report

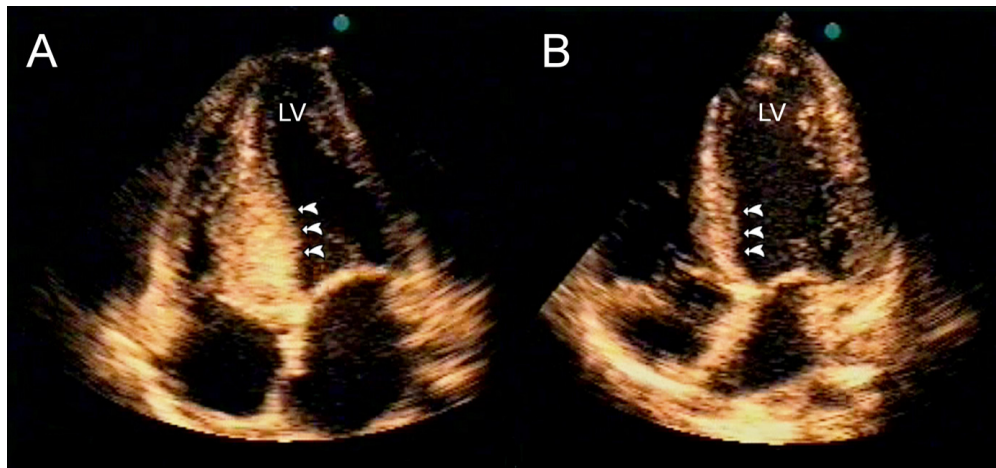


Figure 2 - Transthoracic echocardiogram in the apical four-chamber view showing thickening of the basal septum (arrows). Figure 2B shows the same projection in the echocardiogram performed after chemotherapy, which shows complete resolution of the myocardial thickening (arrows). LV - left ventricle.

documents with Ifosfamide use⁶. However, this hypothesis is less favored due to the improvement in the metastatic implants in the following days with the ICE protocol.

In conclusion, we report an unusual case of cardiac involvement of NHL presenting with VT. The occurrence of arrhythmias in this population should always alert for the possibility of metastatic involvement of the myocardium.

Potential Conflict of Interest

No potential conflict of interest relevant to this article was reported.

Sources of Funding

There were no external funding sources for this study.

Study Association

This article is part of the thesis of doctoral submitted by Diego Chemello, from Hospital de Clínicas de Porto Alegre - Universidade Federal do Rio Grande do Sul.

References

1. Goedert JJ, Cote TR, Virgo P, Scoppa SM, Kingma DW, Gail MH, et al. Spectrum of AIDS-associated malignant disorders. *Lancet*. 1998;351(9119):1833-9.
2. Thurber DL, Edwards JE, Achor RW. Secondary malignant tumors of the pericardium. *Circulation*. 1962;26:228-41.
3. Engelen MA, Juergens KU, Breithardt G, Eckardt L. Interatrial conduction delay and atrioventricular block due to primary cardiac lymphoma. *J Cardiovasc Electrophysiol*. 2005;16(8):926.
4. Tanaka Y, Yamabe H, Yamasaki H, Tsuda H, Nagayoshi Y, Kawano H, et al. A case of reversible ventricular tachycardia and complete atrioventricular block associated with primary cardiac B-cell lymphoma. *Pacing Clin Electrophysiol*. 2009;32(6):816-9.
5. Manojkumar R, Sharma A, Grover A. Secondary lymphoma of the heart presenting as recurrent syncope. *Indian Heart J*. 2001;53(2):221-3.
6. Quezado ZM, Wilson WH, Cunnion RE, Parker MM, Reda D, Bryant G, et al. High-dose ifosfamide is associated with severe, reversible cardiac dysfunction. *Ann Intern Med*. 1993;118(1):31-6.