



ORIGINAL ARTICLE

Inflammatory reaction in the intestinal wall of rats: can intraperitoneal urine cause damage?

Paulo R. Ferreira,¹ Sérgio L. Amantéa,² Manoel Trindade,³ Ubirajara Mota⁴

Abstract

Objective: To observe the intensity of the inflammatory reaction caused by urine on the intestinal wall of rats.

Methods: Experimental model, using 20 Wistar rats divided into two groups. All the animals were submitted to abdominal puncture at the right inferior quadrant, twice daily for five days. In Group I (control group) no substance was inoculated during the procedure, while in Group II (urine group), 3 ml of neonatal urine were inoculated. The animals were killed on the sixth day. A small-bowel specimen was fixed in paraffin and stained with hematoxylin-eosin. Microscopic analysis was performed by the same pathologist in all cases for determination of the degree of inflammatory reaction in the intestinal wall.

Results: All animals completed the experiment. In group I (control group) serositis was observed in six animals and enteritis in one. In group II (urine group) serositis was observed in nine animals and enteritis in four. The groups were similar in terms of the intensity of the inflammatory reaction observed ($p = 0.1$).

Conclusion: The intra-abdominal inoculation of neonatal urine did not produce significant inflammatory reactions in the intestinal wall of rats.

J Pediatr (Rio J). 2003;79(6):525-29: Gastrosquise, rats, intestine damage, urine.

-
1. MSc. Pediatric surgeon, Hospital da Criança Santo Antônio - Complexo Hospitalar Santa Casa, Porto Alegre, RS, Brazil.
 2. PhD. Associate professor, Department of Pediatrics, Fundação Faculdade Federal de Ciências Médicas de Porto Alegre (FFFCMPA). Chief of the Pediatric Emergency Room, Hospital da Criança Santo Antônio - Complexo Hospitalar Santa Casa, Porto Alegre, RS, Brazil.
 3. Associate professor, Department of Surgery, Universidade Federal do Rio Grande do Sul (UFRGS), Porto Alegre, RS, Brazil.
 4. Professor, Department of Surgery, Fundação Faculdade Federal de Ciências Médicas de Porto Alegre FFCMPA and Universidade Federal do Rio Grande do Sul UFRGS, Porto Alegre, RS, Brazil.

Manuscript received Jun 11 2003, accepted for publication Jul 25 2003.

Introduction

Gastroschisis is a defect of the anterior abdominal wall. The defect allows loops of bowel to protrude, the surface of which exhibits varying degrees of inflammatory process.

The global incidence of gastroschisis is estimated to be approximately 1:10,000 live births, with mortality rates varying from 7 to 80%. The primary appearance (inflammatory process) of the loops of bowel at birth appears to have a fundamental role in the prognosis of

gastroschisis patients. The first attempt to quantify the inflammatory reaction of the surface of the intestinal loops and correlate it with substances present in the amniotic fluid of patients suffering from gastroschisis was made by Sherman et al.¹ Because gastroschisis results in the bowel loops being in direct contact with the amniotic fluid, this exposure is held to be one of the principal factors responsible for the thickening and shortening of the intestine, which is common with this pathology.²⁻¹⁰ Urine, the major component of this embryonic fluid compartment, has been blamed for damage to the intestinal wall by many authors.^{5,9,11-13} These observations are based on the physiological principal that all of the fetus' urine is excreted into the amniotic cavity.

Based on the above, an experimental study was performed to observe the intensity of the inflammatory reaction, from a pathoanatomical point of view, caused by neonatal urine on the walls of the bowel loops of an animal model.

Methods

A controlled, experimental study, performed at the Experimental Research Center at the Federal Medical Sciences Faculty Foundation in Porto Alegre, Brazil. Twenty adult, male, albino Wistar rats, weighing between 250 - 350 grams, were selected from a group obtained at random from the breeder.

The urine of 20 normal newborn babies, born at the Irmandade Santa Casa de Misericórdia Maternity Unit in Porto Alegre, who were not being fed, was collected in a sterile recipient using aseptic techniques, during the first hour of life. The collecting system was changed every 20 minutes, with local hygiene and aqueous iodine, until the biological material was obtained. All of the urine underwent bacteriological analysis at the Institute's laboratory with no knowledge of the study objectives on the part of those responsible for the analysis. Only material proven free of bacterial growth was included in the study.

The rats were divided into two groups, depending upon the biological material to be injected into their peritoneal cavities:

Group I - control group (n = 10): animals were subjected to abdominal puncture of the lower-right-hand quadrant (LRQ), twice a day for five days. No substance was injected. This group was the control for the experiment.

Group II - urine group (n = 10): animals were subjected to abdominal puncture of the LRQ, twice a day, for five days. On each occasion 3 milliliters of neonatal urine was injected into the intraperitoneal cavity.

The project was evaluated and approved by the Research and Post-Graduation Group at the Federal Medical Sciences Faculty Foundation in Porto Alegre.

All of the mothers gave signed consent for collection of the material.

All of the animals were killed 24 hours after the last injection (sixth day of the experiment) by CO₂ inhalation and were then sequentially subjected to explorative laparotomy, via a xypho-pubic incision, for excision of the loops of intestine.

From each animal a specimen of small intestine was removed (approximately three centimeters from the pyloric region). This material was fixed in paraffin and was stained by the hematoxylin-eosin method. All the material was passed to the same pathologist (who did not know which group each animal belonged to) who performed the microscopic analysis. Each individual slide had the intensity of inflammatory reaction recorded on a standardized datasheet.

Following the example of the Sherman et al. study,¹ the inflammatory reaction of the bowel loops of each animal was analyzed in terms of the intensity of the following findings: serositis, enteritis, parietal necrosis and peeling. Once the presence of any of these inflammatory abnormalities was detected it was graded as mild, moderate and severe and transcribed to the standardized datasheet. The intensity of the findings, relating to the presence of an inflammatory reaction (serositis, enteritis, parietal necrosis and peeling) were scored from 1 to 3 (mild, moderate, severe). The sum of these resulted in a score for inflammatory reaction intensity that could vary from 1 to 12. The absence of any inflammatory reaction of any of the types evaluated resulted in a score of zero. The scores were used for the statistical analysis that was performed using the "U" test (Wilcoxon - Mann - Whitney test). The significance level adopted was 5 % ($\alpha = 0.05$).

Results

All of the animals completed the experiment. No differences were demonstrated between the general characteristics of the animals in the two groups (appearance of skin and weight). When the laparotomy was performed there were no lesions observed which could have been related to the daily puncturing. Intra-abdominal structures were intact. There were no observed macroscopic abnormalities of the bowel loops of any of the animals in either group (Figure 1).

When microscopic analysis was performed, in group I (control group) mild serositis was observed in six cases and in two of these the abnormality was associated with moderate enteritis. None of the animals exhibited parietal necrosis or peeling. The score for this group had an amplitude of 0 to 3 and a median of 1. The total score for the whole group was 8.

In group II, nine animals presented serositis (one mild, six moderate and two severe). Enteritis was observed in

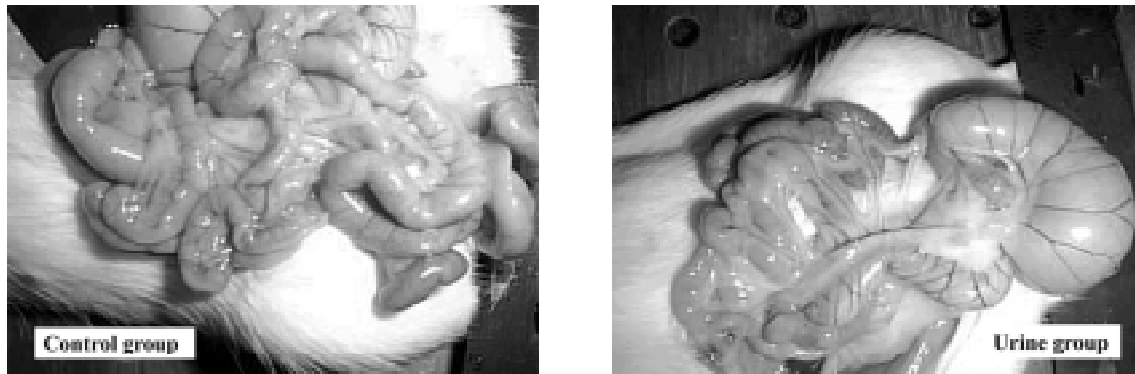

Figure 1 - Macroscopic aspect of the bowel loops after laparotomy

four (two mild and two moderate). Parietal necrosis or peeling were not observed in any animal. The score for group II had an amplitude of 0 to 5, with a median of 2.5. The total number of points for the group was 27. Figure 2 details the frequencies of each score for the two groups.

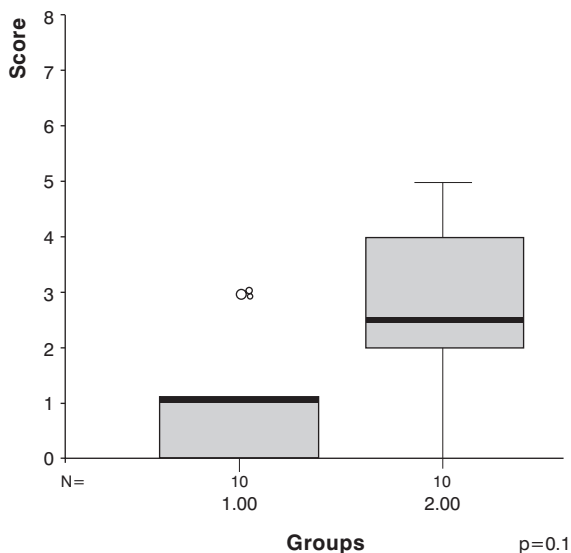


Figure 2 - Frequencies of each score for the two groups

Discussion

In our study we did not observe significant differences in the inflammatory reactions on the walls of loops of intestine of animals subjected to the injection of urine into the peritoneal cavity. These findings are in agreement with some hypotheses raised by other authors. Akgur et al.¹⁴ and Olguner et al.¹⁵ have defended through their experimentation the possibility that residues from the digestive tract may be associated with the genesis of the problem. Although the etiology of gastroschisis and factors relative to its prognosis remain a controversial subject, one point in common is that some characteristic of the amniotic fluid may be one of the most important factors in the genesis of the inflammatory process. Amniotic fluid has been blamed for many of the abnormalities.^{2-4,8,9,11-13,16} secondary to direct action on the eviscerated loops for a large part of the pregnancy.^{5-10,17-20} However, there are doubts about which component substances or substances might be responsible for the intestinal shortening, thickening and reduced peristalsis found in these patients.^{1-4,11-14,21} Urine is the principal component of amniotic fluid,^{5,9,11-13,17} and, because of this, it has often been blamed for the intestinal damage, since the fetus physiologically urinates into the amniotic cavity.^{5,9,11-13,17,22,23} During the early 80s, in varying experiments, a number of different authors correlated urine with damage to the walls of herniated viscera. Innumerable studies were performed with hens' embryos. This species has two embryonic cavities. An allantoic cavity, responsible for storage of the products of urinary and intestinal metabolism and an amniotic cavity in which are the bowel loops. Under normal conditions the

two cavities are not in contact. At the moment that, experimentally, the allantoic cavity is ruptured (amnio-allantoic cavity) its contents come into contact with the bowel loops causing varying degrees of inflammatory reaction. However, in this type of experiment it is not possible to categorically determine whether only urine was responsible for the intestinal damage.^{11,12}

This has been the great difficulty of all of the experimental models tested to date; it is necessary to know which substance present in amniotic fluid could be responsible for the damage. In addition to the models referred to above, in which hens' eggs were used, other animal models have been investigated with bowel loops being subjected to exposure to human urine.¹⁴ While it may appear contradictory to use neonatal human urine (early collection, uncolonized) for these animal models, the objective views the issue through a different lens. The capacity of urine to provoke an inflammatory reaction in the walls of bowel loops in an animal model. The exposure of rat intestine to rat urine is not an objective and of no practical interest. Transposing this analysis to our objective, we attempted to observe human urine (an environment that is to be found in our amniotic cavities), provoke damage to bowel loop walls in this animal model. The response observed from the walls of rat intestine may differ from that found in humans. However, this is an intrinsic limitation of experimental studies. The possibility of different behavior with the human race must be taken into account, but it is also important to reinforce the fact that, in the current research and in other studies performed with different experimental models, the main factor under study has centered on human urine (its inflammatory action on bowel loops) and not on the experimental animal used.

It is known that the presence of an intense intestinal wall inflammatory process is not characteristic of cases of urinary ascites.¹⁷ However, other substances that make up human amniotic fluid, including meconium,^{2,4,14-16,24-26} may be responsible for the event. Innumerable experiments have demonstrated that intrauterine defecation can be considered physiological,^{2,16,24,25,27-29} and as such the differences that we did not find in our study could be related to a secondary role played by urine in the presence of an inflammatory effect by one of these other components which were not tested in the experiment.

Also worthy of consideration is the possibility that a significant difference was not encountered due to limitations of sample size. Once the number of cases was increased, a hitherto unapparent difference may be detected (b error). We also judge it important to point out that the scores obtained from the inflammatory scale may also fail to be a trustworthy instrument for obtaining clinical judgments. Even the animals used as controls exhibited some abnormalities during anatomical pathology. Certain inferences may be made to justify this

finding. The mechanism for killing the animals or even the repeated punctures of the amniotic cavity may lead to minor inflammatory abnormalities of the intestinal wall. The total scores obtained for each group (Group I: 8 and Group II: 27), compared to the maximum possible score (maximum score of 120) clearly illustrate the low significance of the manifestations provoked.

Congenital abdominal wall defects are a challenge to neonatal intensive care, with gastroschisis being associated with a mortality of around 10%. Its etiology is unknown, although it is possible that it is part of a wide spectrum of fetal disorders that includes vascular factors, factors related to the position of the defect and the capacity of the fetus to heal.²⁶ The intensity of the inflammatory reaction present in the intestinal walls of these patients is a defining factor in their prognosis from which springs the importance of establishing its etiology and identifying factors which may be associated with worse progress. In our study the injection of neonatal urine was not capable of producing significant inflammatory reactions on the intestinal walls of rats when compared with animals in a control group submitted to just the paracentesis procedure.

References

1. Sherman NJ, Asch MJ, Isaacs H Jr, Rosenkrantz JG. Experimental gastroschisis in the fetal rabbit. *J Pediatr Surg.* 1973;8:165-9.
2. Aktug T, Erdag G, Kargi A. Amnio-allantoic fluid exchange for the prevention of intestinal damage in gastroschisis: an experimental study on chick embryos. *J Pediatric Surg.* 1995;30:384-7.
3. Aktug T, Uçan B, Olguner M. Amnio-allantoic fluid exchange for prevention of intestinal damage in gastroschisis II: effects of exchange performed by using two different solutions. *Eur J Pediatr Surg.* 1998;8:308-11.
4. Aktug T, Uçan B, Olguner M. Amnio-allantoic fluid exchange for prevention of intestinal damage in gastroschisis III: Determination of waste products removed by exchange. *Eur J Pediatr Surg.* 1998;8:326-8.
5. Hakgüder G, Ates O, Olguner M, Riza Sisman A, Akgur FM. Is induction of fetal diuresis with intraamniotic furosemide effective for the removal of intestinal waste products from amniotic fluid? *Eur J Pediatr Surg.* 2002;12:293-8.
6. Saxena AK, Hülskamp G, Schleef J, Schaarschmidt K, Harms E, Willital GH. Gastroschisis: a 15-year, single-center experience. *Pediatr Surg Int.* 2002;18:420-4.
7. Sydorak RM, Nijagal A, Sbragia L, Hirose S, Tsao K, Phibbs RH, et al. Gastroschisis: small hole, big cost. *J Pediatr Surg.* 2002;37:1669-72.
8. Hunter A, Soothill P. Gastroschisis – an overview. *Prenat Diagn.* 2002;22:869-73.
9. Hakgüder G, Ates O, Olguner M, Api A, Ozdogan O, Degirmenci B, et al. Induction of fetal diuresis with intraamniotic furosemide increases the clearance of intraamniotic substances: an alternative therapy aimed at reducing intraamniotic meconium concentration. *J Pediatr Surg.* 2002;37:1337-42.
10. J Baerg, G Kaban, J Tonita, P Pahwa, D Reid. Gastroschisis: a sixteen-year review. *J Pediatr Surg.* 2003;38:771-4.

11. Klück P, Tibboel D, van der Kamp AWM, Molenaar JC. The effect of fetal urine on the development of bowel in gastroschisis. *J Pediatr Surg.* 1983;18:47-50.
12. Tibboel D, Keers CV, Klück P, Gaillard JLJ, Koppenberg J, Molenaar JC. The natural history of gastroschisis during fetal life: development of the fibrous coating on bowel loops. *Teratology.* 1986;33:267-72.
13. Lopez de Torre B, Aldazabal P, Uriarte S, Sanvicente MT, Ruiz I, Tovar JA. Produccion experimental de laparosquisis en el embrion de pollo. *Cir Pediatr.* 1991;4:108-11.
14. Akgur FM, Özdemir T, Olguner M, Aktug T, Özer E. An experimental study investigating the effects of intraperitoneal human neonatal urine and meconium on rat intestines. *Res Exp Med.* 1998;198:207-13.
15. Olguner M, Akgür FM, Api A, Özer E, Aktug T. The effects of intraamniotic human urine and meconium of the intestines of chick embryo with gastroschisis. *J Pediatr Surg.* 2000;35:458-61.
16. Abramovich DR, Gray ES. Physiologic fetal defecation in mid pregnancy. *Obstet Gynecol.* 1982;60:294-6.
17. King LR. Posterior urethra. In: Kelalis PP, King LR, Belman AB, editors. *Clinical Pediatric Urology.* Philadelphia, PA: W. B. Saunders Co; 1985. p. 527-558.
18. Cooney DR. Defects of the abdominal wall. In: O'Neil JA, Rowe MI, Grosfeld JL, Fonkalsrud EW, Coran AG. *Pediatric Surgery.* 5th ed. Mosby-Year Book, Inc; 1998. p. 1045-1069.
19. Bax NMA. Exomphalos and gastrochisis. In: Freeman NV, Burge MD, Griffiths DM, Malone PSJ, editors. *Surgery of the newborn.* Churchill Livingstone; 1994. p. 301-320.
20. Maksoud JG. Defeitos da região umbilical e paraumbilical. In: Maksoud JG, editor. *Cirurgia Pediátrica.* Rio de Janeiro: Livraria e Editora Revinter; 1998. p. 674-682.
21. Gaines BA, Holcomb GW III, Neblett WW. Gastroschisis and Omphalocele. In: Ashcraft KW, Murphy JP, Sharp RJ, Sigalet DL, Snyder CL. *Pediatric Surgery.* 3rd ed. Philadelphia: W. B. Saunders Co; 2000. p. 639-649.
22. Lotgering FK, Wallenburg HC. Mechanisms of production and clearance of amniotic fluid. *Semin Perinatol.* 1986;10:94-102.
23. Martin RW, Mc Colgin SG. Evaluation of fetal and neonatal acid-base status. *Obstet Gynecol Clin North Am.* 1990;17:223-33.
24. Ciftci AO, Tanyel FC, Ercan MT, Karnak I, Büyükpamukçu N, Hiçsönmez A. In utero defecation by the normal fetus: a radionuclide study in the rabbit. *J Pediatr Surg.* 1996;31:1409-12.
25. Kizilkan F, Karnak I, Tanyel FC, Büyüpamukçu N, Hiçsönmez A. In utero defecation of the nondistressed fetus: a roentgen study in the goat. *J Pediatr Surg.* 1994;29:1487-90.
26. Aktug T, Hosgor M, Akgur FM, Olguner M, Kargi A, Tibboel D. End-results of experimental gastroschisis created by abdominal wall versus umbilical cord defect. *Pediatr Surg Int.* 1997;12:583-6.
27. Mulivor RA, Mennuti MT, Harris H. Origin of the alkaline phosphatases in amniotic fluid. *Am J Obstet Gynecol.* 1979;135:77-80.
28. Potier M, Melacon SB, Dallaire L. Developmental patterns of disaccharidases in human amniotic fluid. *Am J Obstet Gynecol.* 1978;131:73-9.
29. Morin PR, Potier M, Dallaire L. Prenatal detection of intestinal obstruction: deficient amniotic fluid disaccharidases in affected fetuses. *Clin Gent.* 1980;18:217-22.

Corresponding author:

Paulo Roberto Ferreira

Rua Américo Vespúcio, 81/802

CEP 90550-030 – Porto Alegre, RS, Brazil

E-mail: pauloferreira@portoweb.com.br