



---

**REVIEW ARTICLE**

---

## *Surgical treatment of parapneumonic pleural effusion and its complications*

José C. Fraga,<sup>1</sup> Peter Kim<sup>2</sup>

### **Abstract**

**Objective:** surgical treatment of parapneumonic pleural effusion in children is controversial. The type of intervention is based mainly on personal experience and on the small number of reported cases. This article aims at presenting a literature review and the authors' experience in the surgical management of parapneumonic pleural effusion in children.

**Sources:** data were searched in the Medline and Lilacs databases.

**Summary of the findings:** complicated parapneumonic effusion should be surgically drained if thoracentesis reveals the presence of pus, positive Gram stain or culture, or pH less than 7.0 or glucose less than 40 mg/dl. The surgical drainage depends on the stage of parapneumonic pleural effusion: at the acute stage closed thoracostomy drainage is enough; at the fibrinopurulent stage thoracoscopy is indicated; at organizational stage thoracotomy can be performed in children with stable anesthetic conditions, and open thoracostomy drainage should be used in patients in a poor state of health. Echography is very important to evaluate the staging of parapneumonic effusion.

**Conclusions:** surgical treatment of complicated parapneumonic effusion should be done as early as possible, and the kind of procedure depends on the stage of pleural effusion. In children with complicated parapneumonic effusion echography is very important to evaluate the staging of parapneumonic effusion.

*J Pediatr (Rio J) 2002;78(Supl. 2):S161-S70:* pleural effusion, surgical drainage, surgery.

### **Introduction**

Pleural effusion often occurs in children with pneumonia, with an incidence between 21 and 91%.<sup>1</sup> The macroscopic, biochemical and bacteriological analyses of the parapneumonic pleural fluid assesses the necessity for surgical drainage.

The surgical treatment of complicated parapneumonic effusion in children is controversial and has been based on personal experience and on the limited number of cases reported in the literature.<sup>2</sup> Surgical decisions are influenced by a series of variables, such as age and clinical status of the patient, response to antibiotic therapy, microorganisms found in culture, and staging and duration of empyema.<sup>2</sup> Possible treatment includes antibiotics or antibiotic therapy combined with thoracentesis,<sup>3</sup> closed thoracostomy drainage,<sup>4</sup> fibrinolytic agents,<sup>5</sup> thoracoscopy,<sup>6-8</sup> minithoracotomy,<sup>9,10</sup> open thoracostomy drainage<sup>3</sup> or usual thoracotomy.<sup>11,12</sup>

---

1. Associate professor of Pediatric Surgery, Graduate Course, School of Medicine, Universidade Federal do Rio Grande do Sul (UFRGS); pediatric surgeon at Hospital de Clínicas (HCPA) and Hospital Moinhos de Vento (HMV), Porto Alegre, Brazil.

2. Associate Professor, School of Medicine, University of Toronto.

Although there is no consensus on the management of complicated parapneumonic effusion, it must be carried out in an organized and systematic manner, in order to determine the indication and type of surgical drainage, which should be performed as soon as possible. This allows a more rational approach, with reduced treatment costs and the possibility for future analysis and comparison of results.<sup>13</sup>

### Definition

Pleural effusion associated with pneumonia is called parapneumonic effusion. This effusion is classified as *complicated* and *uncomplicated*.<sup>14</sup>

*Uncomplicated* parapneumonic effusion is a reaction to underlying pulmonary infection and, in general, is reabsorbed with antibiotic therapy and with the healing of pulmonary infection. This type of effusion is not purulent, and yields negative results on Gram stain and culture, with pH higher than 7.2, glucose greater than 40 mg/dl and lactate dehydrogenase (LDH) lower than 1,000 IU/l.<sup>14</sup>

*Complicated* parapneumonic effusion is purulent or positive on either Gram stain or culture, with pH lower than 7.0, glucose lower than 40 mg/dl and LDH greater than 1,000 IU/l.<sup>14</sup> Empyema, defined as the accumulation of intrapleural pus, is characteristic of complicated parapneumonic effusion.

Regardless of the presence or absence of pus or bacteria in the fluid, complicated effusion should be treated as empyema, since there is a great possibility of loculation which, if improperly treated, produces frank pus. Complicated parapneumonic effusion causes remarkable increase in morbidity and mortality,<sup>8</sup> and its presence always requires surgical drainage.<sup>14</sup>

### Pathophysiology

As initially defined by the American Thoracic Society, in 1962, pleural effusion develops in three different stages.<sup>15</sup> If inappropriately treated, it can progress and reach the highest stage.<sup>14</sup> The first stage is known as *acute* or *exudative* (as short as 48 hours) and is characterized by rapid effusion of sterile fluid into the pleural space. The origin of this fluid is not perfectly known yet, but it may probably originate from the interstitial space of the lung.<sup>14</sup> At this stage, the fluid has a small amount of leukocytes and LDH, as well as normal levels of pH and glucose,<sup>16</sup> and can be easily drained, with quick re-expansion of the lung.

If antibiotic therapy is inadequate, the bacteria of the contiguous pneumonic process invade the pleural space, triggering the second stage, called *fibrinopurulent* (2 to 10 days after the process has begun). This stage is characterized by a large accumulation of pleural fluid, with many

polymorphonuclear leukocytes, bacteria, and cellular remains. Fibrin is formed and deposited on the visceral and parietal pleurae, with a tendency towards the formation of partitions with loculated effusion. Loculation prevents the dissemination of empyema, but hinders the removal of the fluid from the pleural cavity. As this stage advances, the pleural fluid tends to show low levels of pH and glucose and high LDH values.<sup>14</sup> Re-expansion of the lung occurs when the partitions rupture and fibrin is removed.

The last stage, known as *organizational* (2 to 4 weeks after primary infection), is characterized by the presence of fibroblasts on the surfaces of the visceral and parietal pleurae, which cover the lung with a thick and inelastic membrane and reduce its expansibility. Even after all the fluid and fibrin are removed from the pleural cavity, the lung is not totally expanded. At this stage, the pleural fluid is thick and if the patient is not properly treated, the fluid may spontaneously drain to the lung, producing a bronchopleural fistula.<sup>14</sup>

### Diagnosis

The clinical presentation of parapneumonic effusion is indistinguishable from underlying pneumonia, as both are characterized by fever, tachycardia, tachypnea, dyspnea and productive cough. Older children may complain of pleuritic chest pain. The clinical examination reveals reduction of vesicular murmur and dullness to percussion.

The diagnosis is often established by chest x-ray in anteroposterior and lateral positions. The pleural fluid may fill up the hemithorax, with displacement of the mediastinum and trachea to the contralateral side. Echography is the best exam for the assessment of pleural fluid and for the detection and quantification of fibrin in it, thus determining the stage of the effusion.<sup>17</sup> Computed tomography is used to assess complications of parapneumonic effusion, such as extension of pneumonia, pulmonary necrosis, pneumatocele, lung abscess, bronchopleural fistula, and to rule out other diseases such as subdiaphragmatic abscesses and effusions caused by tumors of the lung, chest wall, mediastinum or liver.<sup>17</sup>

The parapneumonic pleural fluid can only be identified by diagnostic thoracentesis. This procedure can also be used to isolate and identify the causative agent of the infection. Thoracentesis should ideally be performed before antibiotic therapy, especially if lateral decubitus films show pleural effusion greater than 1 cm between the lung and the chest wall.<sup>14</sup> The fluid should be assessed as to its aspect and color and then referred for bacteriological and biochemical examination. Some tests used for the quick detection of antigens in the pleural fluid, as is the case of latex agglutination test, have been used to identify capsule pneumococcal antigens and Haemophilus influenzae type B antigens.<sup>18</sup> This allows the early detection of the causative agent of the pneumonic process.

## Treatment

Recent studies have underscored the importance of early and aggressive treatment of complicated parapneumonic effusion. The treatment is controversial and should also include adequate parenteral antibiotics. It is crucial that the effusion be treated as soon as possible and according to the developmental stage of the disease.<sup>8,19</sup>

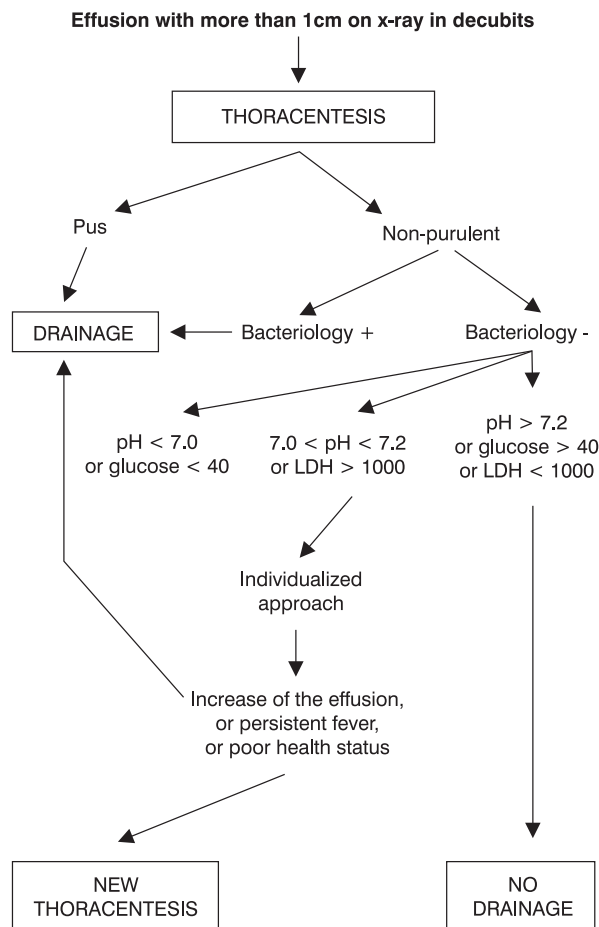
Surgical drainage of the empyema is based on the examination of the pleural fluid (Figure 1). Drainage is recommended when the fluid is purulent or yields positive results on Gram stain or culture and biochemical analysis, with pH lower than 7.0, or glucose level lower than 40 mg/dl. Children who have parapneumonic pleural fluid with pH between 7.0 and 7.2, or LDH greater than 1,000 IU/ml, should be assessed individually.<sup>14</sup> If effusion is massive and the patient is febrile and in a poor health state, drainage should be performed; in case of a small pleural effusion and a stable health status, a new thoracentesis is advisable after a 12 to 24-hour interval (Figure 1).

The presence of septated pleural effusion is not alone an indication for surgical drainage.<sup>14,20,21</sup> It is important to analyze the pleural fluid, as loculations may only indicate an intense inflammatory response in the pleural space, without necessary complication of the fluid by the presence of bacteria or low levels of pH or glucose. However, most children with loculated pleural effusion show altered pleural fluid, which requires drainage.<sup>14,21</sup>

The treatment of complicated parapneumonic effusion has been based upon the natural history of the effusion and the type of surgical drainage depends on the stage of the effusion (Figure 2).

At the acute stage, the placement of a large-bore chest tube in the lower part of the effusion is often enough for the complete removal of the pleural fluid, allowing for re-expansion of the lung.<sup>14</sup>

At the fibrinopurulent stage of complicated effusions, fibrin should be removed and pleural partitions should be ruptured in order to allow for the total re-expansion of the



**Figure 1 - Management of the empyema<sup>13</sup>**

lung (Figure 2). The fibrinopurulent material is not totally removed by chest drainage (even when large-bore tubes are used), due to the thickening of the fluid and to the partitions that make the effusion loculated. At this stage, thoracoscopy is necessary (Figure 2).

In effusions at the organizational stage, at which the lung is not able to expand, even after the pleural fluid is removed, the definitive treatment can include thoracotomy and clearing of the whole pleural material, when the patient has clinical conditions to undergo a large surgery, or pleurostomy, for debilitated patients, to whom anesthesia poses a major risk. These procedures have been used less and less frequently on children, since in most cases surgical intervention is performed at the acute and fibrinopurulent stages of the effusion.<sup>20</sup>

**Types of pleural drainage**

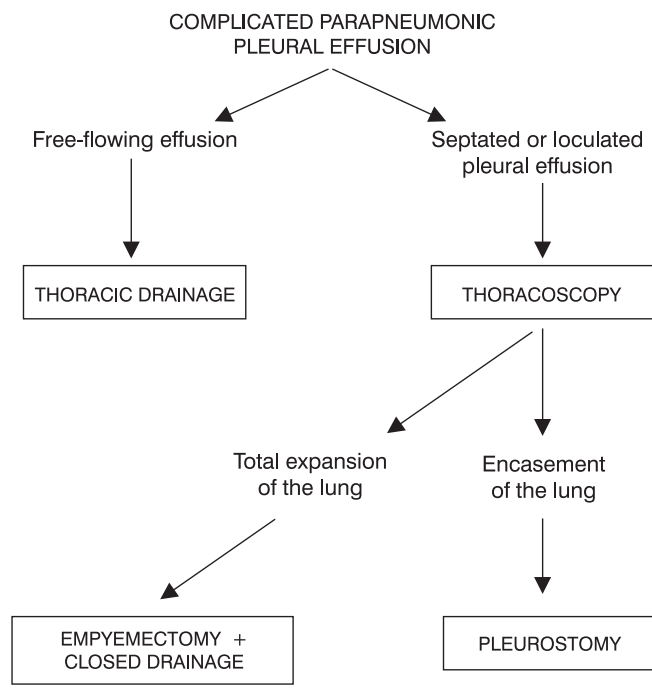
The removal of pleural fluid is still a fundamental procedure for the treatment of complicated parapneumonic effusion since it allows for lung re-expansion and contact between the pleurae, with consequent obliteration of the pleural space and healing of the infection.

The pleural fluid can be removed by closed thoracostomy drainage, thoracotomy or thoracoscopy. The ideal moment for carrying out each of them has been previously discussed.

*Closed thoracostomy drainage*

Silicone chest tubes with several side openings are preferred for the drainage of parapneumonic effusion. These silicone tubes are sturdy but malleable, inexpensive, and cause minimal irritation to the skin or the pleura. Large-bore tubes should be used, since they are less prone to obstruction.

The drainage by closed chest tubes is performed in the lower region of the fluid collection, at the posterior axillary line. In effusions without partitions, the lower regions usually correspond to the fifth or sixth intercostal spaces. Ideally, the lower region of the effusion should be assessed by thoracentesis, immediately before the tube is inserted. The placement of a tube below the sixth or seventh intercostal space should be avoided due to the risk of damage to the diaphragm or abdominal viscera. The tube should be preferably placed with an underwater seal, without aspiration.



**Figure 2 -** Types of empyema drainage

For the placement of chest tubes, the patient should be sedated, if clinically possible, with midazolam or chloral hydrate and immobilized ("mummification" technique). General anesthesia should be used on children who can tolerate it. The patient is placed in a supine position with his/her arm and forearm, on the same side, raised, so that the intercostal spaces can be expanded. A small cushion is placed under the hemithorax to be drained. The hemithorax is submitted to antisepsis with aqueous iodophor and the skin, subcutaneous tissue and parietal pleura where the tube is to be inserted are anesthetized with lidocaine. The puncture of lower intercostal spaces confirms the correct site for the drainage. After the site for the drainage is determined, an incision the same size of the tube to be inserted should be made on the skin. Large incisions may cause air escape, provoking subcutaneous emphysema. After that, the subcutaneous tissue and the intercostal muscles are pulled apart by hemostatic clamps until the pleural cavity is penetrated. It is important that dissection be made close to the upper border of the lower rib of the intercostal space so as to avoid damage to intercostal vessels. The musculature should not be sectioned due to the risk of bleeding. The tube is then inserted into the pleural space, coupled onto the clamp previously used to open the drainage hole, hooked up to the drainage system, and sutured on the skin with nonabsorbable purse-string stitches. The fixing point is threaded in a U-shape and fastened in such a way that it can be used to close the tube opening at the time of tube removal. Before fixing the tube, make sure no opening of the tube protrudes from the chest cavity. The site is then draped with gauze and taped with Micropore.

A chest x-ray (anteroposterior and lateral positions) should be done after drainage, in order to assess the position of the tube and lung re-expansion. The nature and volume of the drainage should be daily monitored until the tube is removed.

The chest tube should be removed when the amount of drained fluid is minimal and when there is no air escape. The clamping of the tube before removal is quite arguable and is not carried out by us on a routine basis. While the tube is being removed, its opening for insertion into the skin should be quickly closed in order to prevent air from entering the pleural cavity. Chest x-rays should be done every 6 to 12 hours after tube removal, in order to confirm the total expansion of the lung.

#### *Thoracotomy*

The pleural drainage of the parapneumonic fluid can be carried out by thoracotomy, which is useful for the drainage of the pleural fluid, breakdown of adhesions and removal of fibrin and, when necessary, resection of the necrotic lung tissue, or bronchopleural fistula.<sup>22,23</sup> This surgical procedure was erroneously called decortication or early decortication in the past. This term should not be used, since decortication, with removal of the pleura, is not actually performed;

instead, an empyemectomy (clearing of the intrapleural material) is carried out (Figure 2).

Thoracotomy was recommended for effusions at the fibrinopurulent or organizational stages,<sup>23</sup> which could be performed by classical posterolateral incision,<sup>23</sup> or by minithoracotomy.<sup>9,10</sup> Due to complications such as deformity of the chest wall, significant blood loss and higher probability of resection of the pulmonary parenchyma and of the bronchopleural fistula, or postoperative pneumonia, the procedure is currently performed only in cases of complicated effusion at the organizational stage. Differently from adult patients, thickening of the pleura observed in complicated parapneumonic effusion has a benign course in children, with spontaneous resolution and with no need for surgical intervention.<sup>24</sup>

With the frequent use of pediatric videosurgery, thoracoscopy became an ideal procedure for children with complicated effusion at the fibrinopurulent stage, with numerous advantages over thoracotomy: it causes less postoperative pain and earlier return to activity; reduces anxiety of parents about postoperative care and shortens the length of hospital stay; minimizes chances of resection of the pulmonary parenchyma and reduces the need for blood transfusion; avoids thoracotomy and its sequelae, with optimal esthetic results; encourages pediatricians to refer patients with complicated effusion for surgical assessment, at an earlier time.<sup>25</sup>

Pleurostomy has been used on children with complicated effusion at the organizational stage, with a poor health state, for whom anesthesia or a large surgery is of high risk. This procedure should only be used after confirming that the lung is adhered and encased, with no risk of collapse after the pleural cavity is opened. By the incision in the lowermost part of the fluid cavity, a small part of the rib is resected, but the periosteum is maintained. After that, the skin and the subcutaneous tissue are loosened from the border of the chest opening in such a way that the skin can be sutured to the parietal pleura. This opening allows the drainage of secretions, washing of the pleural cavity and gradual pulmonary re-expansion. Another advantage of this method is the possibility of earlier discharge from hospital. Nevertheless, it is important that the pleural opening be located on the lowermost part of the fluid cavity, in order to avoid the accumulation of intrathoracic secretion below the pleurostomy level.

#### *Thoracoscopy*

Thoracoscopy has been successfully used in adults with empyema. Kehr and Rodgers<sup>6</sup> were the first to describe the success of thoracoscopy for the treatment of empyema in children. They affirmed that thoracoscopy is a minimally invasive procedure, which allows washing fibrin out of the pleural cavity and placing a well-located chest tube under direct visualization. When thoracoscopy is performed at an early stage, it reduces the need for other surgical procedures.

Thoracoscopy may be carried out either with or without video equipment. Although video-assisted thoracoscopy allows a better visualization of the pleural cavity, pleuroscopy with a small mediastinoscope allows properly clearing and aspiration of the pleural material, and also permits the total expansion of the lung.<sup>26</sup> The comparison between video-assisted thoracoscopy and pleuroscopy with a mediastinoscope in children did not show statistically significant difference as to the length of the procedure, length of postoperative pleural drainage and length of hospital stay.<sup>20</sup>

Thoracoscopy is especially recommended for parapneumonic effusion at the fibrinopurulent stage (Figure 2), since it allows breaking down the adhesions and removing fibrin and the infected material, with the release of all pulmonary surfaces, including the diaphragmatic ones. This way, the lung may have total re-expansion and the infection can be resolved.<sup>6</sup> Thoracoscopy has also been indicated for children with empyema, in which closed thoracostomy drainage was not sufficient to remove all the fluid from the pleura.<sup>27</sup> Klena *et al.*<sup>19</sup> suggest that the procedure be early indicated in cases of septated effusions, after chest drainage, in children with persistent effusion. Merry *et al.*,<sup>28</sup> in a review of 23 children with empyema submitted to thoracoscopy, reported that thoracoscopy was indicated as initial drainage procedure in 19 of them. Thoracoscopy was indicated due to the presence of loculated effusion, diagnosed by insufficient drainage of the whole fluid at thoracentesis or at chest x-ray, echography, or computed tomography.<sup>28</sup> Subramaniam *et al.*<sup>25</sup> have recently compared thoracoscopy with thoracotomy in children with empyema and observed that thoracoscopy significantly reduces surgical time, the necessity for pulmonary resection, intraoperative blood loss, necessity for analgesia, length of chest drainage and the length of hospital stay.

Even though there is no randomized controlled study of children that compares this method with other procedures, we prospectively indicate thoracoscopy as an initial drainage procedure in loculated or septated parapneumonic effusions (Figure 2).

Thoracoscopy is performed under general anesthesia on an intubated patient placed in lateral decubitus. At the beginning, we carried out selective intubation of the contralateral lung; however, the last patients were submitted to thoracoscopy without the need for selective intubation. For the procedure, we used two 5-mm trocars: the first one was inserted into a small incision below the nipple. In children with previous chest tube placement, the procedure is initially carried out by the tube opening. We recommend penetrating the pleural space initially with a hemostatic clamp and then proceeding to the trocar insertion. We do not think CO<sub>2</sub> inflation through the trocar is necessary, as recommended by some authors so as to favor pulmonary collapse.<sup>25,29</sup> After inspection of the cavity with an optical device measuring 4 or 5 mm, the second trocar is inserted into the nethermost region of the pleural effusion. This

opening is later used for the placement of the postoperative drainage tube. After insertion of the trocars, and under direct visualization, an aspirator and dissection clamps are introduced for removal of the fluid and release of all adhesions and partitions, especially the mediastinal and diaphragmatic ones, thus allowing for the total re-expansion of the lung. The procedure is only finished when the lung is totally clear and able to expand freely, with positive ventilatory pressure. The chest tube is then placed under direct visualization and the small incision on the chest is closed with absorbable stitches.

Thoracoscopy on children with complicated parapneumonic effusion has been gathering considerable momentum. Although most studies are retrospective, with a small sample of children, the procedure has proved effective, with minimal complications (Table 1).

A recent review of 29 children aged between eight months and 11 years (mean of three years and three months), submitted to thoracoscopy for treatment of complicated parapneumonic effusion at Hospital de Clínicas de Porto Alegre, has shown that the procedure was effective and well tolerated.<sup>36</sup> After thoracentesis, the children received broad-spectrum antibiotics intravenously and were submitted to some type of drainage. A pleural tube was inserted in 23 patients, and thoracoscopy was performed on six patients. In the latter, thoracoscopy was the initial procedure due to the presence of pleural effusion with partitions at echography. In patients with closed thoracostomy drainage, thoracoscopy was performed due to the presence of fever and residual pleural fluid at echography (with or without partitions), with or without deterioration of the general health status, during or after the removal of the chest tube.

Echographic examination was carried out before thoracoscopy on all patients for detection and location of pleural fluid and presence of fibrin and loculations of the pleural effusion. The surgical time of thoracoscopy averaged 97 minutes (30 to 180 min). The chest x-ray in the immediately postoperative period showed adequate pulmonary expansion, with residual thickening of the pleura with no evidence of effusion. Three children had subcutaneous emphysema at the site of surgical incision. Infection of the surgical incision was not observed. Chest drainage after thoracoscopy averaged 7.4 days (2 to 27). Five children required new thoracoscopy during the follow-up period. These children had fever and pleural effusion after the removal of the chest tube and were submitted to a new procedure for the removal of the fluid and fibrin. Another three children, treated at the beginning of our series, required open thoracostomy drainage. Two of them also revealed pleural effusion and fever after removal of the tube; however, due to encasement of the lung, a pleurostomy was carried out. One child had effusion through the chest tube for over two weeks; in this case, the tube was cut and opened externally. The length of hospital stay after thoracoscopy averaged 15.1 days (5 to 26 days). All patients stayed asymptomatic after hospital discharge. The chest x-

**Table 1** - Thoracoscopy in the treatment of complicated parapneumonic effusion in children and adolescents

Author/Year	Number of children	Stage/Empyema	Efficacy *	Complications
Kern/Rodgers <sup>6</sup> / 1993	9	II and III	100%	Absent
Stovroff <sup>8</sup> / 1995	10	II and III	90%	Absent
Davidoff <sup>30</sup> / 1996	9	II	78%	Not mentioned
Campos <sup>31**</sup> / 1997	38	II and III	82%	Not mentioned
Klena <sup>19</sup> / 1998	21	II	71%	Not mentioned
Grewal <sup>32</sup> / 1999	25	II	96%	Hemorrhage = 1
Merry <sup>28</sup> / 1999	19	I and II	100%	Absent
Doski <sup>33</sup> / 2000	41	I and II	100%	Absent
Fraga <sup>20**</sup> / 2000	23	II and III	91%	Subcutaneous emphysema = 2
Rescorla <sup>34</sup> / 2000	16	II and III	88%	Absent
Subramaniam <sup>25</sup> / 2001	22	II and III	100%	Absent
Chen <sup>35</sup> / 2002	19	II and III	100%	Absent

\* Efficacy - 100% means that open surgery was not necessary.

\*\* By means of mediastinoscopy and videothoracoscopy.

ray on the monthly follow-up showed residual thickening of the pleura.<sup>36</sup>

Recent studies have emphasized the importance of an early and aggressive treatment of complicated parapneumonic effusion. Thoracoscopy is preferred in the presence of loculated or septated effusion with no evidence of organization.<sup>6,28</sup> Currently, in our service, the children who present with parapneumonic effusion with indication for drainage are initially submitted to chest echography. If free-flowing effusion is detected, closed thoracostomy drainage is performed; if it is loculated or septated, thoracoscopy is carried out.

### ***Intrapleural enzymes***

Intrapleural use of fibrinolytic agents for the degradation of septated pleural effusion and increase of drainage through the chest tube was first described in 1950.<sup>1</sup>

Problems with allergic reactions and neutralization of the fibrinolytic agent by antibodies during prolonged treatment caused this type of approach to be abandoned in subsequent years.<sup>37</sup>

From the 1990s onwards, with the purification of streptokinase and the use of urokinase, which does not produce allergic reactions, new studies have recommended

this type of treatment for children with complicated parapneumonic effusion.

The fibrinolytic agent degrades a wide variety of proteins, including fibrin. The fibrinolytic reaction mediated by streptokinase or urokinase results in the activation of plasminogen and plasmin formation, which acts on the lysis of the septa or partitions of the loculated pleural effusion, allowing the material to liquefy and to be exudated from the chest cavity through the tube.<sup>38</sup>

A recent retrospective study of the use of streptokinase and urokinase in 25 children with loculated empyema suggests that this adjuvant treatment method is effective and safe in children with empyema thoracis.<sup>37</sup> The authors state that the treatment was effective in 20 of these children (80%). The use of fibrinolytic agents in this study was necessary due to the persistence of parapneumonic pleural effusion after drainage by chest tubes in patients with fever, despite the use of parenteral antibiotics. Five patients (20%) showed complications and had to undergo surgery. Three patients had bronchopleural fistula and required thoracotomy, decortication and segmental resection of the lung; two continued with loculations and required thoracotomy and decortication. In this series, no complications related to the use of fibrinolytic agents were observed, and chest tube time averaged 8.9 days (8 to 17 days). This study did not mention the length of hospital stay.<sup>37</sup>

The key discussion about the use of fibrinolytic agents as adjuvant treatment in children with empyema is that this type of approach requires a prolonged hospital stay and has remarkable rates of inefficiency.<sup>39</sup> In addition, there is no randomized prospective study comparing the use of fibrinolytic agents with other methods of treatment against complicated parapneumonic effusion in children. The only study of this type was conducted with adults and showed that thoracoscopy was more efficient than the use of fibrinolytic agents instilled through the chest tube in patients with empyema, with a shorter hospital stay and lower costs.<sup>40</sup> Because of this and while we do not have an appropriate study involving children, we do not recommend the use of fibrinolytic agents in children with complicated parapneumonic effusion.

### Special cases

#### *Pyopneumothorax*

Pneumothorax associated with complicated parapneumonic effusion often results from the rupture of a peripheral pulmonary microabscess in the pleural cavity. Large air escape may cause hypertensive pneumothorax, with significant respiratory distress.

As this type of pneumothorax is intercurrent with pleural infection, the treatment is the same as that for complicated parapneumonic effusion at the acute stage, requiring drainage by a large-bore chest tube. The total drainage of the pleural material, with complete expansion of the lung, is usually enough to close the leakage area of the pulmonary parenchyma.

#### *Bronchopleural fistula*

When parapneumonic effusion worsens due to the presence of a bronchopleural fistula, appropriate pleural drainage is crucial. Otherwise, the infected material may drain to the lung, and worsen pulmonary infection.<sup>14</sup>

Bronchopleural fistula may develop due to excessive expectoration in children without extensive pulmonary disease. The water/air ratio of the pleura is verified by chest x-ray, with the child in an elevated position. Under certain circumstances, computed tomography is necessary to confirm whether the water/air ratio is located in the pleural space or whether it results from pulmonary abscess.

The most common sign of bronchopleural fistula is the persistent air escape after closed thoracostomy drainage. The diagnosis is confirmed after problems with tube seals and drainage system components are ruled out.

As previously described, empyema with associated bronchopleural fistula requires emergency drainage by chest

tubes in order to avoid contamination of the entire respiratory tract. The child should preferably be placed in lateral decubitus, over the side of the fistula, so as to prevent aspiration of the pleural fluid into the contralateral lung. To close the fistula, it is important that the lung expand and occupy the whole chest cavity. To facilitate expansion of the lung, air escape through the fistula should be reduced by easing intrapulmonary pressure and increasing intrapleural pressure. The reduction of intrapulmonary pressure is achieved by maintaining spontaneous ventilation; avoid as much as possible tracheal intubation and pulmonary ventilation with high pressures. The increase of intrapleural pressure is obtained by interrupting continuous aspiration through the chest tube, which is maintained only under an underwater seal. With total expansion of the lung, the control of sepsis, the healing of pulmonary infection and adequate nutritional support, the bronchial fistula is expected to close within a few days. If the fistula persists for over two to four weeks, it should be surgically closed.

The surgical correction of the bronchopleural fistula in children should preferably be carried out by thoracotomy, since videothoracoscopy is a more complicated procedure.<sup>34</sup> In general, the closure of the bronchopleural fistula requires the removal of the lung tissue adjacent to the site of the fistula, with normal suture of the bronchial cartilage and closure of the air escape site.

#### *Pneumatocele*

Pneumatoceles are pulmonary cysts that occur as a sequela to pulmonary infection, resulting from bronchiolar and alveolar necrosis. With the lesion, air flows down the interstitial space, forming thin-walled, air-filled cysts.

Pneumatocele may rupture and cause hypertensive pneumothorax, bronchopleural fistula and empyema.<sup>41</sup>

Pneumatoceles are usually diagnosed on chest x-ray. Computed tomography may be useful for differential diagnosis between pulmonary cyst, diaphragmatic hernia or cystic adenomatoid malformation.

Most pneumatoceles do not require treatment, since they gradually decrease in size as pulmonary infection resolves. Approximately 45% of pneumatoceles resolve within six months, and the other 55% within 12 months, with no clinical or radiographic complications.

When a pneumatocele develops remarkably, with compression of structures and respiratory distress, thoracostomy drainage should be used. The same treatment is recommended for children who show pneumatocele rupture with development of pneumothorax, bronchopleural fistula or empyema. Thoracotomy and closure of air escape site is seldom necessary.



**References**

1. Rosen H, Nadkarni V, Theroux M, Padman R, Klein J. Intrapleural streptokinase as adjunctive treatment for persistent empyema in pediatric patients. *Chest* 1993;103:1190-3.
2. Chan W, Keyser-Gauvin E, Davis LT, Nguyen LT, Laberge JM. Empyema thoracic in children: a 26-year review of the Montreal Children's Hospital experience. *J Pediatr Surg* 1997;32(6):870-2.
3. Miller JI. Infections of the pleura. In: Shields TW. *General Thoracic Surgery*. Philadelphia: Lea & Febiger; 1989.p.633-49.
4. Mangete EDO, Kombo BB, Legg-Jack TE. Thoracic empyema: a study of 56 patients. *Arch Dis Child* 1993;69:587-8.
5. Robinson LA, Moulton AL, Fleming WH. Intrapleural fibrinolytic treatment of multiloculated thoracic empyemas. *Ann Thorac Surg* 1994;57:802-14.
6. Kern JA, Rodgers BM. Thoracoscopy in the management of empyema in children. *J Pediatr Surg* 1993;28:1128-32.
7. Silen ML, Weber TR. Thoracoscopic débridement of loculated empyema thoracic in children. *Ann Thorac Surg* 1995;59:1166-8.
8. Stovroff M, Teague G, Heiss KF, Parker P, Ricketts RR. Thoracoscopy in the management of pediatric empyema. *J Pediatr Surg* 1995;30:1211-5.
9. Van Way C III, Narrod J, Hopeman A. The role of early limited thoracotomy in the treatment of empyema. *J Thorac Cardiovasc Surg* 1988;96:436-9.
10. Raffensperger JC, Luck SR, Shkolnik A, Ricketts RR. Mini-thoracotomy and chest tube insertion for children with empyema. *J Thorac Cardiovasc Surg* 1982;84:497-504.
11. Miller JI. Empyema thoracis. *Ann Thorac Surg* 1990;50:343-4.
12. Gustafson RA, Murray GF, Warden HE. Role of lung decortication in symptomatic empyema in children. *Ann Thorac Surg* 1990;49:940-7.
13. Finck C, Wagner C, Jackson R, Smith Sam. Empyema: Development of a critical pathway. *Semin Pediatr Surg* 2002; 11:25-8.
14. Light RW. Parapneumonic effusions and empyema. In: Light RW. *Pleural diseases*. 3ª ed. Baltimore: Williams & Wilkin; 1995.p.129-53.
15. The American Thoracic Society: Management of non-tuberculous empyema. *Am Ver Respir Dis* 1962;85:935-6.
16. Light RW. Management of parapneumonic effusions. *Arch Intern Med* 1981;141:1339-41.
17. Meier A, Smith B, Rhagavan ABS, Moss LR, Harrison M, Skarsgard E. Rational treatment of empyema in children. *Arch Surg* 2000;135(8):907-12.
18. Boersma WG, Lowenberg A, Holloway Y, Kuttschutter H, Snijder JA, Koeter GH. Rapid detection of pneumococcal antigen in pleural fluid of patients with community acquired pneumonia. *Thorax* 1993;48:160-2.
19. Klena JW, Cameron B, Langer JC, Winthrop AL, Perez C. Timing of video-assisted thoracoscopic débridement for pediatric empyema. *J Am Coll Surg* 1998;187(4):404-8.
20. Fraga JC, Nunes G, Schopf L, Hinke T, Antunes CRH. Toracoscopia em crianças com derrame parapneumônico complicado. *Revista HCPA* 2000;20:13-20.
21. Himelmann RB, Callen PW: The prognostic value of loculations in parapneumonic pleural effusions. *Chest* 1986;90:852-6.
22. Foglia RP, Randolph JG. Current indications for decortication in the treatment of empyema in children. *J Pediatr Surg* 1987;22: 28-33.
23. Kosloske AM, Cartwright KC. The controversial role of decortication in the management of pediatric empyema. *J Thorac Cardiovasc Surg* 1988;96:166-70.
24. Sarihan H, Cay A, Aynaci M, Abaki A. Empyema in Children. *J Cardiovasc Surg* 1998;39:113-6.
25. Subramaniam R, Joseph VT, Tam GM, Goh A, Cahy OM. Experience with video-assisted thoracoscopic surgery in the management of complicated pneumonia in children. *J Pediatr Surg* 2001;36:316-9.
26. Fraga JC, Lima A, Schopf L, Antunes CRH. Pleuroscopia com mediastinoscópico em crianças com derrame parapneumônico complicado. *J Pediatr (Rio J)* 1999;75:470-6.
27. Rodgers BM. Thoracoscopy. In: Holcomb GW III. *Pediatric Endoscopic Surgery*. Connecticut: Appleton & Lange; 1994. p.103-17.
28. Merry CM, Bufo AJ, Shah RS, Schropp KP, Lobe TE. early definitive intervention by thoracoscopy in pediatric empyema. *J Ped Surg* 1999;34:178-81.
29. Steinbrecher HA, Hajmaldin AS. Thoracoscopy for empyema in children. *J Pediatr Surg* 1998;33:708-10.
30. Davidoff AM, Hebra A, Kerr J, Stafford PW. Thoracoscopic management of empyema in children. *J Laparosc Surgery* 1996;6 Suppl 1:51-4.
31. Campos JRM, Filho LOA, Werebe EC, Minamoto H, Quim LOA, Filomeno LTB, et al. Thoracoscopy in children and adolescents. *Chest* 1997;111:494-7.
32. Grewal H, Jackson RJ, Wagner CW, Smith S. Early video-assisted thoracic surgery in the management of empyema. *Pediatrics* 1999;103(5):e63.
33. Doski JJ, Lou D, Hicks BA, Megison SM, Sanchez P, Contidor M, et al. Management of parapneumonic collections in infants and children. *J Pediatr Surg* 2000;35(2):265-70.
34. Rescorla FJ, West KW, Gingalewski CA, Engum SA, Scherer III LR, Grosfeld J. Efficacy of primary and secondary video-assisted thoracic surgery in children. *J Pediatr Surg* 2000;35:134-8.
35. Chen LE, Langer JC, Dillon PA, Foglia RP, Huddleston CB, Mendeloff EM, et al. Management of late-stage parapneumonic empyema. *J Pediatr Surg* 2002;37(3):371-4.
36. Fraga JC, Komlós M, Nunes G, Schopf L. Toracoscopia em crianças com empiema. *Resumo do IV Congresso de Cirurgia Pediátrica Del Cono Sur de América (CIPESUR)*; 2001 Nov 7-10; Montevideo, Uruguai. Montevideo: CDC; 2001:75.
37. Kiliç N, Çelebi S, Gürpınar A, Hacimustafaoglu M, Konca Y, Ildirm I, et al. Management of thoracic empyema in children. *Pediatr Surg Int* 2002;18:21-3.
38. Jerjes-Sanchez C, Ramirez-Rivera A, Elizalde JJ, Delgado R, Cícero R, Ibarra-Perez C, et al. Intrapleural fibrinolysis with streptokinase as an adjunctive treatment in hemothorax and empyema. A multicenter trial. *Chest* 1996;109:1514-9.
39. Krishnan R, Amin N, Dozor AJ, Stringel G. Urokinase in the management of complicated parapneumonic effusions in children. *Chest* 1997;112:1579-83.

40. Wait M, Sharma S, Hohn J, Nogare AD. A randomized trial of empyema therapy. *Chest* 1997;111:1548-51.
41. Zuhdi MK, Bradley JS, Spear RM, Peterson BM. Fatal air embolism as a complication of staphylococcal pneumonia with pneumatoceles. *Pediatr Infect Dis J* 1995;14:811-2.

Correspondence:

Dr. José Carlos Fraga

Rua Ramiro Barcelos 2350/600

Hospital de Clínicas de Porto Alegre

CEP 90430-000 – Porto Alegre, RS, Brazil

E-mail: [jcfraga@brturbo.com](mailto:jcfraga@brturbo.com)