

Endovascular repair of an abdominal aortic aneurysm in patient with horseshoe kidney: a case report

Correção endovascular de aneurisma de aorta abdominal em paciente com rim em ferradura: relato de caso

Eduardo Keller SAADI¹, Luiz Henrique DUSSIN², Leandro de MOURA³, Alcides José ZAGO⁴

RBCCV 44205-1012

Abstract

Horseshoe kidney is a rare congenital anomaly that may cause various technical problems during conventional repairs of abdominal aortic aneurysms. We report the case of a 68-year-old woman with a horseshoe kidney, symptomatic abdominal aortic aneurysm and mild renal failure. The patient underwent endovascular repair using a bifurcated endoprosthesis. The postoperative was uneventful. We describe the diagnosis and the endovascular technique and literature review.

Descriptors: Aortic aneurysm. Aortic aneurysm, abdominal/surgery. Blood vessel prosthesis implantation/methods. Kidney diseases/surgery. Kidney/abnormalities. Stents.

Resumo

O rim em ferradura é uma anomalia congênita rara que pode causar várias dificuldades técnicas durante a correção convencional de aneurisma de aorta abdominal. Relatamos o caso de uma paciente de 68 anos com rim em ferradura, aneurisma de aorta abdominal sintomático e disfunção renal leve. A paciente foi submetida a correção endovascular, sendo utilizada uma endoprótese bifurcada. O pós-operatório foi livre de complicações. O diagnóstico e a técnica endovascular são discutidos, assim como a literatura revisada.

Descritores: Aneurisma aórtico. Aneurisma da aorta abdominal/cirurgia. Implante de prótese vascular/métodos. Nefropatias/cirurgia. Rim/anormalidades. Contenedores.

INTRODUCTION

Horseshoe kidney (HSK) is a complex congenital anomaly that results from the fusion of renal parenchyma (usually of the lower poles); it is associated with anomalous rotation of the urinary tract and vascular anomalies [1-4]. Its rate of occurrence ranges from 0.15% to 0.8%, which corresponds to 1 in every 400 people [5,6]. Horseshoe kidney associated with abdominal aortic aneurysm (AAA) is rare: it is found in about 1 in every

710 autopsied cases, and in only 0.12% of the patients that undergo AAA repair [1,7,8].

We report a case of an AAA patient, occluded right iliac artery aneurysm, HSK and impaired renal function. The patient was treated with endovascular repair (EVAR).

CASE REPORT

A 68-year-old woman with diabetes mellitus, arterial hypertension and coronary heart disease presented with

1. PhD; Professor of the Medical School, Cardiovascular Surgery, Federal University of Rio Grande do Sul (UFRGS).
2. Master's Degree, Cardiovascular and Endovascular Unit of the Clinics Hospital of Porto Alegre, UFRGS; Cardiovascular Surgeon – Clinics Hospital of Porto Alegre.
1. Master's Degree, Cardiovascular Surgeon – Clinics Hospital of Porto Alegre.
2. PhD; Professor of Cardiology- UFRGS.

This study was carried out at the Cardiovascular and Endovascular

Unit of the Clinics Hospital of Porto Alegre, Federal University of Rio Grande do Sul, Porto Alegre, RS, Brazil.

Correspondence address: Eduardo Saadi
Rua Pedro Weingartner, 125/801 Porto Alegre, RS, Brazil. 90430-140
Phone: +55 (51) 9982 5379 Fax: +55 (51) 3333 7887.
E-mail: esaadi@terra.com.br

Article received on June 8th, 2008
Article accepted on August 1st, 2008

recent-onset lower back pain (lasting about 10 days). During her physical examination, she presented a pulsatile abdominal mass, and pain reproduced by palpation. Right femoral pulse was weak, but left femoral pulse was normal. She had a history of smoking heavily (an average of 2 packs per day) and mild renal dysfunction (creatinine = 1.5 mg/dl; urea = 55 mg/dl). Multislice spiral CT angiography with 3-Dimensional reconstruction revealed a fusiform AAA (68mm diameter) and a horseshoe kidney (Figure 1). The proximal neck was 20mm (diameter) and 25mm long - but severely angulated (>60 degrees), as shown in Figure 2. The HSK was supplied by two renal arteries on the right side and three on the left. An occluded right common iliac artery aneurysm 48 mm in diameter was also found (Figure 3).

Endovascular repair (EVAR) was chosen. Both femoral arteries were dissected with the patient under spinal anesthesia. First, an attempt was made to pass a guidewire through the occluded right iliac artery. This was successfully achieved through the right common femoral artery. A 23 x 12mm x 16cm bifurcated Gore-Tex (Excluder) stent graft was chosen, and a proximal aortic extension (aortic extender 23 X 33 mm) was used to seal the angulated neck. The main trunk was deployed using an 18 Fr sheath through the left common femoral artery, and the contralateral limb was inserted through the right common femoral artery with a 12 Fr sheath. A 7-cm long iliac extension was placed in the right side to treat the right iliac artery aneurysm, covering the right internal iliac artery and landing at the external iliac artery (Figure 4). After that, the proximal aortic extender was deployed. One of the left polar renal arteries was occluded by the stent graft. After surgery, the patient's creatinine level rose to 2.5 mg/dl, but returned to baseline levels after 3 days. The patient was discharged from the hospital on the 6th postoperative day, and the recovery was uneventful. A postoperative CT scan showed good anatomic correction and a well-functioning HSK (Figures 5 and 6).

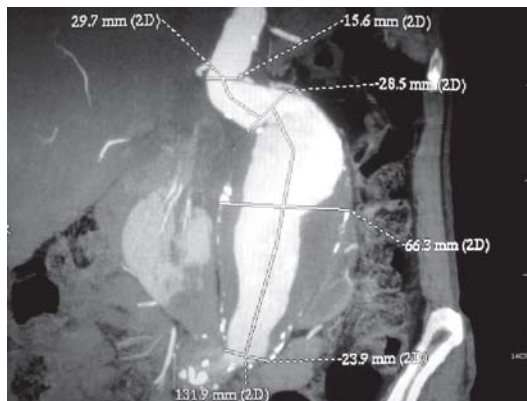


Fig. 2 - CT with 3-Dimensional reconstruction demonstrating the AAA with an angulated proximal neck

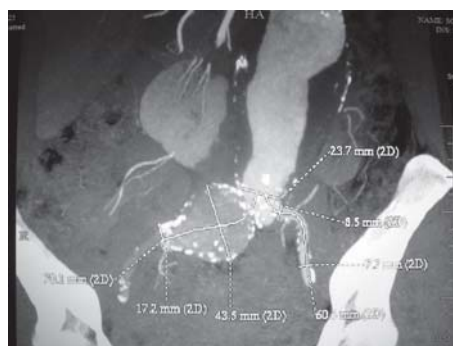

Fig. 3 - Occluded right common iliac artery aneurysm

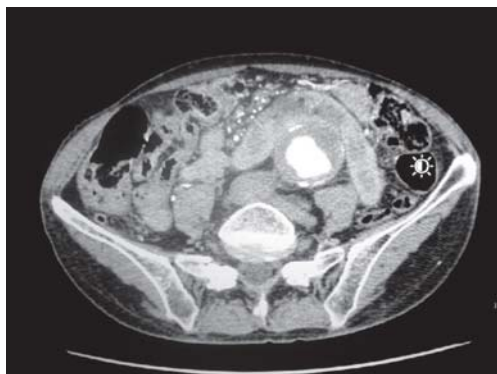

Fig. 1 - Computed tomography showing an abdominal aortic aneurysm (AAA) and horseshoe kidney

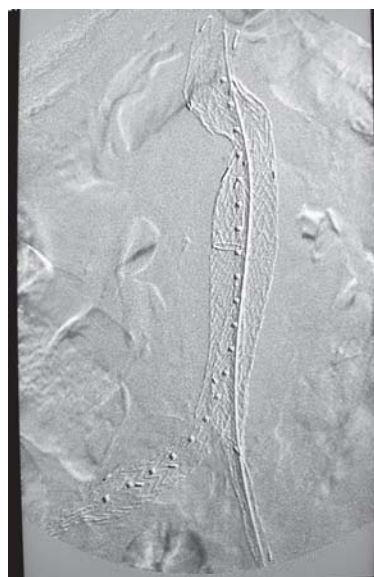

Fig. 4 - Right extension is covering the common iliac artery aneurysm and landing at the right external iliac artery at the end of the endovascular procedure

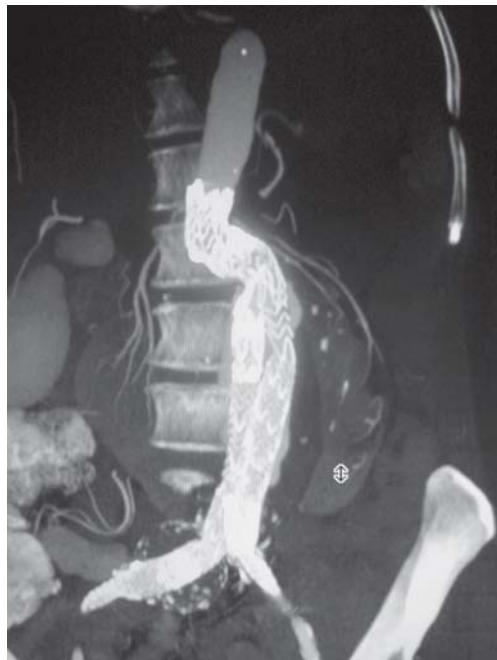


Fig. 5 - Postoperative CT scan showing exclusion of the AAA and right iliac aneurysm and no endoleaks

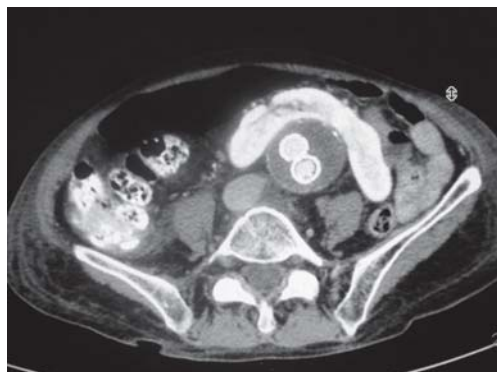

Fig. 6 - Postoperative Axial CT scan demonstrating the two limbs of the stent-graft and a well-fused horseshoe kidney and no leaks

DISCUSSION

The surgical treatment of AAA coexistent with HSK gives rise to several technical difficulties. The renal isthmus is located in front of the aneurysm and frequently needs to be divided to expose the aorta [9]. Moreover, ectopic renal arteries are often found in this condition [10]. Since 1991, EVAR has been used for the treatment of AAA coexistent with HSK in 13 cases, and uni-iliac stent grafting was used in most of them [11-19]. This method is easier and quicker because there is no need to catheterize the contralateral limb.

The renal impact of aortic stent grafting in patients with HSK was analyzed using the EUROSTAR protocol. Out of 130 patients in whom aortic stent grafting was performed from 1995 to 2000, 4 had coexistent HSK and normal renal function. In all patients, the aneurysm was successfully excluded with the occlusion of one to four anomalous renal arteries. During follow-ups, no clinically significant renal impairment was detected [20]. Only one report in the literature describes a case of AAA coexistent with HSK and moderate renal impairment that was treated using EVAR with no subsequent renal complication [19]. Our patient had slight renal impairment: her renal function worsened shortly after the procedure, but then returned to baseline levels.

To our knowledge, this is the first case of an AAA coexistent with HSK and occlusion of the iliac artery described in the literature. In this case, access from the right femoral artery might have been limited. The surgical team was ready to perform left uni-iliac stent grafting and an extra-anatomical femoral-femoral bypass, but this was not necessary because a bifurcated graft was successfully deployed.

Horseshoe kidneys are rare, and even more so are their association with an abdominal aortic aneurysm that needs repair. In patients with the appropriate anatomy, EVAR is feasible despite predictable technical difficulties (angulated neck, iliac aneurysm and occlusion) and the possibility of renal impairment. In patients with ruptured AAA and HSK the EVAR treatment or a retroperitoneal approach should be strongly considered [21]. When faced with an AAA and HSK, two purposes should be intended: to safely repair the life-threatening aortic disease, and thus keep mortality and morbidity low, and to avoid renal complications. The choice of surgical technique should take into consideration the patient's characteristics and the surgeon's experience. Endovascular repair is an attractive option to treat patients with AAA and HSK.

REFERENCES

1. Eisendrath DN, Phifer FM, Culver HB. Horseshoe kidney. *Ann Surg.* 1925;82(5):735-64.
2. Connelly TL, McKinnon W, Smith RB 3rd, Perdue GD. Abdominal aortic surgery and horseshoe kidney. *Arch Surg.* 1980;115(12):1459-63.
3. Glenn JF. Analysis of 51 patients with horseshoe kidney. *N Engl J Med.* 1959;261:684-7.
4. Sidell PM, Pairolo PC, Payne WS, Bernatz PE, Spittel JA Jr. Horseshoe kidney associated with surgery of the abdominal aorta. *Mayo Clin Proc.* 1979;54(2):97-103.

5. Bomalaski MD, Gardner AL, Madison DL. Aortic surgery complicated by horseshoe kidney. *Indiana Med.* 1988;81(8):688-93.
6. Kölln CP, Boatman DL, Schmidt JD, Flocks RH. Horseshoe kidney: a review of 105 patients. *J Urol.* 1972;107(2):203-4.
7. Crawford ES, Coselli JS, Safi HJ, Martin TD, Pool JL. The impact of renal fusion and ectopia on aortic surgery. *J Vasc Surg.* 1988;8(4):375-83.
8. O'Hara PJ, Hakaim AG, Hertzner NR, Krajewski LP, Cox GS, Beven EG. Surgical management of aortic aneurysm and coexistent horseshoe kidney: review of a 31-year experience. *J Vasc Surg.* 1993;17(5):940-7.
9. Ezzet F, Dorazio R, Herzberg R. Horseshoe and pelvic kidneys associated with abdominal aortic aneurysms. *Am J Surg.* 1977;134(2):196-8.
10. Kotsis T, Mylonas S, Katsenis K, Arapoglou V, Dimakakos P. Abdominal aortic aneurysm with ectopic renal artery origins: a case report. *Vasc Endovasc Surg.* 2007;41(5):463-6.
11. Ferko A, Krajina A, Jon B, Lesko M, Voboril Z. Juxtarenal aortic aneurysm associated with a horseshoe kidney. Transfemoral endoluminal repair. *Arch Surg.* 1997;132(3):316-7.
12. Loftus IK, Thompson MM, Fishwick G, Boyle JR, Bell PR. Endovascular repair of aortic aneurysms in the presence of a horseshoe kidney. *J Endovasc Surg.* 1998;5(3):278-81.
13. Lee WA, Rubin GD, Arko F, Hill BB, Zarins CK. Endovascular stent graft repair of an infrarenal abdominal aortic aneurysm with a horseshoe kidney. *Circulation.* 2001;103(16):2126-7.
14. Toursarkissian B, Mejia A, Wholey MH, Lawler MA, Thompson IM, Sykes MT. Endovascular AAA repair in a patient with a horseshoe kidney and an isthmus mass. *J Endovasc Ther.* 2001;8(6):604-8.
15. Teijink JA, Odink HF, Bendermacher B, Welten RJ, Veldhuijzen van Zanten GO. Ruptured AAA in a patient with a horseshoe kidney: emergent treatment using the Talent acute endovascular aneurysm repair kit. *J Endovasc Ther.* 2003;10(2):240-3.
16. Aquino RV, Rhee RY, Muluk SC, Tzeng EY, Carrol NM, Makaroun MS. Exclusion of accessory renal arteries during endovascular repair of abdominal aortic aneurysms. *J Vasc Surg.* 2001;34(5):878-84.
17. Ruppert V, Umscheid T, Rieger J, Schmedt CG, Mussack T, Steckmeier B, et al. Endovascular aneurysm repair: Treatment of choice for abdominal aortic aneurysm coincident with horseshoe kidney? Three case reports and review of literature. *J Vasc Surg.* 2004; 40(2): 367-70.
18. Volpe P, Nano G, Dalainas I, Palazzo V, Casana R, Paroni G. Endovascular repair of an abdominal aortic aneurysm in a patient with a horseshoe kidney: report of a case. *Surg Today.* 2006;36(7):623-8.
19. Sajid MS, Ahmed N, Tibbals J, Hamilton G. Endovascular aneurysm repair in a patient with a horseshoe kidney and impaired renal function. *Ir J Med Sci.* 2006;175(4):71-3.
20. Jackson RW, Fay DM, Wyatt MG, Rose JD. The renal impact of aortic stent-grafting in patients with a horseshoe kidney. *Cardiovasc Intervent Radiol.* 2004;27(6):632-6.
21. Stroosma OB, Kootstra G, Schurink GW. Management of aortic aneurysm in the presence of a horseshoe kidney. *Br J Surg.* 2001;88(4):500-9.