

Decreased expression of cardiac troponin C is associated with cardiac lesions in *Amorimia exotropica* poisoned cattle¹

Saulo Petinatti Pavarini², Marcele Bettim Bandinelli², Gregory Duarte Juffo², Suyene Ultramari de Souza², David Driemeier² and Cláudio Estêvão Farias da Cruz^{2*}

ABSTRACT.- Pavarini S.P., Bandinelli M.B., Juffo G.D., Souza S.O., Driemeier D. & Cruz C.E.F. 2012. **Decreased expression of cardiac troponin C is associated with cardiac lesions in *Amorimia exotropica* poisoned cattle.** *Pesquisa Veterinária Brasileira* 32(10):1005-1008. Setor de Patologia Veterinária, Faculdade de Veterinária, Universidade Federal do Rio Grande do Sul, Av. Bento Gonçalves 9090, Bairro Agronomia, Porto Alegre, RS 91540-000, Brazil. E-mail: claudio.cruz@ufrgs.br

The plants which cause sudden death of cattle in Brazil occupy a leading position for losses in the cattle industry. *Amorimia exotropica* is one of the plants pertaining to this group. Diagnostic findings in these cases may be inconclusive; further knowledge is necessary. This paper identifies cardiac lesions through anti-cardiac troponin C (cTnC) immunohistochemistry performed in tissues from cattle poisoned after consumption of *A. exotropica* in southern Brazil. Heart fragments from nine *A. exotropica*-poisoned cattle were studied immunohistochemically using anti-human cTnC as the primary antibody. In the hearts from all of the poisoned cattle, there was a sharp decrease in the cTnC expression level in the cytoplasm of groups of cardiomyocytes. A significant decrease in anti-cTnC immunoreactivity occurred particularly in degenerated or necrotic cardiomyocytes. Occasional groups of cells showed complete loss of immunolabeling. In the remaining intact cardiomyocytes from poisoned cattle and in cardiomyocytes from six cattle that died from other causes there was intense cytoplasmic staining.

INDEX TERMS: *Amorimia exotropica*, cattle, sudden death, troponin, immunohistochemistry, cardiac injury.

RESUMO.- [Expressão diminuída de troponina cardíaca C associada com lesões cardíacas em bovinos intoxicados por *Amorimia exotropica*.] No Brasil, plantas cujo consumo determina morte súbita de bovinos estão entre as principais causas de perdas na pecuária. Esse trabalho identifica lesões cardíacas através de imuno-histoquímica antitroponina cardíaca C (TncC), desenvolvida em tecidos de bovinos intoxicados após consumo de *Amorimia exotropica*, no sul do Brasil. Fragmentos cardíacos de nove bovinos intoxicados, naturalmente, por *Amorimia exotropica* foram examinados por imuno-histoquímica anti-TncC, como anticorpo primário. Nos corações de todos os bovinos intoxicados pela planta, havia pronunciada diminuição

dos níveis de expressão de TncC no citoplasma de grupos de cardiomiócitos. Diminuição significativa na imunorreatividade anti-TncC ocorreu, particularmente, em cardiomiócitos degenerados ou necróticos. Grupos ocasionais de células mostraram completa perda de imunomarcção. Em cardiomiócitos remanescentes e intactos de bovinos intoxicados e em cardiomiócitos de seis bovinos que morreram por outras causas, observou-se intensa coloração citoplasmática.

TERMOS DE INDEXAÇÃO: *Amorimia exotropica*, bovinos, morte súbita, troponina, imuno-histoquímica, lesão cardíaca.

INTRODUCTION

Amorimia exotropica is a woody vine of the Malpigiaceae family, which occurs in southern Brazil and Argentina (Anderson 2006), and is poisonous for cattle (Gava et al. 1998, Pavarini et al. 2011, Soares et al. 2011). Poisoned cattle usually die suddenly. In Brazil, sudden death of ruminants caused by the ingestion of cardiotoxic poisonous

¹ Received on May 31, 2012.

Accepted for publication on July 4, 2012.

² Departamento de Patologia Clínica Veterinária, Faculdade de Veterinária, Universidade Federal do Rio Grande do Sul (UFRGS), Avenida Bento Gonçalves 9090, Porto Alegre, RS 91540-000, Brazil. *Corresponding author: claudio.cruz@ufrgs.br

plants has been mainly associated with the consumption of species from the genera *Palicourea*, *Arrabidaea*, and *Amorimia* (Tokarnia et al. 2002). While the affected cattle usually die within few minutes after rapid exercise-induced clinical distress, death may occur with no previous clinical signs. Pathological changes are rare, and the main microscopic finding observed in one-third of the cases is vacuolar hydropic degeneration in the epithelial cells of renal tubules (Tokarnia et al. 1990, 2002). However, recent reports have associated *Amorimia* sp. poisoning with cardiac fibrosis (Pavarini et al. 2011, Soares et al. 2011).

Cardiac troponins (cTns) are muscular proteins that comprise the myocardial contractile apparatus (Dhoot et al. 1979). Because they are released into the systemic circulation as a result of degeneration and acute myocardial necrosis, cTns are specific and valuable biochemical markers of myocyte degeneration in acute human coronary diseases (Azzazy & Christenson 2002). In this study, cardiac tissues from naturally *Amorimia exotropica*-poisoned cattle were analyzed using an anti-cTn C immunohistochemical technique.

MATERIALS AND METHODS

Serial 3-5µm histological sections from paraffin-embedded heart fragments from nine naturally *Amorimia exotropica*-poisoned cattle (Pavarini et al. 2011) were stained with hematoxylin and eosin (HE) and the streptavidin immunohistochemical method. Slices were placed on ImmunoSlides (EasyPath, São Paulo/SP, Brazil). Endogenous peroxidase activity was inhibited by immersing the tissue sections in a 10% hydrogen peroxide in methanol solution for 15 minutes. Antigen retrieval was performed in a pressure cooker at 125°C for 3 minutes by immersing sections in TRIS-EDTA (10mM Tris Base, 1mM EDTA Solution, 0.05% Tween 20, pH 9.0). Nonspecific reactions were blocked by immersion in skimmed milk 5% (Molico®). The monoclonal anti-human cTnC (Nova Castra) antibody was used at a 1:40 dilution in phosphate-buffered saline (PBS). Slices were incubated overnight with the primary antibody in a humid chamber at 4°C. Next, the specimens were incubated with a biotinylated anti-rabbit antibody (LSAB plus System-HRP, Dako, Carpinteria, California, United States of America) for 20 minutes and then treated with streptavidin-peroxidase conjugate (LSAB plus System-HRP). DAB (Dako) was the chromogen, and Harris hematoxylin was used as the counterstain. In addition, heart fragments (bearing cardiomyocyte necrosis) from one naturally monensin-poisoned (Corrêa et al. 2003) and six (three slaughtered and three killed by rabies) cattle with lesion-free cardiomyocytes served as positive controls. Heart fragments from *A. exotropica*- and monensin-poisoned cattle incubated with PBS instead of the primary antibody served as the negative controls.

RESULTS

The histological changes observed in the heart from all nine *Amorimia exotropica* poisoned-cattle included groups of cardiomyocytes or isolated cells with enhanced cytoplasmic eosinophilia and a lack of cytoplasmic striations that were distinct from intracytoplasmic and intranuclear vacuole formation. Some retracted cells were decreased in size and occasionally showed pyknotic or fragmented nuclei (Fig.1A,B). The immunohistochemical analysis showed marked reduction in cTnC expression within the cytoplasm

of groups of cardiomyocytes from the *A. exotropica*- and monensin-poisoned cattle. A significant decrease in anti-cTn immunolabeling (a-cTni) occurred particularly within cardiomyocytes displaying degenerative and necrotic changes. Total loss of a-cTni was occasionally observed in areas affected with severe microscopic lesions (Fig.1C,D). While rare cardiac muscle fibers without histological changes showed loss of a-cTni, intense a-cTni was observed in the cytoplasm of intact cardiomyocytes from *A. exotropica*- and monensin-poisoned cattle and the heart fragments from the positive controls.

DISCUSSION AND CONCLUSION

Hearts from nine *Amorimia exotropica*-poisoned cattle presented well-demarcated areas with significantly decreased or absent cTn expression, which indicates the presence of cardiac lesions. Occasional intact cardiomyocytes also showed diminished immunoreactivity. The early depletion of cardiac troponin in intact cardiomyocytes under hematoxylin and eosin staining has been demonstrated previously (Kleine et al. 1993).

Due to its high specificity and diagnostic sensibility, the serum cTns are used as major biomarkers of myocardial lesion in humans (O'Brien, 2008, Wells & Sleeper 2008). Their use in immunohistochemistry is a valuable tool for the detection of cardiac lesions during human forensic pathology (Ortmann et al. 2000). The detection of serum cTns of cattle affected with cardiac lesions was demonstrated in cases of foot-and-mouth disease (Gunes et al. 2005, Tunca et al. 2008), valvular endocarditis (Buczinski & Bélanger 2010), and pericarditis (Mellanby et al. 2007). However, the use of immunohistochemistry to determine whether cardiac lesions are associated with the lack of cTn expression has been rarely reported (Tunca et al. 2008).

In this study, the anti-human cTnC antibody was useful for detecting cardiac lesions in cattle. cTnC is present as two isoforms, one that occurs in fast-twitch muscle fibers and another that occurs in cardiac and slow-twitch muscular fibers. The homology between the cardiac and the skeletal muscle isoforms decreases the cardiac specificity of cTnC and limits its diagnostic utility in biochemical analysis (Schreier et al. 1990). However, being able to identify cardiac lesions through anti-cTnC immunohistochemistry has proven useful (Ortmann et al. 2000).

The most important Brazilian toxic plants are those associated with sudden death because they are responsible for more than half of the cattle deaths due to plant poisoning in the country (Tokarnia et al. 2002). These plants may have toxic components that interfere with the heart functioning, such that affected animals die due to acute heart failure (Tokarnia et al. 1990, 2002). While fluoroacetic acid has only been identified as the major toxicant in some of the plants from this group (Krebs et al. 1994), it is believed to be the toxic agent present in all of them (Tokarnia et al. 2002). Inconsistent histological changes include enhanced cytoplasmic eosinophilia; these changes have been associated with nuclear pyknosis in hearts from cattle poisoned after consumption of species of *Palicourea*, *Arrabidaea*, and

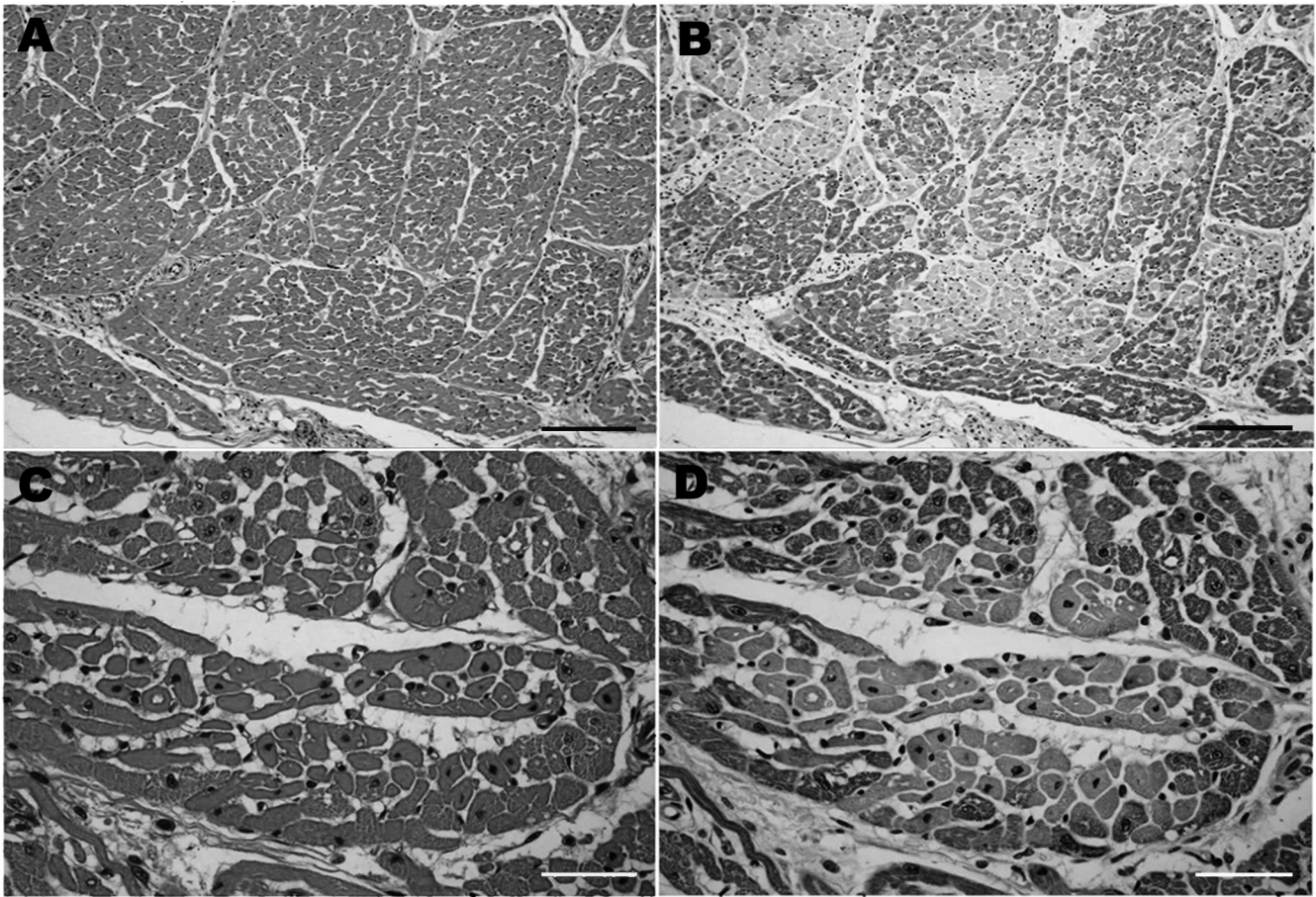


Fig.1. (A) Heart sections from *Amorimia exotropica*-poisoned cattle. Observe the distribution of groups of cardiomyocytes displaying enhanced eosinophilia within the HE-stained section, Bar 420 μ m. (B) Decreased anti-cardiac troponin C immunolabeling within the cytoplasm of altered cardiomyocytes, serial sections, Bar 420 μ m and 50 μ m, respectively. (C,D) Hyper-eosinophilic cardiomyocytes lack cytoplasmic striation and display cellular retraction and pyknosis within the HE-stained section, Bar 50 μ m.

Amorimia (Tokarnia et al. 1990). More recently, pronounced cardiac lesions have been associated with ruminant poisoning by *Amorimia* sp. (Schons et al. 2011, Soares et al. 2011).

Due to the typically scarce lesions present in the dead animals, the diagnosis of sudden death induced by poisonous plants in Brazil is based on the association of epidemiological (presence of plants and sudden death triggered by exercise) with pathological findings. Until now, the pathological change most frequently linked to the disease has been hydropic degeneration in the epithelium of the renal tubules, which is present in one-third of the cases (Tokarnia et al. 1990, 2002). Such changes were seen in 3 from the 9 cases in this study. This paper demonstrates cardiac changes in naturally *Amorimia exotropica*-poisoned cattle through an immunohistochemical analysis using an anti-cardiac troponin C antibody. In addition, this study suggests the applicability of this method as an auxiliary test for diagnosing cattle poisoning by *A. exotropica* and most likely by the other plants that cause sudden death of cattle in Brazil.

Acknowledgements.- This study was funded by the Conselho Nacional de Desenvolvimento Científico e Tecnológico (CNPq, Proc. 478842/2009-0) of Brazil.

REFERENCES

- Anderson W.R. 2006. Eight segregates from the neotropical genus *Mascagnia* (Malpighiaceae). *Novon* 16:168-204.
- Azzazy H.M.E. & Christenson R.H. 2002. Cardiac Markers of Acute Coronary Syndromes: Is there a case for point-of-care testing? *Clin. Biochem.* 35:13-27.
- Buczinski S. & Bélanger A.M. 2010. Bovine tricuspid endocarditis as a cause of increased serum concentration of cardiac troponins. *Can. Vet. J.* 51:195-197.
- Corrêa A.M.R., Loretti A.P., Vogg G., Traverso S.D., Coelho R. & Driemeier D. 2003. Intoxicação espontânea por monensina em bovinos. *Resumos XI Encontro Nacional de Patologia Veterinária, Botucatu*, p.57.
- Dhoot G.K., Frearson N. & Perry V.S. 1979. Polymorphic forms of troponin T and troponin C and their localization in striated muscle cell types. *Exp. Cell. Res.* 122:339-350.
- Gava A., Cristani J., Branco J.V., Neves D.S., Mondadori A.J. & Souza R.S. 1998. Mortes súbitas em bovinos causadas pela ingestão de *Mascagnia* sp. (Malpighiaceae), no Estado de Santa Catarina. *Pesq. Vet. Bras.* 18:16-20.
- Gunes V., Erdogan H.M., Cital M. & Ozcan K. 2005. Assay of cardiac troponins in the diagnosis of myocardial degeneration due to foot-and-mouth disease in a calf. *Vet. Rec.* 156:714-715.
- Kleine A.H., Glatz J.F.C., Havenith M.G., Van Nieuwenhoven F.A., van der Vusse G.J. & Bosman F.T. 1993. Immunohistochemical detection of very recent myocardial infarctions in humans with antibodies against heart-type fatty acid-binding protein. *Cardiovasc. Pathol.* 2:63-69.
- Krebs H.C., Kemmerling W. & Habermehl G. 1994. Qualitative and quan-

- titative determination of fluoroacetic acid in *Arrabidaea bilabiata* and *Palicourea marcgravii* by F-NMR spectroscopy. *Toxicon* 32:909-913.
- Mellanby R.J., Henry J.P., Cash R., Ricketts S.W., Bexiga J.R. & Mellor D.J. 2007. Serum cardiac troponin I concentrations in cattle with pericarditis. *Vet. Rec.* 161:454-455.
- O'Brien P.J. 2008. Cardiac troponin is the most effective translational safety biomarker for myocardial injury in cardiotoxicity. *Toxicology* 245:206-218.
- Ortmann C., Pfeiffer H. & Brinkmann B. 2000. A comparative study on the immunohistochemical detection of early myocardial damage. *Int. J. Legal. Med.* 113:215-220.
- Pavarini S.P., Soares M.P., Bandarra P.M., Gomes D.C., Bandinelli M.B., Cruz C.E.F. & Driemeier D. 2011. Mortes súbitas em bovinos causadas por *Amorimia exotropica* (Malpighiaceae) no Rio Grande do Sul. *Pesq. Vet. Bras.* 31:291-296.
- Schons S.V., Mello T.L., Riet-Correa F. & Schild A.L. 2011. Poisoning by *Amorimia (Mascagnia) septium* in sheep in northern Brazil. *Toxicon* 57:781-786.
- Schreier T., Kedes L. & Gahlmann R. 1990. Cloning, structural analysis, and expression of the human slow twitch skeletal muscle/cardiac troponin C gene. *J. Biol. Chem.* 265:47-53.
- Soares M.P., Pavarini S.P., Adrien M.L., Quevedo P.S., Schild A.L., Peixoto P.V., Cruz C.E.F. & Driemeier D. 2011. *Amorimia exotropica* poisoning as a presumptive cause of myocardial fibrosis in cattle. *J. Vet. Diagn. Invest.* 23:1226-1229.
- Tokarnia C.H., Peixoto P.V. & Döbereiner J. 1990. Poisonous plants affecting heart function of cattle in Brazil. *Pesq. Vet. Bras.* 10:1-10.
- Tokarnia C.H., Döbereiner J. & Peixoto P.V. 2002. Poisonous plants affecting livestock in Brazil. *Toxicon* 40:1635-1660.
- Tunca R., Sozmen M., Erdogan H., Cital M., Uzlu E., Ozen H. & Gokçe E. 2008. Determination of cardiac troponin I in the blood and heart of calves with foot-and-mouth disease. *J. Vet. Diagn. Invest.* 20:598-605.
- Wells S.M. & Sleeper M. 2008. Cardiac troponins. *J. Vet. Emerg. Crit. Care* 18:235-245.